

ULTRASOUND DIAGNOSIS

Phiwipha Kamonrat

History

A ten-year-old, intact, female Golden Retriever dog was presented at the Chulalongkorn University Small Animal Hospital with a history of inappetance, depression, acute abdominal pain and vomiting. Physical examination revealed a high fever (104⁰ F), icterus mucous membranes and a severe pain on palpation of the right cranial abdomen. Abdominal clinical parameters included leukocytosis (2.58x10³ white blood cells/ μ l, 70% neutrophils, 1% bands, 1% basophils, 20% lymphocytes and 8% monocytes), anemia (3.2x10⁶ red blood cells/ μ l, 7 g/dl hemoglobin and 22% hematocrit), thrombocytopenia (69x10³ platelets/ μ l) and elevation of serum alkaline phosphatase (441 units) and amylase concentrations (2,500 U/L). Plain radiographs of the abdomen demonstrated a mild peritoneal effusion. An abdominal ultrasonography was performed to obtain more specific information.

Ultrasonographic Findings

A real-time, ultrasonographic examination of an entire abdomen was performed using an 8 MHz microconvex, phased array transducer with the dog in dorsal recumbency. An abdominal pain was detected in the right cranial abdominal region during scanning. A small quantity of localized anechoic peritoneal fluid was seen adjacent to the descending duodenum. The duodenal wall was normal, measured 4.6 mm thick, and layers remained distinct. The echogenicity relationship of liver, spleen and kidneys were within a normal limits. The gall bladder was distended with a large amount of anechoic bile. The common bile duct, mainly in its distal segment, was dilated, measured 5.8 mm in diameter. Both right and left lobes of the pancreas appeared heterogeneously hypoechoic and had slightly irregular margins (Figs 1 and 2). They were mildly thickened, measured up to 1.7 cm in diameter. There was an increase in echogenicity of the peripancreatic mesenteric fat. These findings were consistent with a diffuse inflammatory change in the pancreas. Other differential diagnoses would include infiltrative disease process.

Diagnosis

Ultrasonographic diagnosis – Acute pancreatitis with secondary extrahepatic duct obstruction.

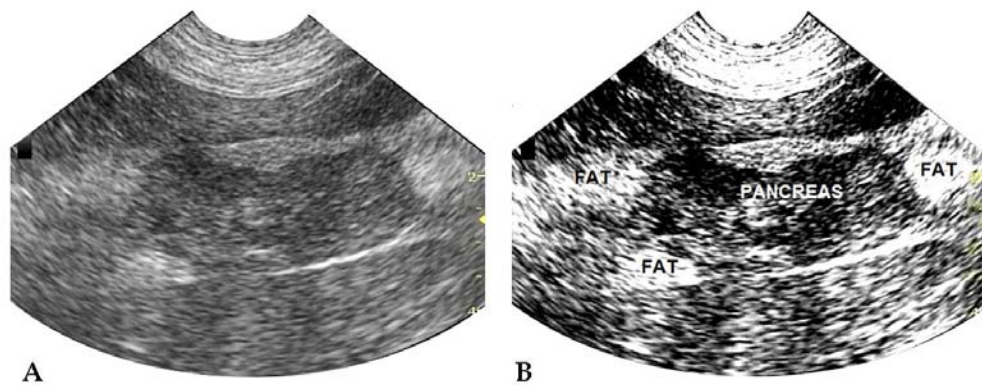


Figure 1 A longitudinal sonogram (A) and a corresponding schematic image (B) of the right lobe of the pancreas of a ten-year-old, intact, female Golden Retriever dog in dorsal recumbency. The lobe was hypoechoic and thickened, measured 1.6-1.7 cm in diameter. The surrounding fat was hyperechoic, outlining the pancreatic contours.

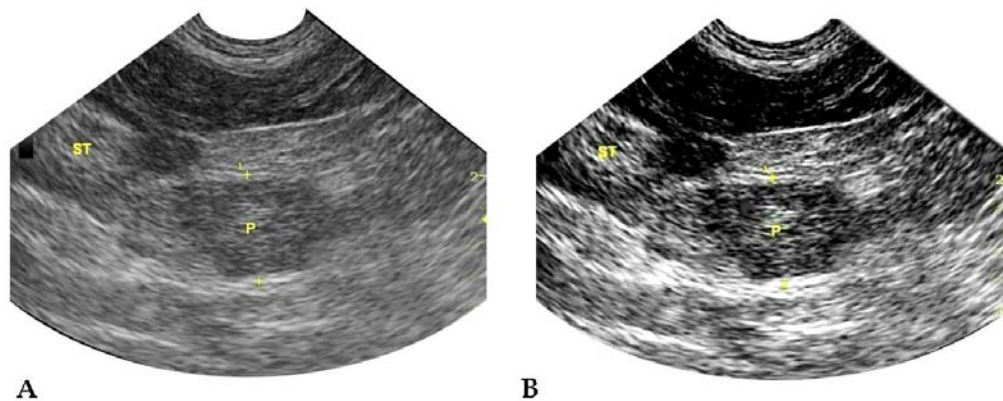


Figure 2 A longitudinal sonogram (A) and a corresponding schematic image (B) of the left lobe of the pancreas. The lobe appeared hypoechoic and enlarged and had irregular margins outlined by bright fat. ST –stomach; P – pancreas.

Comments

In the normal dog, the pancreas is a coarsely lobulated, thin, elongated organ that is divided into three portions: a thinner, longer right lobe, a thicker, shorter left lobe and a body or pancreatic angle. The mean thickness measurement of the pancreas is usually less than 1 cm: (Etue et al., 2001). Ultrasonographically, the normal pancreas has a homogeneous echotexture and is poorly delineated from surrounding structures as it has a similar echogenicity to the adjacent mesenteric fat and lacks capsular margination. Therefore, a recognition of anatomical landmarks is critical for identifying and examining this organ. The normal pancreas in the dog is relatively hypoechoic to the spleen, hyperechoic to the renal cortex, isoechoic or slightly hyperechoic to the caudate liver and isoechoic to the surrounding mesenteric fat (Penninck, 2008).

Abdominal ultrasonography is a valuable diagnostic tool in dogs suspected to have pancreatitis (Hess et al., 1998). It is highly specific but not particularly sensitive. The sonographic changes associated with pancreatitis vary with severity, duration and extent of pancreatic and peripancreatic tissue inflammation. The acute change is more classic than the chronic disease. In acute pancreatitis in the dog, the pancreas appears diffusely hypoechoic relative to the surrounding mesenteric fat, which becomes hyperechoic as the result of steatitis. It is

commonly enlarged with ill-defined or irregular margins. It may contain combined areas of edema, haemorrhage and necrosis, which appear as hypoechoic and anechoic areas. Changes in the pancreas may be accompanied by inflammation of adjacent stomach or duodenum, localized or generalized accumulation of peritoneal fluid, or mechanical obstruction of biliary tract. However, sonographic changes of pancreatitis may be similar to those of pancreatic abscess and neoplasia. The definitive diagnosis requires serial examination and ultrasound-guided fine-needle aspiration or biopsy.

References

- Etue, S.M., Penninck, D.G., Labato, M.A., Pearson, S. and Tidwell, A. 2001. Ultrasonography of the normal feline pancreas and associated anatomical landmarks: A prospective study of 20 cats. *Vet Radiol Ultrasound*. 42: 330-336.
- Hess, R.S., Saunders, H.M., Van Winkle, T.J., Shofer, F.S. and Washabau, R.J. 1998. Clinical, clinicopathologic, radiographic, and ultrasonographic abnormalities in dogs with fatal acute pancreatitis: 70 cases (1986-1995). *J Am Vet Med Assoc*. 213: 665-670.
- Penninck, D. 2008. Pancreas. In: *Atlas of Small Animal Ultrasonography*. 1st ed. D. Penninck and M.A. Anjou (eds.) Ames: Blackwell Publishing. 319-337.