

## Ophthalmology Snapshot

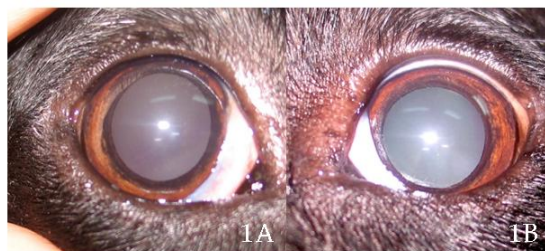Nalinee Tuntivanich

### *History*

A 4 year-old female spayed mix breed dog was brought to the Small Animal Teaching Hospital, Faculty of Veterinary Science, Chulalongkorn University for the third opinion on sudden onset blindness without previous history of trauma.

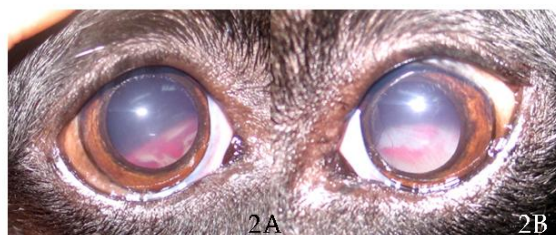
The dog abruptly lost her vision overnight. After 3 days of treatment by the first veterinarian and the dog's vision remained loss, the owner looked for another help from the second veterinarian. Still, the cause of blindness could not be identified, diagnosis could not be made, and the dog remained blinded. She was then referred to the Ophthalmology Clinic with this unsolved problem that had occurred for a total period of 10 days.

Ophthalmic examinations revealed no neuro-ophthalmic responses including menace response, dazzle reflex and pupillary light response on both eyes (Fig 1). The dog failed on maze test under light and dark conditions. Levels of STT 1 and IOP were within normal limits. Ocular surface appeared fine. Lenses were clear.



**Figure 1** Ophthalmic appearance of the right (1A) and the left (1B) eye.

Close ophthalmic examination of both eyes revealed as in Fig 2.



**Figure 2** Close ophthalmic appearance of the right (2A) and the left (2B) eye.

*(For better quality, figures can be viewed in the TJVM website)*

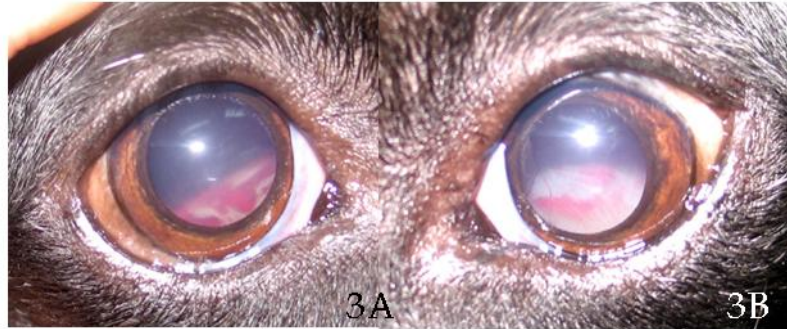
### **Question**

Give the diagnosis.

Please turn to the next page for answers .....

*Answers*

## Bilateral nonrhegmatogenous retinal detachment and retinal hemorrhage



**Figure 3** Close appearance of the eyes through fully dilated pupils illustrating bilateral elevated retina with blood underneath (ventrally viewed). Note: white spots above lesions represent reflection of flash light from taking photographs.

*Comments*

Retinal detachment is a separation between retinal pigmented epithelial layer and neurosensory retina. From ophthalmic examination, if the detached area is filled in with blood, the elevated retina will appear dull and red (Fig 2 or 3). Infection, inflammation or systemic disorders related to cardiovascular system are often a leading cause of nonrhegmatogenous retinal detachment or in this case; an exudative retinal detachment, from leakage of blood and fluid into subretinal space. Close ophthalmic examination of the fundus should be performed to differentiate between nonrhegmatogenous versus rhegmatogenous detachment. Usually rhegmatogenous retinal detachment is accompanied with tear or hole in the neurosensory retina; tractional detachment.

Visual impairment relies on area of retina that is detached. If focal, it is usually not affecting clinical vision. Large area of detachment, on the other hand, can cause acute blindness and therefore minimal chance to regain vision if treatment is prolonged. Administration of systemic corticosteroid and diuretics should instantly be prescribed as well as further investigation of the underlying causes.

*References*

- Wolfer, J., Grahn, B. and Arrington, K. 1998. Diagnostic ophthalmology. *Can Vet J.* 39: 57-58
- Grahn, B. and Wolfer, J. 1997. Diagnostic ophthalmology. *Can Vet J.* 38: 250-251
- Narfström, K. and Petersen-Jones, S.M., 2007. Diseases of the canine ocular fundus. In: *Veterinary Ophthalmology*. 4<sup>th</sup> ed. K.N. Gelatt (ed). Ames: Blackwell Publishing. 1008-1009.