

Histological Characteristics of Auditory Tube Diverticulum of Domestic Donkey (*Equus asinus*)

Seyed Morteza Ghazi¹ Behzad Mobini^{2*}

Abstract

The purpose of this study was to investigate histological characteristics of auditory tube diverticulum in domestic donkeys (*Equus asinus*) using conventional histological and histochemical methods. Specimens were collected from twenty regions (five different locations of each compartment of auditory diverticulum). The mucosa consisted of pseudostratified columnar epithelium with brush-like cilia and forms of some non-isometric folds. The few goblet cells, which were irregularly distributed over the whole luminal surface, reacted strongly with Alcian blue pH 2.5, whereas neutral mucosubstances were not observed. The lamina muscularis mucosa was absent. The lamina propria-submucosa contained all connective tissue fibers, tubulo-acinar glands, parasympathetic ganglia, nerve bundles, numerous diffuse or nodular lymphatic tissues, blood vessels, adipose tissue and skeletal muscles. There were some differences in type of epithelium and submucosal connective tissue, frequency of goblet cell and seromucosal gland between sexes and among the various regions.

Keywords: auditory tube diverticulum, domestic donkey (*Equus asinus*), histology, sex

¹ Graduated from School of Veterinary Medicine, Islamic Azad University, Shahrekord Branch, P.O.Box 166, Shahrekord- Iran.

²Department of Basic Sciences, College of Veterinary Medicine, Islamic Azad University, Shahrekord Branch, P.O. Box: 166. Shahrekord, Iran

*Correspondence author E-mail: dr.mobini@iaushk.ac.ir

บทคัดย่อ

ลักษณะทางจุลกายวิภาคของ diverticulum ของท่อหูลา (*Equus asinus*)

Seyed Morteza Ghazi¹ Behzad Mobini^{2*}

วัตถุประสงค์ของการศึกษานี้เพื่อศึกษาลักษณะทางจุลกายวิภาคของ diverticulum ของท่อหูลาเลี้ยง (*Equus asinus*) โดยใช้วิธีการทางเนื้อเยื่อวิทยาและฮิสโตเคมี เก็บตัวอย่างรวบรวมจากยี่สิบภูมิภาค (จากห้าตำแหน่งที่ต่างกันของช่องหูแต่ละส่วนใน diverticulum) ชั้นเยื่อเมือกประกอบด้วยเยื่อบุผิวประเภท pseudostratified columnar ที่มีซิเลียแบบขนแปรงและมีการพับไปมาไม่สมมาตร พบการกระจายตัวของ goblet cell ไม่สม่ำเสมอทางด้านในท่อ โดยติดสีย้อม Alcian blue ที่ pH 2.5 โดยไม่พบสาร mucosubstance ไม่พบชั้น lamina muscularis mucosa ในขณะที่ชั้น lamina propria-submucosa ประกอบด้วยเส้นใยเนื้อเยื่อเกี่ยวพัน ต่อม tubulo-acinar ปมประสาท parasympathetic กลุ่มของเส้นประสาท เนื้อเยื่อน้ำเหลืองทั้งที่กระจายตัวและอยู่เป็นต่อม หลอดเลือด เนื้อเยื่อไขมันและกล้ามเนื้อโครงร่าง นอกจากนี้พบความแตกต่างบางประการในส่วนของเยื่อบุผิวและเนื้อเยื่อเกี่ยวพันในชั้น submucosa จำนวน goblet cell และต่อม seromucosal ระหว่างเพศและส่วนต่างๆ ของท่อได้

คำสำคัญ: diverticulum ของท่อหู ลา (*Equus asinus*) จุลกายวิภาค เพศ

¹Graduated from school of Veterinary Medicine, Islamic Azad University, Shahrekord Branch, P.O. Box: 166. Shahrekord, Iran

²Department of Basic Sciences, College of Veterinary Medicine, Islamic Azad University, Shahrekord Branch, P.O. Box: 166. Shahrekord, Iran

*ผู้รับผิดชอบบทความ E-mail: dr.mobini@iaushk.ac.ir

Introduction

Auditory tube diverticula or guttural pouches are air-filled evaginations of the auditory tubes present in perissodactyls such as donkey (Sasaki et al., 1999; Dyce et al., 2002; Alsafy et al., 2008; Oto and Hazirolu, 2011; Ghazi et al., 2012), horse (Sasaki et al., 1999; Lepage et al., 2004; Parillo et al., 2009^{a,b}) and tapir (Sasaki et al., 1999). The diverticula are located in the caudal area of the head, under the base of the skull and the atlanto-occipital joint (Ghazi et al., 2012). In the medial plane, the right and left diverticula are in contact with each other by a thin septum (Sasaki et al., 1999; Lepage et al., 2004; Alsafy et al., 2008; Ghazi et al., 2012). From the lateral aspect, the stylohyoid bone incompletely divides each diverticulum into lateral and medial compartments (Baptiste et al., 2000; Ghazi et al., 2012). The auditory diverticula have important anatomical relationships with other neighbouring structures such as several cranial nerves, cranial cervical ganglion, cranial sympathetic trunk, blood vessels (Manglai et al., 2000; Lepage et al., 2004; Liebich and König, 2004; Ghazi et al., 2012) and retropharyngeal lymph nodes (Lepage et al., 2004). Ghazi et al. (2012) described that the opening of the pharyngeal part of auditory tube in domestic donkey was like a triangle shape orifice.

Recent evidence demonstrates that the auditory diverticula have an important function in the bray mechanism (Ghazi et al., 2012), physiology of swallowing (Hodgson, 1998; Sasaki et al., 1999) and also in brain cooling, which regulate the temperature

of arterial blood circulating to the brain (Mitchell et al., 2006), during exercise, keeping the brain from overheating (Baptiste et al., 2000). It is well-known that the domestic donkey (*Equus asinus*) possessed relative large symmetric auditory tube diverticula (Manglai et al., 2000; Liebich and König, 2004; Alsafy et al., 2008; Oto and Hazirolu, 2011; Ghazi et al., 2012), although their size is lesser than those in horses (Manglai et al., 2000; Liebich and König, 2004; Ghazi et al., 2012). Although some advanced studies give adequate detail on the histological characteristics of the auditory tube diverticulum of the horse (Manglai et al., 2000; Parillo et al., 2009^{a,b}), to the author's best knowledge, no research had been done on the histology of the auditory tube diverticula of domestic donkey. Therefore, in this work we investigated the histological characteristics of the auditory tube diverticulum of domestic donkey (*Equus asinus*).

Materials and Methods

Four clinically healthy adult domestic donkeys (*Equus asinus*) of both sexes (2 of each sex), weighing 140-155 kg, at the Department of Anatomy, College of Veterinary Medicine, Shahrekord Islamic Azad University, Shahrekord, Iran, were employed in this study. Deep anesthesia was made by using combination of xylazine hydrochloride and ketamine hydrochloride. The animals were exsanguinated and perfused with 10% neutral buffered formalin. The guidelines of the ethical committee of Shahrekord

Azad University were strictly followed during the procedure. All the heads were cut off transversely at the level of the sixth cervical vertebra. Transverse section of the donkey's head passed at the level of the medial canthus of the eyes, whereas median section passed longitudinally on the head. Samples from the medial and lateral compartments of each auditory diverticulum were obtained from the following five different locations: the rostral part, middle part, caudal part, dorsal part and ventral part. All the specimens were immediately fixed in neutral buffered formalin solution for 24 hours, subjected to routine tissue processing for light microscopic examination and embedded in paraffin blocks. Serial sections (5 μ m) were stained with hematoxylin-eosin for routine histological examination, Van Gieson's (for collagen fibers), Verhoeff's (for elastic fibers) and Gomori's staining for reticulum. To investigate the chemical character (pH) of the secretion material in the epithelial cells, periodic acid-Schiff (PAS) reaction was employed to determine neutral mucosubstance and alcian blue (AB) (pH 2.5) was used for determining acidic mucosubstances (Kiernan, 1999). Histological studies on stained sections were carried out by light microscopy.

Results and Discussion

Light microscopic examination revealed that the auditory diverticulum of the domestic donkeys was composed of tunica mucosa and tunica submucosa in all different locations (Fig 1). The tunica mucosa of auditory diverticulum was mainly lined by pseudostratified columnar epithelium with brush-like cilia (Fig 2). However, in some regions (especially lateral compartment of right auditory diverticulum in males and right medial compartment of female's auditory diverticulum) it varied from non ciliated stratified cuboidal to columnar. This variation in females was slightly higher than in males. Tunica mucosa formed some folds which appeared to be irregularly distributed over the whole luminal surface of the auditory diverticulum. The mucosal folds of varied heights were almost simple and non-isometric.

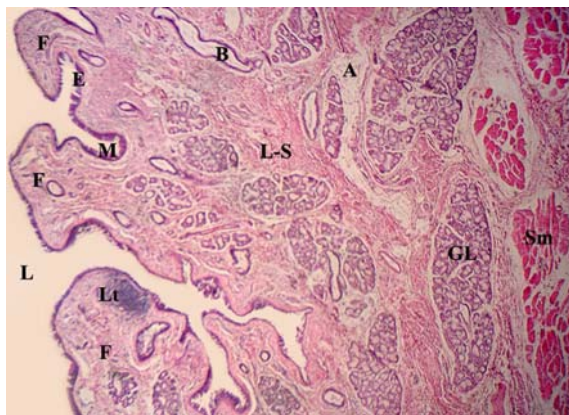


Figure 1 Auditory tube diverticulum of domestic donkey. tunica mucosa (M), lamina propria-submucosa (L-S), epithelium (E), mucosal fold (F), lymphatic tissues (Lt), seromucosal glands (GL), skeletal muscles (Sm), adipose tissue (A), blood vessels (B), Lumen (L). H&E, x 100

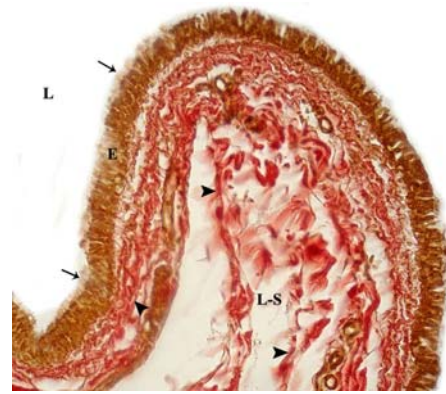


Figure 2 Collagenous fibres (arrowheads) in lamina propria-submucosa (L-S) of auditory diverticulum of domestic donkey, epithelium (E), brush-like cilia (arrows), Lumen (L). Van gieson's, x 400

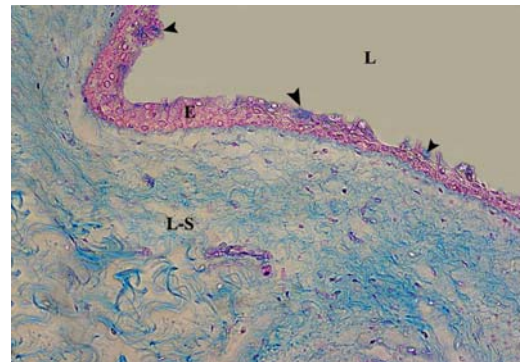


Figure 3 Acidophilic mucosubstances are present in all goblet cells (arrowheads). epithelium (E), lamina propria-submucosa (L-S). Alcian blue, x400

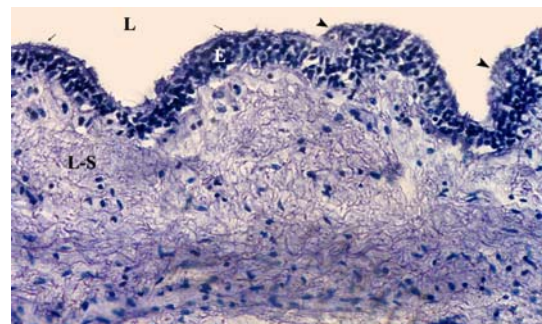


Figure 4 Neutral mucosubstances are absent in all goblet cells (arrowheads). brush-like cilia (arrows), epithelium (E), lamina propria-submucosa (L-S), Lumen (L). PAS, x 400

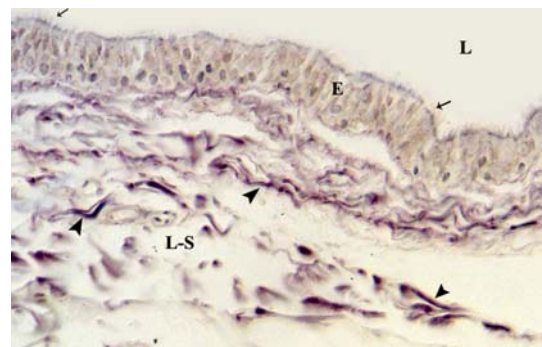


Figure 5 Reticular fibres (arrowheads) in lamina propria-submucosa (L-S), of auditory diverticulum of domestic donkey, epithelium (E), brush-like cilia (arrows), Lumen (L). Gomori's staining for reticulum, x 400

However, in some regions the shape and arrangement of these folds varied as branched, anastomotic, or constituted by foliaceous villosities (Fig 1). The highest and lowest mucosal folds were found respectively in the right medial compartment of males and right lateral compartment of female's auditory diverticulum.

A few goblet cells were observed in the epithelium, which appeared to be irregularly distributed over the whole luminal surface of the auditory diverticulum in both sexes. The numbers of goblet cells differed between sexes and among the various regions. The majority of the goblet cells reacted strongly with AB pH 2.5 (Fig 3), whereas neutral mucosubstances was not present (Fig 4). The lamina propria-submucosa of auditory diverticulum in both sexes was formed by frame of connective tissue containing collagenous (Fig 2), reticular (Fig 5), elastic fibers (Fig 6), numerous diffuse or nodular lymphatic tissues, blood vessels, tubulo-acinar glands, adipose tissue, skeletal muscles (Fig 1), nerve bundles and parasympathetic ganglia (Fig 6). The connective tissue of lamina propria-submucosa, which varied from loose to dense irregular type in male donkeys, as well as in medial compartment, were more observed to be of loose type as compared to females and lateral compartment of auditory diverticulum. The seromucosal glands were occasionally seen in male donkeys but were numerous in the females. These glands in lateral compartment of auditory diverticulum were numerous higher than in medial compartment. The lamina muscularis mucosa was absent in all different locations of auditory diverticulum in both sexes.

The auditory diverticulum of domestic donkeys was composed of tunica mucosa and tunica submucosa, which was similar to those of horse (Manglai et al., 2000; Parillo et al., 2009^{a,b}). Although some variations were observed in the epithelium of tunica mucosa, it was mainly lined by pseudostratified columnar epithelia with brush-like cilia similarly to the reports of Parillo et al. (2009^{a,b}) in horse. In contrast, Manglai et al. (2000) reported that the mucosa of the horse auditory diverticulum was consisted of stratified columnar epithelia.

Previous studies demonstrated that mucosa of the horse auditory diverticulum provided foreign substance clearance ability, but that its ability varied among different regions of the epithelium (Manglai et al., 2000).

In the present study, the histology of the auditory diverticulum revealed differences between the male and female domestic donkeys in the epithelial type, height of mucosal folds, goblet cell frequency, connective tissue type of lamina propria-submucosa and seromucosal gland frequency. Manglai et al. (2000) reported the sex effect on goblet cell frequency and the thickness of lamina propria in equine auditory tube diverticulum, whereas Parillo et al. (2009^{a,b}) reported non-sex related differences between male and female horse. The higher mucosal folds in auditory diverticulum of male donkeys may

be due to the bray mechanism (Lindsay and Clayton, 1986).

In horse, the numerous goblet cells were reported in auditory diverticulum mucosa which were topographically located mainly on the basis of the folds (Parillo et al., 2009^{a,b}), but in the present study, few goblet cells were observed which interspersed among the epithelial cells in the whole luminal surface of the auditory diverticulum.

On the basis of these results, the numbers of goblet cells differed between sexes and among the various regions of the epithelium which is in agreement with the results reported by Manglai et al. (2000) and Parillo et al. (2009^{a,b}). AB-positive reactions of the majority of the goblet cells in domestic donkey auditory diverticula mirror the findings of Parillo et al. (2009^b) in horse. Parillo et al. (2009^b) reported that in horse the majority of the goblet cells reacted strongly with PAS. These investigators concluded that the glycosaminoglycans provided a hydrophilic environment that prevented dehydration and desiccation of the guttural membranes during air passage. Additionally, the presence of these glycosaminoglycans might be of importance in relation to the pathogenesis of some bacterial disease in horses such as equine strangles and involved in host defence. But in the present study, neutral mucosubstances were not observed in the goblet cells of the auditory diverticulum in domestic donkeys.

Reported submucosal glands of the auditory diverticulum in donkey (Abdel Rahman et al., 1994) and horse (Parillo et al., 2009^{a,b}) which contained both serous and mucous secretory granules were in agreement with our results. Some researchers (Abdel Rahman et al., 1994; Parillo et al., 2009^{a,b}) reported that the submucosal glands were tubulo-acinar type, which agrees with the results obtained from this

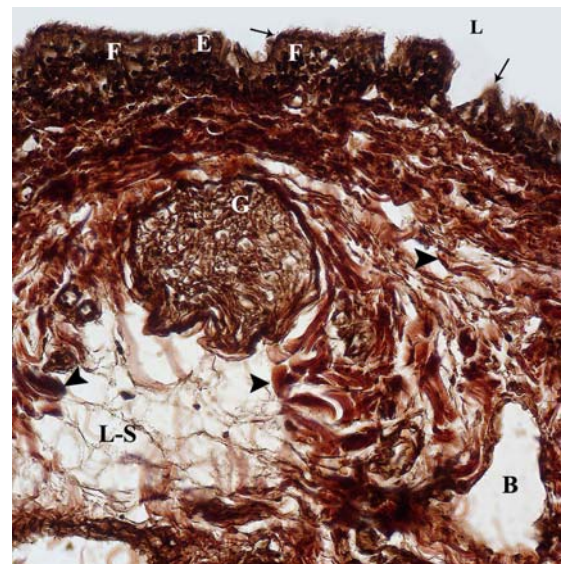


Figure 6 Elastic fibres (arrowheads), parasympathetic ganglion (G) and blood vessels (B) in lamina propria-submucosa (L-S) of auditory diverticulum of domestic donkey. epithelium (E), brush-like cilia (arrows), mucosal fold (F), Lumen (L). Verhoeff's, x 400

study. The finding of lipids within the submucosal glands of the auditory diverticulum was reported in donkey (Abdel-Rahman et al., 1994) and horse (Parillo et al., 2009^{a,b}). Abdel-Rahman et al. (1994) described the occurrence of lipid droplets in serous acinar cells and argued that these cells were responsible for phospholipid secretion. Baptiste and Cake (1994) demonstrated that the presence of phospholipid compounds involved in protection of the tubal membrane from corrosion, defensive mechanisms and the facilitation of fast pressure equilibration. But in the present study, lipid droplets were not observed in the submucosal glands of the auditory diverticulum in domestic donkeys.

In the present study, the submucosal glands in the lateral compartment of auditory diverticulum, as well as the females, were more numerous as compared to medial compartment and males, whereas Parillo et al. (2009^{a,b}) reported no differences between sexes and among the various regions.

In conclusion, the present study is the first report regarding the histological structures of the auditory diverticulum in domestic donkeys. The histological properties of the auditory diverticulum in domestic donkeys were generally similar to those of horse except for the goblet cells, which were few and interspersed among the epithelial cells, the absence of neutral mucosubstances and lipid droplets in auditory diverticulum. Epithelial type, height of mucosal folds, goblet cell frequency, submucosal connective tissue type and seromucosal gland frequency differed between sexes and among the various regions studied.

References

- Abdel-Rahman YA, Abou-Elmagd A and Salem AO 1994. Morphological studies on the guttural pouch of donkey: II - The subepithelial glands. *Assiut Vet Med J*. 32: 39-51.
- Alsafy MAM, El- Kammar MH and El-Gendy SAA 2008. Topographical anatomy, computed tomography and surgical approach of the guttural pouches of the donkey. *J Equine Vet Sci*. 28: 215-222.
- Baptiste KE and Cake MH 1994. Lipid analysis of lavage samples from the equine guttural pouch (auditory tube diverticulum). *Ann Otol Rhinol Laryngol*. 103: 383-388.
- Baptiste KE, Naylor JM, Bailey J, Barber EM, Post K and Thornhill J 2000. Physiology: A function for guttural pouches in the horse. *Nature*. 403: 382-383.
- Dyce KM, Sack WO and Wensing CJG 2002. *Textbook of Veterinary Anatomy*. 3rd ed. WB Saunders Philadelphia: 496-501.
- Ghazi SM, Mobini B and Afsharzadeh MR 2012. Topographical and morphological anatomy of the guttural pouches of the domestic donkey (*Equus asinus*). *Global Veterinaria*. 9(6): 691-695.
- Hodgson DR 1998. What is the function of the guttural pouches: Selective brain cooling? Augmentation of swallowing? Still to be defined. *Vet J*. 155: 115-117.
- Kiernan JA 1999. *Histological and Histochemical Methods: Theory and Practice*. 3rd ed. Butterworth Heinemann: Oxford, Boston: 103-132.
- Lepage OM, Perron MF and Cadore JL 2004. The mystery of fungal infection in the guttural pouches. *Vet J*. 168: 60-64.
- Liebich HG and König HE 2004. Vestibulocochlear organ. In: *Veterinary Anatomy of the Domestic Mammals*. 4th ed. HE König and HG Liebich (eds). Schattauer, Stuttgart: 577-579.
- Lindsay FEF and Clayton M 1986. An anatomical and endoscopic study of the nasopharynx and larynx of the donkey (*Equus asinus*). *J Anat*. 144: 123-132.
- Manglai D, Wada R, Kurohmaru M, Yoshihara T, Kuwano A, Oikawa M and Hayashi Y 2000. Histological and morphometrical studies on the mucosa of the equine guttural pouch (auditory tube diverticulum). *Okajimas Folia Anat Jpn*. 76: 335-346.
- Mitchell G, Fuller A, Maloney SK, Rump N and Mitchell D 2006. Guttural pouches, 10 brain temperature and exercise in horses. *Biol Lett*. 2: 475-477.
- Oto C and Haziroglu RM 2011. Magnetic resonance imaging of the guttural pouch (diverticulum tubae auditivae) and its related structures in donkey (*Equus asinus*). *Ankara univ Vet Fak Derg*. 58: 1-4.
- Parillo F, Arias MP and Verini Supplizi A 2009^a. Glycoprofile of the different cell types present in the mucosa of the horse guttural pouches. *Tissue Cell*. 41: 257-265.
- Parillo F, Rossi G, Busoni V, Magi GE and Verini Supplizi A 2009^b. Differentiation of glycans in equine guttural pouches. *Vet J*. 180: 246-252.
- Sasaki M, Hayashi Y, Koie H, Yamaya Y, Kimura J, Manglai D, Kawashima S, Endo H and Yamamoto M 1999. CT examination of the guttural pouch (auditory tube diverticulum) in Przewalski's horse (*Equus przewalskii*). *J Vet Med Sci*. 61: 1019-1022.

