

Ejaculate Characteristics of Captive Malayan Tapirs (*Tapirus indicus*)

Wanlaya Tipkantha^{1,6,7*} Budhan Pukazhenth² Boripat Siriaroonrat¹ Ampika Thongphakdee¹
Umaporn Maikaew³ Warisara Thomas⁴ Daraka Tongthainan³ Jessada Thaeonon³
Sumate Kamolnorrath¹ Mitchell Bush^{2,8} Sithawee Thongtipsiridech^{5,6,7*}

Abstract

The aims of this study were to optimize semen collection by electroejaculation and characterize ejaculate characteristics in Malayan tapir (*Tapirus indicus*). Eight adult males (4-20 years of age) were anesthetized using a combination of medetomidine HCl (0.012-0.018 mg/kg), butorphanol tartrate (0.012-0.018 mg/kg), and ketamine HCl (5-7 mg/kg) administered intramuscularly via a dart and subjected to electroejaculation. Ejaculates (milky-white to yellowish color) were successfully collected from all males. Averages (Mean±SD) of the seminal traits (volume, pH, osmolality, sperm concentration, total sperm motility, and viability) were 10.3±9.4 ml, 7.4±3.4, 278.6±13.3 mOsm, 206.2±185.4×10⁶ spermatozoa/ml, 24±15.4%, and 35.1±6.5%, respectively. Morphological analysis showed low percentage of normal spermatozoa 6.7±2.6 % with 39.2±8.5% intact acrosomes. This is the first study to evaluate semen characteristics and sperm morphology in the Malayan tapirs. Results provide fundamental information essential for development of assisted reproductive technologies in this species.

Keywords: Malayan tapir, Semen collection, Seminal traits

¹ Bureau of Conservation, Research and Education, Zoological Park Organization, Bangkok, 10300, Thailand

² Smithsonian Conservation Biology Institute, National Zoological Park, 1500 Remount Road, Front Royal, VA 22630, USA

³ Khao Kheow Open Zoo, Bangpra, Sriracha, Chonburi, 20110, Thailand

⁴ Nakornratchasrima Zoo, Mueng, Nakornratchasrima, 30000, Thailand

⁵ Faculty of Veterinary Medicine, KamphaengSaen Campus, NakornPathom, 73140, Thailand

⁶ Center for Agricultural Biotechnology, Kasetsart University, KamphaengSaen Campus, NakornPathom, 73140, Thailand

⁷ Center of Excellence on Agricultural Biotechnology: (AG-BIO/PERDO-CHE), Bangkok, 10900, Thailand

⁸ Adelaide Zoo, Frome Rd., Adelaide, 5000, South Australia

*Corresponding author: E-mail: wanlayav62@gmail.com, foetnit@ku.ac.th

บทคัดย่อ

คุณลักษณะน้ำเชื้อของสมเสร็จในสภาพเพาะเลี้ยงของประเทศไทย

วัลยา ทิพย์กันทา^{1,6,7*} บุदान พุคาเรนต์² บริพัตร ศิริอรุณรัตน์¹ อัมพิกา ทองภักดี¹ อุมภาพร ใหม่แก้ว³ วริศรา โทมัส⁴
ดารกา ทองไทยนนท์³ เจษฎา แก้วเนิน³ สุเมธ กมลนรนาถ¹ มิตเชล บุษ^{2,8} สิทธิวีร์ ทองทิพย์ศิริเดช^{5,6,7,*}

การศึกษานี้มีวัตถุประสงค์ เพื่อพัฒนากระบวนการรีดเก็บน้ำเชื้อสมเสร็จด้วยเครื่องกระตุ้นการหลั่งน้ำเชื้อด้วยกระแสไฟฟ้าและตรวจประเมินคุณภาพและลักษณะของน้ำเชื้อรวมถึงตัวอสุจิของสมเสร็จที่อยู่ในสภาพการเพาะเลี้ยง ทำการศึกษาโดยการวางยาสลบสมเสร็จเพศผู้ ตัวเต็มวัยอายุระหว่าง 4-20 ปี จำนวน 8 ตัว ด้วยสูตรยาที่ประกอบด้วย 1) medetomidine HCl (0.012-0.018 มก./กก.) 2) butorphanol tartrate (0.012-0.018 มก./กก.) และ 3) ketamine HCl (5-7 มก./กก.) กระตุ้นการหลั่งน้ำเชื้อสมเสร็จด้วยกระแสไฟฟ้าที่ระดับ 2-7 โวลต์ จำนวน 80-140 ครั้ง ซึ่งสามารถรีดเก็บน้ำเชื้อลักษณะเหลว สีขาวขุ่นคล้ายนํ้านมจนถึงใส โดยปริมาตรเฉลี่ย 10.3±9.4 มล. มีค่าความเป็นกรดต่าง 7.7±3.4 ค่าออสโมลาริตี 278.6±13.3 มิลลิออสโมล การเคลื่อนไหวตัวอสุจิเฉลี่ยร้อยละ 24±15.4 ความเข้มข้นตัวอสุจิ 206.2±185.4 ล้านตัวต่อมล. จำนวนอสุจิมีชีวิตร้อยละ 35.1±6.5 ผลการตรวจประเมินลักษณะรูปร่างตัวอสุจิพบตัวปกติเพียง ร้อยละ 6.7±2.6 และตรวจพบความสมบูรณ์ของอะโครโซมบนหัวอสุจิลดลง ร้อยละ 39.2±8.5 การศึกษาครั้งนี้เป็นการศึกษากระบวนการรีดเก็บและคุณลักษณะของน้ำเชื้อตัวอสุจิของสมเสร็จเป็นครั้งแรก ผลการศึกษานี้จะเป็นฐานข้อมูลที่เป็นประโยชน์สำหรับการศึกษาเพื่อพัฒนาเทคโนโลยีช่วยสืบพันธุ์ในสมเสร็จต่อไปในอนาคต

คำสำคัญ: สมเสร็จ การรีดเก็บน้ำเชื้อ ลักษณะน้ำเชื้อ การประเมินความสมบูรณ์พันธุ์

¹ สำนักอนุรักษ์ วิจัย และการศึกษา องค์การสวนสัตว์ในพระบรมราชูปถัมภ์ กรุงเทพฯ 10300

² สวนสัตว์แห่งชาติ สถาบันสมิธโซเนียน 1500 ถนนเรนอมอนด์ ฟอนต์รอยล์ รัฐเวอร์จิเนีย 22630 สหรัฐอเมริกา

³ สวนสัตว์เปิดเขาเขียว อ.ศรีราชา จ.ชลบุรี 20110

⁴ สวนสัตว์ราชสีมา อ.เมือง จ.นครราชสีมา 30000

⁵ คณะสัตวแพทยศาสตร์ มหาวิทยาลัยเกษตรศาสตร์ วิทยาเขตกำแพงแสน จ.นครปฐม 73140

⁶ ศูนย์เทคโนโลยีชีวภาพเกษตร มหาวิทยาลัยเกษตรศาสตร์ วิทยาเขตกำแพงแสน จ.นครปฐม 73140

⁷ ศูนย์ความเป็นเลิศด้านเทคโนโลยีชีวภาพเกษตร สำนักพัฒนาบัณฑิตศึกษาและวิจัยด้านวิทยาศาสตร์และเทคโนโลยี สำนักงานคณะกรรมการการอุดมศึกษา กรุงเทพฯ 10900

⁸ สวนสัตว์อเดเลด ถนนไพรม์ อเดเลด 5000 ออสเตรเลีย

*ผู้รับผิดชอบบทความ E-mail: wanlayav62@gmail.com, fvetnit@ku.ac.th

Introduction

Malayan tapirs (*Tapirus indicus*; Desmarest, 1891) are large odd-toed herbivores in the Order Perissodactyla. They are listed as endangered by the IUCN Red list (Lynam et al., 2011). There are four species of tapirs including three American species: 1) Lowland tapir (*T. terrestris*) 2) Mountain tapir (*T. pinchaque*) and 3) Baird's tapir (*T. bairdii*) and an Asian species, the Malayan tapir. Malayan tapirs are distributed in the tropical rain forest of Southeast Asia (Lekagun and McNeely, 1977).

In Thailand, the Malayan tapir is a reserved animal and is listed as critically endangered by the Thailand Office of Environmental Policy and Planning (OEPP, 1997). Current wild populations are highly fragmented and continue to decline due to deforestation, loss of habitat and overexploitation

(Mace et al., 2000; Lynam et al., 2011). *Ex situ* conservation program of Malayan tapir has been established in many institutions worldwide. The recent global captive population comprises of 261 animals distributed among 79 institutions (Prastiti, 2010) and approximately 42 individuals reside in Thailand (last update October 2011).

It has been reported that the Malayan tapir reaches sexual maturity at 2-5 years of age (Kuehn, 1978). Previous endocrinology studies of tapir showed no evidence of seasonality (Brown et al., 1994; Kusuda et al., 2007). The gestation period is reported between 380-405 days (Kuehn, 1978) producing a single calve and only rare twins (Zahari et al., 2008). The limited number of founders in captivity has led to inbreeding depression in captive population. Furthermore, there were some reports about unsuccessful mating of breeding pairs, which resulted in no offspring (Sumate Kamolnoranath, 2011 personal data). Preliminary assessment revealed that the causes of

mating failures consisted of undesired aggressive behavior of male, infertility and health condition of animals. Furthermore, slow reproductive rate of tapir in terms of gestation period and long inter-birth interval (average 2-3 years) made it difficult for the species to rapid recover from low population numbers.

Ex situ conservation plays an important role in preserving living genetic resource and diversity in highly endangered species (Pukazhenthhi and Wildt, 2004). Captive management programs combined with assisted reproductive technologies (ARTs) have facilitated the recovery of numerous species including the black-footed ferret (Howard et al., 2003), clouded leopard (Howard et al., 1996) and Przewalski horse (Summer et al., 1987; Monfort et al., 1991). Artificial insemination (AI) with fresh or frozen/thawed sperm also has been used successfully to preserve and manage genetic diversity in selected wildlife species (Wildt, 2009). The use of a proven genome resource bank (GRB) also is an effective tool to ensure that genetic viability is maintained for long-term genetic health. Semen from free-living individuals has successfully been used to increase genetic diversity via AI in captive populations of giant panda (Moore et al., 1984) and Asian elephants (Brown et al., 2004; Thongtip et al., 2009).

The understanding of reproductive parameters and physiology is critical for developing the ARTs in novel species (Pukazhenthhi and Wildt, 2004). The fertility assessment contributes to an understanding of an individual's potential reproductive performance. Semen analysis also permits the systematic examination and evaluation of the male germ cells (spermatozoa). Examination of reproductive organs and assessment of semen quality have been used to predict fertilizing potential in domestic animals such as the boars, bulls and stallions (Amann, 1989; Colenbrander, 1992). The successful manipulation of spermatozoa for ARTs requires a thorough understanding of male reproductive biology, physiology as well as endocrinology with the ability to collect, evaluate and sustain and/or improve their viability. Ejaculate quality is highly species specific. It requires in-depth studies of targeted species. Spermatozoa of some endangered species have been successfully stored by cryopreservation in several species including the black rhinoceros (Roth et al., 2005), white rhinoceros (Roth et al., 2005), African elephant (Howard et al., 1984), and neotropical Baird's tapir (Pukanzhenthhi, 2011). The specific aims of this study were to 1) develop a safe and consistent method including anesthesia for semen collection using electro-ejaculation, and 2) to evaluate and characterize the ejaculate traits in the Malayan tapir semen for the future ARTs studies.

Materials and Methods

Animal: Captive male Malayan tapirs (4-20 years old, n=8) were used in this study. The body weight for all animals was estimated (250-300 kg). Animals were maintained in 4 zoos under the Zoological Park Organization (ZPO): 1) KhaoKheow Open Zoo

(KKOZ, n=3), 2) Nakhonratchasima Zoo (NRZ, n=2), 3) Chiang Mai Zoo (CMZ, n=1) and 4) Songkhla Zoo (SKZ, n=2).

Animal anesthesia: The animals were anesthetized using a MBK combination consist of medetomidine HCl (0.012-0.018 mg/kg), butorphanoltartrate (0.012-0.018 mg/kg), and ketamine HCl (5-7 mg/kg). All three drugs were purchased from ZooPharm®, Fort Collins, Colorado, USA. They are mixed in a single dart and administered (intramuscularly) via a dart (DanInject®, Denmark). Some individuals were supplemented with ketamine HCl and/or Guaifenesine (GG; VedcoInc., Saint Joseph, USA) administered intravenously to achieve the optimal level of anesthesia for electro-ejaculation (EEJ). During anesthesia, physiological parameters including respiration rate, heart rate, pulse rate and body temperature were monitored and recorded. The blood oxygen saturation was measured using pulse oximeter (N-600x™ Pulse Oximeter, COVIDIEN, Boulder, CO). An endotracheal tube (16-20 mm diameter) was inserted for respiratory management (Bush, 1996). The positive respiration pressure was maintained by pumping the oxygen via the endotracheal tube to maintain the optimal hemoglobin oxygen saturation (>95%). After all procedures were completed, the medetomidine HCl and butorphanoltartrate were reversed with atipamezole (0.07-0.09 mg/kg; Antisedan®, Pfizer Inc, New York, USA) and Naltrexone (0.36-0.47 mg/kg; ZooPharm®, Fort Collins, Colorado, USA) via an intramuscular injection.

Testicular assessment: Tapir testes were examined for testicular size and tonicity (Fig 1). The testes were measured for length (L), width (W) and height (H) using the Vernier caliper (Mitutoyo, Japan). These values were then used to calculate the testicular volume using the formula: Volume (cm³) = 0.5233 x LxWxH (Howard et al., 1983; Love, 1992; and Pukazhenthhi et al., 2011).

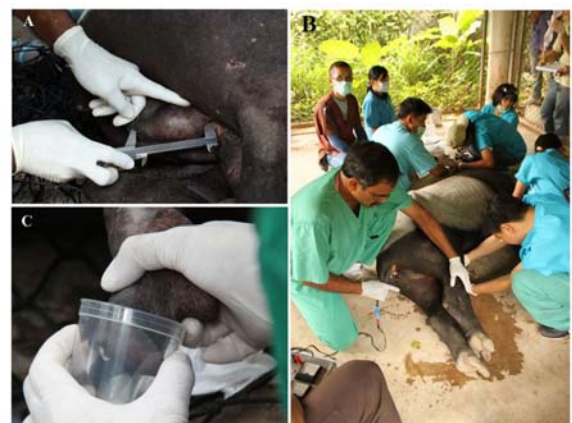

Figure 1 Semen collection by electroejaculation in a Malayan tapir (A-C). A) Testes were measured using a Vernier caliper prior to semen collection; B) A rectal probe with three longitudinal electrodes was inserted into the rectum and electrical stimuli applied. Another person assisting with the collection, directed the penis into a sterile polypropylene specimen cup; and C) Ejaculates appeared milky white.

Semen collection by electro-ejaculation: Semen collections (n=8 males; 14 ejaculates total) were conducted from July 2010 through June 2011. The tapirs were subjected to a standardized electro-ejaculation procedure as described by Pukazhenthil et al. (2011). Briefly, a lubricated rectal probe (5.2 cm diameter with three longitudinal electrodes) was inserted approximately 15 cm into the rectum with the 3 electrodes directed ventrally and connected to a 60 Hz sine wave electro-ejaculator (PT Electronics, Boring, Oregon). A series of electrical stimuli were initiated at 2 volts (V) (3-5 stimulation) and gradually increased to 3 V (3-5 stimulation), 4 V (10-20 stimulation), 5 V (10-20 stimulations) and 6 or 7 (10-20 stimulation), respectively. The higher volt as 8 V has been challenged in case of some animals which were actively ejaculating. The stimulations were continued at the current voltage or gradually increasing until the ejaculation occurred. Ejaculates were collected into sterile polypropylene specimen cups (8 oz) and maintained at ambient temperature (28-30 °C) and kept in a styrofoam box to avoid exposure to light until evaluated.

Semen evaluation: Ejaculates were immediately evaluated for the appearance, volume and pH (MERCK, Darmstadt, Germany). Semen motility (0-100%) and forward progressive status (0-5) were initially evaluated using a light microscope (Howard, 1993). Sperm concentration was determined using a hemocytometer and total sperm per ejaculate was determined by multiplying sperm concentration/ml with total ejaculate volume. Semen osmolality was measured using an osmometer (Osmomat®, Gonotec GmbH, Berlin, Germany). To assess sperm viability, samples were stained using eosin-nigrosin staining and/or aniline blue staining (World Health Organization, 2010) and 200 spermatozoa per sample were examined.

Sperm morphology assessment: An aliquot (20 µl) of raw ejaculate was fixed in 100 µl of 0.3% glutaraldehyde in PBS (pH 7.4, 340 mOsm). A second aliquot (2 µl) was placed on a (warmed) slide with a cover slip. Sperm morphology was assessed at 1000x using a phase contrast microscope (Olympus, Tokyo, Japan) and 200 spermatozoa were evaluated per sample.

Acrosome integrity: Aliquots (5-20 µl) of neat ejaculate were fixed in 0.5 ml of 4% paraformaldehyde solution (pH 7.4) (Hass et al., 1988) at room temperature for 15 minutes then stored at 4°C until processed for Coomassie blue staining. Two hundred spermatozoa were counted for acrosome status.

Statistical analysis: Data were analyzed using NCSS (NCSS LLC., Utah, USA). Semen characteristics were examine using descriptive analysis and presented as mean±SD.

Results

Semen collection: A total of 14 semen collections was conducted on eight males (1-3 ejaculates per male). Spermic ejaculates were obtained from all males. Some males (n=4) appeared to ejaculate

spontaneously during palpation of the accessory sex glands, however, spermatozoa were immotile. All males responded to electrical stimuli with muscle contractions starting from 2 V and gradually increased to 3, 4, 5, 6, and 7 V (Table 1). In two males, stimulation at 7 V resulted in a slight arousal and one tapir tolerated stimulations at 8 V with minimal adverse effects. In all procedures, ejaculates were obtained starting at 3 V stimulation.

Testicular measurement: The Malayan tapir testes were ellipsoidal in shape, located at the cranioventral portion of the anus within a slightly pendulous scrotum. It was most convenient to measure the testes when the animal was in standing position. When placed on lateral recumbence, in some tapirs, the testes could not be palpated or measured because they retracted into the inguinal canal or abdomen. In this study, we could measure testicular sizes in only four males. All of them had normal tonicity and no evidence of scar or granulation tissue inside the testes were found. Testicular dimensions and calculated volume are shown in Table 2.

Semen characteristic: Ejaculates were thick, creamy and milky white with one ejaculate appearing creamy brownish and sticky. The semen of all collection was assessed under light microscope. The results showed the ejaculate quality varied among individuals. Mean±SD of the seminal traits were 10.3±9.4 ml, 7.4±3.4 and 278.6±13.3 mOsm for semen volume, pH and osmolality, respectively. Ejaculates contained 206.1±185.4x10⁶ spermatozoa/ml with 24±15.4% motile sperm and 2.0±0.2 wave motion score

Spermatozoa morphology: Most ejaculates contained a high proportion of morphologically abnormal sperm (92%) with only 6.7±2.6% morphologically normal. The percentage of intact acrosomal membrane was 39.2±8.5% (Fig 2). The mean proportion of primary and secondary of morphological defects in fresh semen were 42% and 52%, respectively. Ejaculates also contained high proportions of abnormal acrosome (51.7±22.5), bent mid-piece with droplet (32%) and tightly coiled tail (12%).

Table 1. Protocol for electro-ejaculation in each series of stimulation for Malayan tapir

	Series (1, 2, 3)					
	2	3	4	5	6	7
Voltage (V)	2	3	4	5	6	7
mA (miliamps)	130	130	150	200	220	250
No. of stimulations	3-5	3-5	3-5	10	10	10

Table 2. Testicular measurement in adult captive Malayan tapir

Measurement	Left testicle (n=4)	Right testicle (n=4)
Length (cm)	8.9±1.4 (7.5-11.2)	9.2±0.7 (8.2-9.9)
Width (cm)	4.4±0.5 (3.5-4.8)	5.0±0.1(5-5.2)
Height (cm)	4.4± 0.3 (4-4.9)	4.8±0.7 (4.5-5.1)
Volume (cm ³)	93.2± 25.6 (65.9-133)	118.2± 12.2 (106-139)

Values represent Mean±SD; value within parenthesis present minimum and maximum

Table 3 Ejaculate characteristic of captive Malayan tapir (n=8 males)

Parameter	Mean±SD	Range (n=14)
Age	10.6±6.8	4-20
Volume (ml)	10.3±9.4	7.9-33.9
Semen pH	7.7±3.4	7-8
Osmolarity (mOsm)	278.6±13.3	266.8-298.5
Sperm concentration (x10 ⁶ spermatozoa/ml)	206.1±185.4	60-520.6
Total sperm per ejaculate (x10 ⁶)	1624.8±241.0	52-4,150
Sperm motility (%)	24±15.4	0-40
Sperm progressive motility status (1-5)	2.0±0.2	1-3
Sperm viability (%)	35.1±6.5	28.2-42.6
Normal sperm morphology (%)	6.7±2.6	2.5-13
Primary defects (%)	42.7±22.5	24.7-61.7
Secondary defects (%)	52.3±28.1	42.3-71.1
Acrosome intact (%)	39.2±8.5	31.5-54

Values represent Mean±SD; value within parenthesis present minimum and maximum

Discussions

The present study is the first systematic report on 1) anesthesia of a large cohort of Malayan tapirs maintained in captivity in Thailand and 2) their ejaculate traits. We demonstrate that Malayan tapirs can be safely anesthetized using MBK and reversed without any adverse effects. We also demonstrate that similar to the Baird's tapir, spermic ejaculates can be consistently collected from male Malayan tapirs using electroejaculation (Pukazhenthil et al., 2011). Although the overall ejaculate quality was not optimal, the results provide fundamental information on the male reproductive biology, information crucial for development of assisted reproductive technologies for genetic management.

Knowledge and experience on Malayan tapir anesthesia are limited among zoo and wildlife veterinarians. However, there are significant needs in using safe anesthesia for medical procedures and disease surveillance in this species. During the past decade, anesthesia of Malayan tapir has been limited to medical procedures (Lambeth et al., 1998; Kaewamatawong et al., 2010) due to the risk associated with anesthesia and uniqueness of anatomy in this species (Janssen, 2003; Hernandez-Divers and Bailey, 2007). In this study, the anesthesia protocol was optimized for reproductive assessment

in males using MBK in a single dart. This combination was safely used for surgery in various species, e.g. pig (Sakaguchi et al., 1996), dog (Ko et al., 2000), Thomson's gazelle (Chittick et al., 2001), red wolf (Larsen et al., 2002) and binturong (Moresco and Larsen, 2003).

Intravenous supplementation of ketamine HCl and GG has previously been reported to yield satisfactory depth of anesthesia for surgical intervention in the domestic horse (Brock and Hilderbrand, 1990; Young et al., 1993) and ponies (Taylor et al., 1998). In addition, it has been used for semen collection in one-horned rhinoceros (Roth et al., 2005), black rhinoceros (Roth et al., 2005), Southern white rhinoceros (Roth et al., 2005), and Indian rhinoceros (Stoop et al., 2010). In the present study, 2/8 males (25%) showed a pronounced response to the electric stimuli during electroejaculation. Hence, a supplemental dose of ketamine HCl and/or GG infusion had to be administered intravenously. This resulted in an immediate control of the plane of anesthesia. Amongst the anesthetic drugs used in this study, medetomidine HCl was reported to improve the number of spermatozoa per ejaculate in domestic cat (Zambelli et al., 2007) but this effect was not observed in this study.

Table 4 Comparison of semen characteristic of endangered species obtained by electroejaculation

Characteristic	Malayan tapir ¹ (n=8) ^a	Baird's tapir ² (n=11) ^a	Przewalski horse ³ (n=14) ^a	Indian rhinoceros ⁴ (n=6) ^a	African Elephant ⁵ (n=5) ^a	Wild boar ⁶ (n=11) ^b
Volume (ml)	10.3±9.4	20.4±4.3	31.1±2.1	158.6±32.8	93.3±48.4	15.5±8.8
Sperm pH	7.7±3.4	7.4±0.1	9.2±0.0	8.74±0.0	7.8±0.1	ND
Osmolality(mOsm/kg)	278.6±13.3	284.7±14.5	299.7±2.7	308.0±4.7	ND	ND
Concentration(x10 ⁶ /ml)	206.1±185.4	101.2±24.0	2.69±0.2	10.11±3.5	2409±521	8.3±4.2
Sperm motility (%)	24±15.4	46.1±5.0	42.2±2.2	48.0±9.4	70.0±6.0	76.0±7.8
Sperm viability (%)	35.1±6.5	ND	ND	89.5±1.6	ND	84.0±10.0
Normal sperm (%)	6.7±2.6	6.9±1.4	19.1±2.7	38.8±7.79	77.5±0.0	85.6±6.6
Acrosome intact (%)	39.2±8.5	74.8±3.8	ND	85.5±1.9	ND	85.0±6.6

¹Current study; ²Pukazhenthil et al., 2011; ³Collin 2010; ⁴Stoops et al., 2010; ⁵Howard et al., 1984; ⁶Fischman et al., 2011
ND: Not determined, ^aValue represent Mean±SEM, ^bValue represent Mean±SD

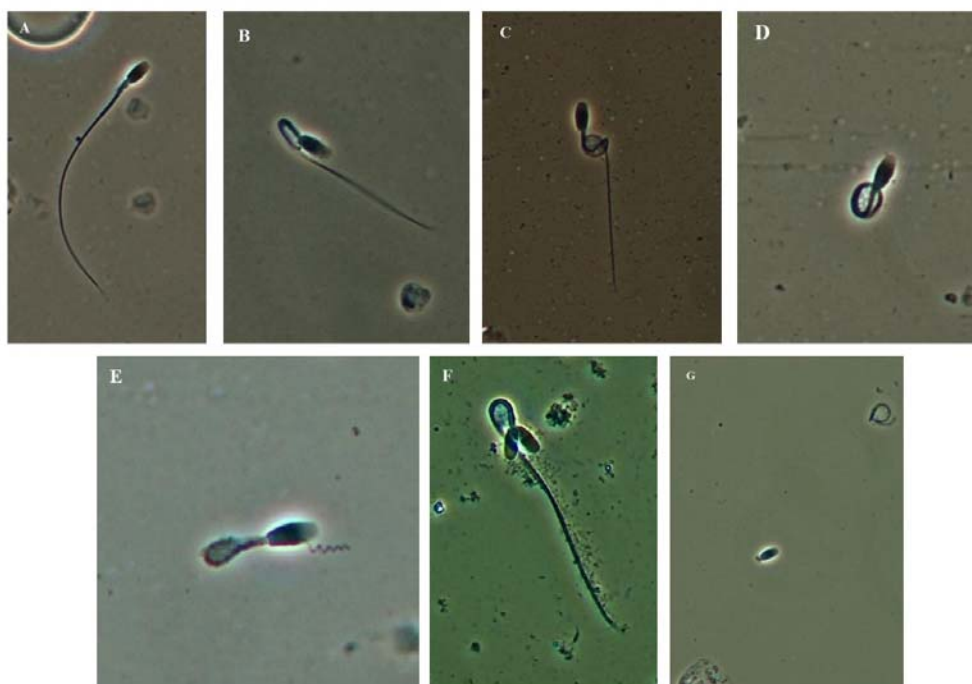


Figure 2 Photomicrographs of spermatozoa examined using a phase contrast microscope (1000x). A) Normal spermatozoa; B) bent midpiece with no cytoplasmic droplet; C) bent midpiece with cytoplasmic droplet; D) a tightly coiled tail; E) bent midpiece with retained cytoplasmic droplet and an abnormal flagellum; F) bicephalic; and G) detached head. (scale bar = 10 μ m).

There are a number of semen collection methods described for Perissodactyla such as manual semen collection in white rhinoceros (Walzer et al., 2000; Hermes et al., 2005), post coital semen collection in Sumatran rhinoceros (O'Brien and Roth, 2000) with limited success and requires intensive animal training (Hermes et al., 2005). Semen collection using an artificial vagina in tapirs has previously been reported, but no further information is available (Durrant, 1990). Electroejaculation is a safe alternative to obtain semen samples from a host of species including the Perissodactyls i.e. black rhinoceros (Roth et al., 2005), white rhinoceros (Roth et al., 2005), Indian rhinoceros (Stoop et al., 2010), Sumatra rhinoceros (Walzer et al., 2010) and Baird's tapir (Pukazhenthithi et al., 2011). In this study, the Malayan tapir semen was collected successfully using electroejaculation as previously described for the Baird's tapir (Pukazhenthithi et al., 2011).

In this study, the size and the tonicity of tapir testicles were normal and comparable with other species (i.e. Bovidae: Bailey et al., 1996; and carnivores: Howard, 1993). The ejaculates of captive Malayan tapirs in this study showed low motility with high variation (0-50%). In contrast, ejaculates with good sperm motility have been obtained from other wildlife species including the wild boar (Fischman et al., 2003), African elephant (Howard et al., 1984), rhinoceros (Roth et al., 2005; Hermes et al., 2005), Przewalski horse (Collin, 2006; 2010) and Baird's tapir (Pukazhenthithi et al., 2011). This discrepancy in sperm motility in the present study may be attributed to sperm structure, flagellar physiology, calcium signaling, protein

phosphorylation, nutritional deficiencies or inbreeding (Turner, 2006) and warrants further studies.

Non-physiological ejaculation might affect semen quality. Incomplete ejaculates especially in dog also have been reported to exhibit poor motility (Olson et al., 1987). Alkaline phosphatase has been used to differentiate between an incomplete and complete ejaculates in the dog (Olson et al., 1987; Kutzlera et al., 2003) and horse (Turner and McDonnell, 2003). Complete ejaculates routinely contain higher concentrations of alkaline phosphatase. However, in this present study, we did not evaluate alkaline phosphatase in Malayan tapir seminal plasma. Therefore, further studies on the value of alkaline phosphatase in differentiating between complete and incomplete ejaculate is crucial. From our previous studies in Asian elephant, we found that the urine contamination was a major cause of poor sperm motility and could be detected by measuring creatinine and blood urea nitrogen in seminal plasma (Siththawee Thongtipsiridech, unpublished data). In the present study, however, we did not measure either constituent. Interestingly, in this study, the semen pH was near neutral (7.7 ± 3.4) suggesting that the samples were not contaminated with urine.

The ultrastructural morphology analysis of sperm was one of the techniques that could predict sperm motility (Turner, 2006). However, ultrastructure of Malayan tapir sperm has not been analyzed in our study. It would be important to examine Malayan tapir sperm at the ultrastructural level to better understand the factors responsible for poor sperm motility.

The osmolality of Malayan tapir semen was similar to that of Baird's tapir (Pukazhenthii et al., 2008 and 2011), but lower than that of the Przewalski's horse (Collin, 2006; 2010) and rhinoceros semen (Roth et al., 2005; Hermes et al., 2005). The sperm concentration in tapir was higher than Przewalski horse (Collin, 2006; 2010) and Indian rhinoceros (Stoop et al., 2010) but lower than that of African elephant ejaculate (Howard et al., 1984).

The high proportion of morphologically abnormal spermatozoa has been reported in several Perissodactyla species (Roth et al., 2005; Collin, 2010; Stoop et al., 2010; Pukazhenthii et al., 2011). The Malayan tapir ejaculates from this study demonstrated consistently low numbers of morphologically normal spermatozoa (Table 2). The common abnormalities observed consisted of spermatozoa with an abnormal acrosome and/or a bent midpiece with a cytoplasmic droplet, and/or a tightly coiled flagellum, respectively (Fig 2). In general, acrosomal abnormalities arise from defects in spermatogenesis, while the occurrence of a high proportion of spermatozoa with a midpiece and/or cytoplasmic defects (droplets) indicates a defect of testicular origin. Therefore, additional studies are warranted to examine the etiology of the presence of high proportions of spermatozoa with an abnormal midpiece and/or flagellum.

Lack of gene diversity or increased inbreeding have been studied extensively in several species including cheetah (Raymond and O'Brien, 1993; O'Brien et al., 2009), Eld's deer (Wildt, 1992) and antelopes (Roldan et al., 2006). Teratospermia is highly prevalent in domestic and non-domestic felid species (Wildt et al., 1983; Pukazhenthii et al., 2006). Sperm abnormalities have been attributed to age, seasonality, stress, diseases and inbreeding status in several species e.g. bulls (Soderquist et al., 1996), stallions (Dowsett and Knott, 1996), goats (Karagiannidis et al., 2000), Eld's deer (Monfort et al., 1993), antelopes (Gomendio et al., 2000), and cheetahs (Wildt et al., 1983; Lindburg et al., 1993). The limited numbers of tapir founders in captivity increase inbreeding opportunity. The high proportion of abnormal spermatozoa and poor sperm motility in this study may have been influenced by inbreeding depression. Further molecular genetic analysis is recommended to assess genetic diversity in captive tapir population and can be use for breeding recommendations.

Although previous studies of female Malayan tapir endocrinology indicated that tapirs were not seasonal breeders (Brown et al., 1994; Kusuda et al., 2007), there is no information on the endocrinology of the male Malayan tapir. Therefore, further investigation on male Malayan tapir endocrinology might increase our understanding of the male tapir reproductive physiology and also could facilitate the development of assisted reproductive technologies in this species. In conclusion, the present study is the first systematic research conducted to describe semen characteristic of the endangered Malayan tapir and may facilitate further development

of sperm cryopreservation technologies both for the tapir and other species.

Acknowledgements

This study was supported by the Center for Agricultural Biotechnology and the Center of Excellence on Agricultural Biotechnology (AG-BIO/PERDO-CHE), Kasetsart University and was partially funded by the National Research Council of Thailand. We gratefully thank the zoo staffs, keepers, scientists and veterinarians of four zoos under the Zoological Park Organization (Khao Kheow Open Zoo, Chiang Mai Zoo, Nakhonratchasima Zoo and Songkhla Zoo) for their kind support in this study.

References

- Amann, R.P. 1989. Can the fertility potential of a seminal sample be predicted accurately?. J Androl. 10: 89-98.
- Bailey, T.L., Monke, D., Hudson, R.S., Wolfe, D.F., Carson, R.L. and Riddell, M.G. 1996. Testicular shape and its relationship to sperm production in mature Holstein Bulls. Theriogenology. 46: 881-887.
- Brock, N. and Hilderbrand, S.V. 1990. A comparison of xylazine-diazepam-ketamine and xylazine-guaifenesin-ketamine in equine anesthesia. Vet Surg. 19: 468-474.
- Brown, J. L., Citino, S.B., Shaw, J. and Miller, C. 1994. Endocrine profiles during the estrous cycle and pregnancy in the Baird's tapir (*Tapirus bairdii*). Zoo Biol. 13: 107-117.
- Brown, J.L., Göritz, F., Pratt-Hawkes, N., Hermes, R., Galloway, M., Graham, L.H., Gray, C., Walker, S.L., Gomez, A., Moreland, R., Murray, S., Schmitt, D.L., Howard, J., Lehnhardt, J., Beck, B., Bellem, A., Montali, R. and Hildebrandt, T.B. 2004. Successful artificial insemination of an Asian elephant at the National Zoological Park. Zoo Biol. 23: 45-63.
- Bush, M. 1996. A technique for endotracheal intubation of non-domestic bovids and cervids. J Zoo Wildl Med. 27(3): 378-381.
- Chittick, E., Horne, W., Wolfe, B., Sladky, K. and Loomis, M.J. 2001. Cardiopulmonary assessment of medetomidine, ketamine, and butorphanol anesthesia in captive Thomson's gazelles (*Gazella thomsoni*). J Zoo Wildl Med. 32(2): 168-175.
- Colenbrander, B., Puyk, H., Zandee, A.R., and Parlevliet, J.M. 1992. Evaluation of the stallion for breeding. Acta Vet Scand. 88: 29-38.
- Collins, C.W., Songsasen, N., Monfort, S.L., Bush, M. Wolfe, B., James, S.B., Wildt, D.E. and Pukazhenthii, B.S. 2006. Seminal traits of the Przewalski's horse (*Equus ferus przewalskii*) following electroejaculation. Anim Reprod Sci. 29: 46-49.
- Collin, C.W. 2010. Understanding the reproductive biology of the Przewalski's horse (*Equus ferus przewalskii*). PhD Thesis. The Faculty of the Graduate School of the University of Maryland. 154 pp. p 106.

- Dowsett, K.F. and Knott, L.M. 1996. The influence of age and breed on stallion sperm. *Theriogenology*. 46: 397-412.
- Durrant, B.S. 1990. Semen collection, evaluation, and cryopreservation in exotic animal species: Maximizing reproductive potential. *Ilar News*. 32(1): 2-10.
- Fischman, M.L., Suhevic, J., Rivolta, M.A. and Cisale, H.O. 2003. Collection of wild boar semen by electroejaculation. *Vet Rec*. 153: 365-366.
- Gomendio, M., Cassinello, J. and Roldan, E.R.S. 2000. A comparative study of ejaculate traits in three endangered ungulates with different levels of inbreeding: Fluctuating asymmetry as an indicator of reproductive and genetic stress. *Proc R Soc Lond B*. 267: 875-882.
- Haas, G.G.Jr., DeBault, L.E., D'Cruz, O. and Shuey, R. 1988. The effect of fixatives and/or air-drying on the plasma and acrosomal membranes of human sperm. *Fertil Steril*. 50(3): 487-492.
- Hermes, R., Hildebrandt, T.B., Blottnera, S., Walzerb, C., Silinskib, S., Pattonc M.L., Wibbelta, G., Schwarzenbergerd, F. and Göritz, F. 2005. Reproductive soundness of captive southern and northern white rhinoceroses (*Ceratotherium simum simum*, C.s. cottoni): evaluation of male genitaltract morphology and semen quality before and after cryopreservation. *Theriogenology*. 63: 219-238.
- Hernandez-Divers, S.M. and Bailey, J. 2007. Tapirs. In: *Zoo Animal & Wildlife Immobilization and Anesthesia*. G. West, D. Heard and N. Caulkett (eds), Oxford: Blackwell: 533-541.
- Howard, J.G., Wildt, D.E., Chakraborty, P.K. and Bush, M. 1983. Reproductive traits including seasonal observation on semen quality and serum hormone concentrations in the *Dorcus gazelle*. *Theriogenology*. 20: 221-229.
- Howard, J.G., Bush, M., de Vos, V. and Wildt, D.E. 1984. Electroejaculation, semen characteristics and serum testosterone concentration of free-ranging African elephants (*Loxodonta Africana*). *J Reprod Fertil*. 72: 187-195.
- Howard, J.G. 1993. Semen collection and analysis in canivores. In: *Zoo and Wildlife Medicine 3rd ed.* M.E. Fowler (ed), Philadelphia: WB Saunders: 390-398.
- Howard, J.G., Byers, A.P., Brown, J.L., Barrett, S.J., Evans, M.Z., Schwartz, R.J. and Wildt, D.E. 1996. Successful ovulation induction and laparoscopic intrauterine artificial insemination in the clouded leopard (*Neofelis nebulosa*). *Zoo Biol*. 15: 55-69.
- Howard, J.G. 2003. Black footed ferret: model for assisted reproductive technologies contributing to in situ conservation. In: *Reproductive Science and Integrated Conservation*. W. Holt, A.R. Pickard, J.C. Rodger and D.E. Wildt (eds), Cambridge: The University Press: 249-264.
- Janssen, D.L. 2003. Tapiridae. In: *Zoo and Wild Animal Medicine: Current Therapy*. 5th ed. M.E. Fowler and R.E. Miller (eds), Philadelphia: WB Saunders: 569-577.
- Kaewamatawong, T., Banlunara, W., Rungsipipat, A., Pirarat, N., Puranaveja, S. and Sommanustweechai, A. 2010. Disseminated tuberculosis in captive Malayan Tapir (*Tapirus indicus*). *Thai J Vet Med*. 40(4): 427-431.
- Karagiannidis, A., Varsakeli, S. and Karatzas, G. 2000. Characteristics and seasonal variation in the semen of Alpine Saanen and Damascus goat bucks born and raised in Greece. *Theriogenology*. 53: 1285-1293.
- Ko, J.C., Fox, S.M. and Mandsager, R.E. 2000. Sedative and cardiorespiratory effects of medetomidine, medetomidine-butorphanol, and medetomidine-ketamine in dogs. *J Am Vet Med Assoc*. 216(10): 1578-1583.
- Kuehn, G. 1978. Tapiridae. In: *Zoo and Wildlife Medicine*. M.E. Fowler (ed), Philadelphia: WB Saunders: 759-763.
- Kusuda, S., Ikoma, M., Morikaku, K., Koizumi, J., Kawaguchi, Y., Kobayashi, K., Matsui, K., Nakamura, A., Hashikawa, H., Ueda, M., Kaneko, M., Akikawa, T., Shibagaki, S. and Doi, O. 2007. Estrous cycle based on blood progesterone profiles and changes in vulvar appearance of Malayan tapirs (*Tapirus indicus*). *J Reprod Dev* 53(6): 1283-1289.
- Kutzlera, M.A., Solterb, P.F., Hoffmanb, W.E. and Volkmannc, D.H. 2003. Characterization and localization of alkaline phosphatase in canine seminal plasma and gonadal tissues. *Theriogenology*. 60: 299-306.
- Lambeth, R.R., Dart, A.J., Vogelnest, L., Dart, C.M. and Hodgson D.R. 1998. Surgical management of an abdominal abscess in a Malayan tapir. *Aust Vet J*. 76(10): 664-666.
- Larsen, R.S., Michael, R., Loomis, M.A., Kelly, B.T., Sladky, K.K., Stoskopf, M.K. and Horne, W.A. 2002. Cardiorespiratory effects of medetomidine-butorphanol, medetomidine-butorphanol-diazepam, and medetomidine-butophanol-ketamine in captive red wolves (*Canis rufus*). *J Zoo Wildl Med*. 33(2): 101-107.
- Lekagul, B. and McNeely, J.A. 1997. *Mammals of Thailand*. Bangkok: Kurusapa Ladprao Press: 648-650.
- Lindburg, D.G., Durrant, B.S., Millard, S.E. and Oosterhuis, J.E. 1993. Fertility assessment of cheetah males with poor quality semen. *Zoo Biol*. 12: 97-103.
- Lynam, A., Traeholt, C., Martyr, D., Holden, J., Kawanishi, K., Van Strien, N. J. and Novarino, W. 2008. *Tapirus indicus*. In: *IUCN 2011. IUCN Red List of Threatened Species*. Version 2011.1. [Online]. Available: <http://www.iucnredlist.org>
- Love, C.C. 1992. Semen collection techniques. *Vet Clin North Am Equine Pract*. 8: 111-128.
- Mace, G. M. and Balmford, A. 2000. Pattern and process in contemporary mammalian extinction. In *Priorities for the conservation of Mammalian Diversity*. A. Entwistle and N. Dunstone (eds), Cambridge: Univesity Press: 27-52.
- Monfort, S.L., Arthur, N.P. and Wildt, D.E. 1991. Monitoring ovarian function and pregnancy by evaluating excretion of urinary oestrogen conjugates in semi-free-ranging Przewalski's horses (*Equus przewalskii*). *J Reprod Fertil*. 91: 155-164.

- Monfort, S.L., Brown, J.L., Bush, M., Wood, T.C., Wemmer, C., Vargas, A., Williamson, L.R., Montali, R.J. and Wildt, D.E. 1993. Circannual inter-relationships among reproductive hormones, gross morphometry, behaviour, ejaculate characteristics and testicular histology in Eld's deer stags (*Cervus eldi thamin*). J Reprod Fertil. 98: 471-480.
- Moore, H.D.M., Bush, M., Celma, M., Garcia, A.L., Hartman, T.D., Hearn, J.P., Hodges, J.K., Knight, J.A., Monsalve, L. and Wildt, D.E. 1984. Artificial insemination in the Giant panda (*Ailuropoda melanoleuca*). J Zool. 203: 269-278.
- Moresco, A. and Larsen, R.S. 2003. Medetomidine-ketamine-butorphanol anesthetic combinations in binturongs (*Arctictis binturong*). J Zoo Wildl Med. 34(4): 346-351
- O'Brien, J.K. and Roth, T.L. 2000. Post-coital sperm recovery and cryopreservation in the Sumatran rhinoceros (*Dicerorhinus sumatrensis*) and application to gamete rescue in the African black rhinoceros (*Diceros bicornis*). J Reprod Fertil. 118: 263-271.
- O'Brien, J.K., Steinman, K.J. and Robeck, T.R. 2009. Application of sperm sorting and associated reproductive technology for wildlife management and conservation. Theriogenology. 71: 98-107.
- Olson, P.N., Behrendt, M.D., Amann, R.P., Weiss, D.E., Bowen, R.A., Nett, T.M. and McGarry, J.D. 1987. Concentrations of carnitine in the seminal fluid of normospermic, vasectomized, and castrated dogs. Am J Vet Res. 48(8): 1211-1215.
- OEPP (Office of Environmental Policy and Planning). 1997. Proceedings of the Conference on the Status of Biological Resources in Thailand, 29-30 May 1996. Ministry of Science, Technology and Environment, Bangkok. (in Thai).
- Prastiti, S. 2010. International studbook keeper of Malayan tapir (*Tapirus indicus*). Bogor. 1-34
- Pukazhenthii, B. and Wildt, D.E. 2004. Which reproductive technologies are most relevant to studying, managing and conserving wildlife?. Reprod Fertil Dev. 16: 33-46.
- Pukazhenthii, B., Neubauer, K., Jewgenow, K., Howard, J.G. and Wildt, D.E. 2006. The impact and potential etiology of teratospermia in the domestic cat and its wild relatives. Theriogenology. 66: 112-121.
- Pukazhenthii, B.S., Togna, G.D., Padilla, L.R., Pelican, K., Benedetti, A., Smith, D., Caballero, C.M., Hidalgo, C. and Sanjur, O. 2008. Seminal traits in the Baird's tapir (*Tapirus bairdii*) following electroejaculation. In: Proceeding of Fourth International Tapir Symposium. April 26-May 1, 2008. IUCN/SSC Tapir Specialist Group (TSG). 56.
- Pukazhenthii, B.S., Togna, G.D., Padilla, L., Smith, D., Sanchez, C., Pelican, K. and Sanjur, O.I. 2011. Ejaculate traits and sperm cryopreservation in the endangered Baird's tapir (*Tapirus bairdii*). J Androl. 32(3): 260-270
- Raymond, M.M. and O'Brien, S.J. 1993. Dating the genetic bottleneck of the African cheetah. PNAS. 90(8): 3172-3176.
- Roldan, E.R.S., Gomendio, M., Garde, J.J., Espeso, G., Ledda, S., Berlingver, F., Olmo, A., Soler, A.J., Arregui, L., Crespa, C. and González, R. 2006. Inbreeding and reproduction in endangered ungulates: preservation of genetic variation through the organization of genetic resource bank. Reprod Dom Anim. 4(2): 82-92.
- Roth, T.L., Stoops, M.A., Atkinson, M.W., Blumer, E.S., Campbell, M.K., Cameron, K.N., Citino, S.B. and Maas, A.K. 2005. Semen collection in rhinoceroses (*Rhinoceros unicornis*, *Diceros bicornis*, *Ceratotherium simum*) by electroejaculation with a uniquely designed probe. J Zoo Wildl Med. 36(4): 617-627.
- Sakaguchi, M., Nishimura, R., Sasaki, N., Ishiguro, T., Tamura, H. and Takeuchi, A. 1996. Anesthesia induced in pigs by use of a combination of medetomidine, butorphanol, and ketamine and its reversal by administration of atipamezole. Am J Vet Res. 57(4): 529-534.
- Soderquist, L., Janson, L., Haard, M. and Einarsson, S. 1996. Influence of season, age, breed and some other factors on the variation in sperm morphological abnormalities in Swedish dairy A.I. bulls. Anim Reprod Sci. 44: 91-98.
- Stoops, M.A., Atkinson, M.W., Blumer, E.S., Cambell, M.K. and Roth, T.L. 2010. Semen cryopreservation in the Indian rhinoceros (*Rhinoceros unicornis*). 73(8): 1104-1115.
- Summer, P.M., Shephard, A.M., Hodges, J. K., Kydd, J., Boyle, M. S. and Allen, W. R. 1987. Successful transfer of the embryos of Przewalski's horses (*Equus przewalskii*) and Grant's zebra (*E. burchelli*) to domestic mares (*E. caballus*). J Reprod Fertil. 80: 13-20.
- Taylor, P.M., Kirby, J.J., Shrimpton, D.J. and Johnson, C.B. 1998. Cardiovascular effects of surgical castration during anaesthesia maintained with halothane or infusion of detomidine, ketamine and guaifenesin in ponies. Equine Vet J. 30: 304-309.
- Thongtip, N., Mahasawangkul, S., Thitaram, C., Pongsopavijitr, P., Kornkaewrat, K., Pinyopummin, A., Angkawanish, T., Jansittiwate, S., Rungsri, R., Boonprasert, K., Wongkalasin, W., Homhong, P., Dejchaisri, S., Wajjawalku, W. and Saikhun, K. 2009. Successful artificial insemination in the Asian elephant (*Elephas maximus*) using chilled and frozen-thawed semen. Reprod Biol Endocrinol. 7: 75 [Online]. Available: <http://www.rbej.com/content/7/1/75>.
- Turner, R.M.O. and McDonnell, S.M. 2003. Alkaline phosphatase in stallion semen: Characterization and clinical applications. Theriogenology. 60: 1-10
- Turner, R.M. 2006. Moving to the beat: A review of mammalian sperm motility regulation. Reprod Fertil Dev. 18: 25-38.
- Walzer, C., Göritz, F., Pucher, H., Hermes, R., Hildebrandt, T.B. and Schwarzenberger, F. 2000. Chemical restraint and anesthesia in white rhinoceros (*Ceratotherium simum*) for reproductive evaluation, semen collection and artificial insemination. Proc Am Assoc Zoo Vet.

- 98-101.
- Walzer, C., Göritz, G., Hermes, R., Nathan, S., Kretzschmar, P and Hildebrandt, T. 2010. Immobilization and Intravenous Anesthesia in a Sumatran Rhinoceros (*Dicerorhinus sumatrensis*). J Zoo Wildl Med. 41(1): 115-120.
- Wildt, D.E., Bush, M., Howard, J.G., O'Brien, S.J., Meltzer, D., Van, D.A., Ebedes, H. and Brand, D.J. 1983. Unique seminal quality in the South African cheetah and a comparative evaluation in the domestic cat. Biol Reprod. 29: 1019-1025.
- Wildt, D.E. 1992. Genetic resource banks for conserving wildlife species: Justification examples and becoming organized on a global basis. Anim Reprod Sci. 28: 247-257.
- Wildt, D.E. 2009. Rescuing endangered animals with assisted reproductive technology. Sex Reprod Menopause. 7(2): 23-25.
- World Health Organization 2010. WHO laboratory manual for the examination of human semen. 5th ed. Geneva, Switzerland: WHO press: 26-27.
- Young, L.E., Bartram, D.H., Diamond, M.J., Gregg A.S. and Jones, R.S. 1993. Clinical evaluation of an infusion of xylazine, guaifenesin and ketamine for maintenance of anaesthesia in horses. Equine Vet J. 25: 115-119.
- Zahari, Z.Z., Abraham, M., Aisyah, S., Khairiah, M.S., Abraham, G. and MohdRauf, A.K. 2008. Notes on twinning in the Malayan Tapir (*Tapirus indicus*). In: Proceeding of 4th International Tapir Symposium. April 26-May 1, 2008. IUCN/SSC Tapir Specialist Group (TSG): 56.
- Zambelli, D., Cunto, M., Prati, F. and Merlo, B. 2007. Effects of ketamine or medetomidine administration on quality of electroejaculated sperm and on sperm flow in the domestic cat. Theriogenology. 68(5): 796-803.