

WHAT IS YOUR DIAGNOSIS

Pranee Tuntivanich Suwicha Chuthatep

Signalment

An 8-year-old castrated male Pomeranian

History

The dog had presented stranguria and hematuria during the past 2 weeks. After urinary catheterization could not be performed due to an obstruction at the peni urethral portion, cystocentesis was taken to release urinary bladder tension and urinary analysis was performed.

Clinical Examination

Complete blood count and blood chemistry profile were normal. Large amount of RBC and WBC was detected from urinary analysis. Presence of urethral calculi could not be determined.

Radiographic Examination

Plain right lateral and ventrodorsal views of abdominal radiographs were taken to evaluate the urinary tract abnormalities and positive contrast urethrography was performed to investigate the cause of urethral obstruction.

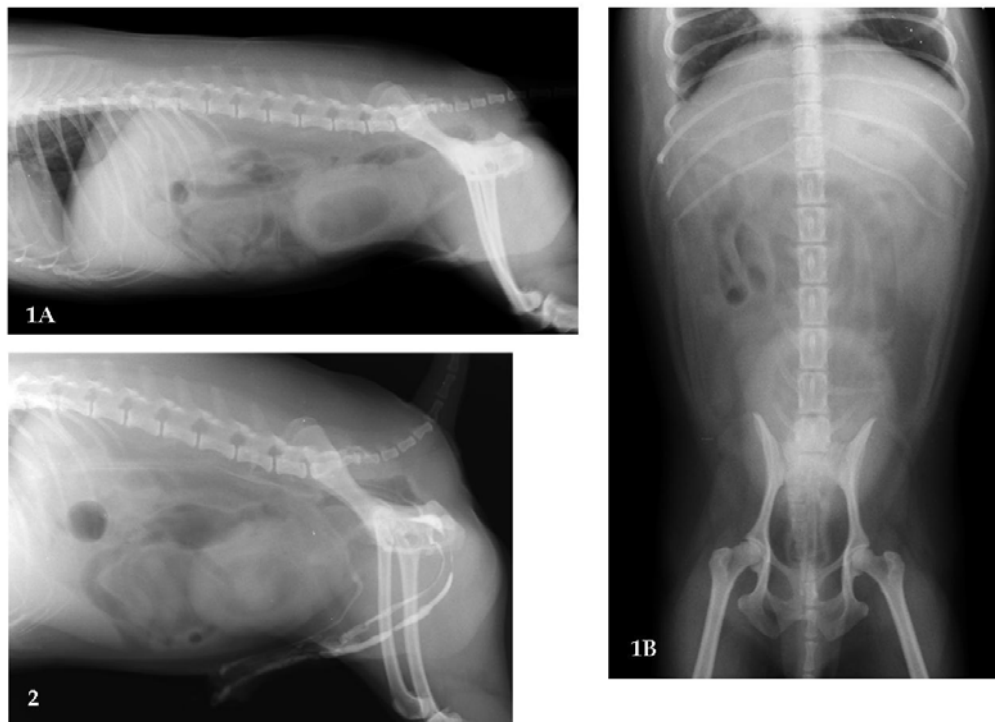

Figure 1A, B Right lateral and ventrodorsal abdominal radiographs

Figure 2 Positive contrast urethrogram

Give your diagnosis and turn to the next page.

Radiographic findings

The right lateral and ventrodorsal radiographs (Fig 1A, B) revealed cranial displacement of the dilated urinary bladder. Urinary bladder had an oval-shaped radiolucent area in the middle that may result from catheterization. No evidence of radiopaque urolith in both urethra and bladder could be detected. Positive contrast urethrogram (Fig 2) showed an extravasation of the contrast medium into periurethral area as double radiopaque lines along the membranous urethra. These two lines were then merged into one radiopaque line beneath caudal lumbar spines. Irregular urethral wall surface and dilation of the urethral lumen were also detected from the filling defect.

Radiographic diagnosis

Urethral laceration

Discussion

Contrast urethrography is a useful special radiographic technique to diagnose abnormalities of the urethra. Water soluble iodide contrast medium is commonly used. The oil based contrast medium, barium suspension and air should be avoided because of the risk of urethrocavernous reflux and contrast

medium embolism. In order to get a good radiograph, adequate contrast medium should be concerned. A 10-15 ml and 5-10 ml volume of contrast medium for large dog and small dog or cat are generally used. The lateral radiograph with the pelvic limbs pulled cranially is an important position to perceive a clear urethral lining. Abnormal radiographic signs of urethra from contrast study are the filling defects in the contrast medium column and extravasation of contrast medium from urethral lumen or both.

Extravasation of contrast medium (Fig 3) from retrograde urethrography indicates laceration or rupture of the urethral wall. In traumatic cases inducing pelvic fractures; contrast medium can pass into peritoneal cavity if there is a urethral tear close to urinary bladder neck. In cases of os penis fracture inducing urethral tear, post urethral surgery or poor catheterization technique can cause urethral laceration; contrast medium may enter the systemic venous circulation (Fig 3) if there is urethrocavernous reflux of the contrast medium.

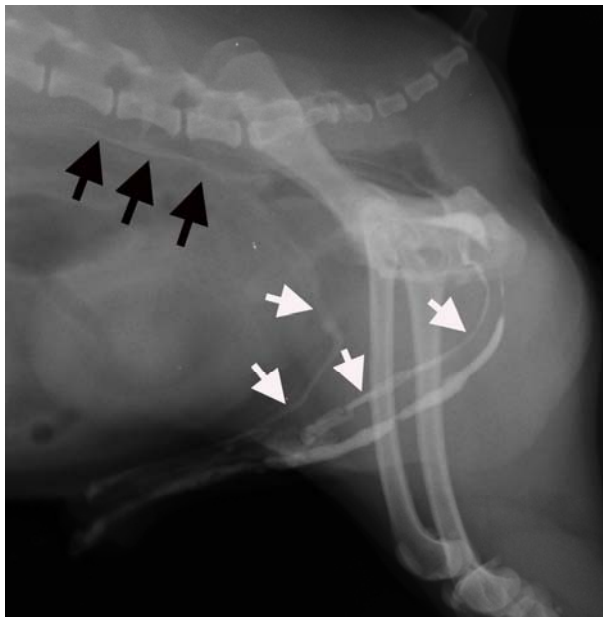


Figure 3 Close-up positive contrast urethrogram reveal an extravasation of contrast medium through urethral laceration area into the cavernous tissue of the penis (white arrows). The drainage of contrast medium into the caudal vena cava (black arrows) could be visualized at the sublumbar area.

References

- Pechman, R.D. 2002. The Urethra. In: Textbook of Veterinary Diagnostic Radiology. 4th ed. D.E. Thrall (ed.). Pennsylvania: W.B. Saunders Company. 588-592.