

# Retrospective Histopathological Study of Hemorrhagic Lesion of Coumarin Intoxication in Dogs

Theerayuth Kaewamatawong<sup>1\*</sup> Acharawan Lohavanijaya<sup>3</sup>

Piyawan Charoenlertkul<sup>2</sup> Supatra Srichairat<sup>2</sup>

## *Abstract*

Anticoagulant rodenticide, especially coumarin derivative, is the most common cause of companion animal intoxication. Retrospective pathological examination was performed on 10 dogs suspected to be intoxicated with anticoagulant rodenticides. Coumarin derivatives, cause of intoxication, were confirmed by toxicological identification using thin layer chromatography technique and spectral analysis. Macroscopically and microscopically, all cases showed generalized hemorrhages in various organs. Microscopic examination of hemorrhagic scores of liver, kidneys, intestines, heart, and lungs were  $2.28 \pm 1.94$ ,  $2 \pm 2$ ,  $1 \pm 1.63$ ,  $0.8 \pm 1.68$ , and  $1.1 \pm 2.32$ , respectively. Highest hemorrhagic score of the liver indicated that it suffered the most hemorrhagic effects related to anticoagulant rodenticides. The important factors might be high blood supply, function of metabolism and vitamin K1 dependent coagulation factor producing of the liver. Kidney also had high hemorrhagic score due to its high blood supply and function of elimination. In summary, this retrospective study revealed pathological findings of hemorrhagic lesions in dogs with coumarin intoxication. The histological assessment of hemorrhagic lesion in this study was evaluated and score in systematic way.

---

**Keywords:** coumarin, dog, hemorrhagic lesion, intoxication, retrospective

---

<sup>1</sup> Department of Veterinary Pathology, Faculty of Veterinary Science, Chulalongkorn University, Bangkok, 10330 Thailand

<sup>2</sup> Department of Veterinary Pharmacology, Faculty of Veterinary Science, Chulalongkorn University, Bangkok, 10330 Thailand

<sup>3</sup> Department of Veterinary Pharmacology, Faculty of Veterinary Medicine, Mahanakorn University of Technology, Nong Chok, Bangkok 10530 Thailand

\*Corresponding author E-mail: [theerayuth71@hotmail.com](mailto:theerayuth71@hotmail.com)

## บทคัดย่อ

### การศึกษาย้อนหลังทางจุลพยาธิวิทยาของรอยโรคเลือดออกของสุนัขที่ได้รับยาเบื่อหนูชนิดอนุพันธ์คูมาริน

ธีระยุทธ แก้วอมตวงศ์<sup>1\*</sup> อัจฉราวรรณ โลหะวนิชย์<sup>3</sup> ปิยะวรรณ เจริญเลิศกุล<sup>2</sup> สุพัตรา ศรีไชยรัตน์<sup>2</sup>

ยาเบื่อหนูชนิดกั้นการแข็งตัวของเลือดโดยเฉพาะอย่างยิ่งชนิดอนุพันธ์คูมารินเป็นสาเหตุของความเป็นพิษที่พบมากที่สุดชนิดหนึ่งในสัตว์เลี้ยง การศึกษาครั้งนี้เป็นการศึกษาย้อนหลังทางจุลพยาธิวิทยาของสุนัขที่ตายจากการได้รับยาเบื่อหนูชนิดอนุพันธ์คูมารินซึ่งได้รับตรวจหาและยืนยันด้วยวิธี thin layer chromatography technique และ spectral analysis จำนวน 10 ตัวอย่าง จากผลทางจุลพยาธิวิทยาพบการเกิดเลือดออกตามอวัยวะสำคัญต่างๆโดยมีความรุนแรงของรอยโรคที่แตกต่างกัน โดยได้ทำการให้คะแนนความรุนแรงของรอยโรคของอวัยวะต่างๆตามหลักเกณฑ์อย่างเป็นระบบ อวัยวะที่พบจุดเลือดออกมากที่สุดคือตับ รองลงมาคือ ไต ลำไส้ หัวใจ และปอด โดยมีคะแนนความรุนแรงของการเกิดเลือดออกในตับ ไต ลำไส้ หัวใจ และปอดดังนี้ 2.28±1.94, 2±2, 1±1.63, 0.8±1.68 และ 1.1±2.32 ตามลำดับ ตับเป็นอวัยวะที่เกิดระดับความรุนแรงของรอยโรคมากที่สุด การศึกษาครั้งนี้เป็นการศึกษาทางพยาธิวิทยาของรอยโรคจุดเลือดออกในสุนัขที่ได้รับยาเบื่อหนูซึ่งได้รับการยืนยันว่าเป็นชนิดอนุพันธ์คูมารินในอวัยวะต่างๆ โดยในการศึกษาทางจุลพยาธิวิทยาได้ประยุกต์การให้คะแนนความรุนแรงของรอยโรคเลือดออกในแต่ละอวัยวะอย่างเป็นระบบ

**คำสำคัญ:** ยาเบื่อหนูชนิดอนุพันธ์คูมาริน สุนัข เลือดออก ความเป็นพิษ ศึกษาย้อนหลัง

<sup>1</sup> ภาควิชาพยาธิวิทยา <sup>2</sup> ภาควิชาเภสัชวิทยา คณะสัตวแพทยศาสตร์ จุฬาลงกรณ์มหาวิทยาลัย ปทุมวัน กรุงเทพฯ 10330

<sup>3</sup> ภาควิชาเภสัชวิทยา คณะสัตวแพทยศาสตร์ มหาวิทยาลัยเทคโนโลยีมหานคร หนองจอก กรุงเทพฯ

\*ผู้รับผิดชอบบทความ E-mail: theerayuth71@hotmail.com

## Introduction

Anticoagulant rodenticides are the most widely used to kill rodents and pests because of their effective, easy to use and commonly available in the market (Eason et al., 2002; Valchev et al., 2008). Binev et al. (2005) reported that 95% of rodenticide bait used in households was anticoagulant rodenticides. Domestic dogs and cats are also at great risk from exposure to the anticoagulant rodenticides through direct ingestion of bait or ingestion of poisoned rodents (Waddell and Poppenga, 2004). On the other hand, the indirect ingestion of anticoagulant drugs for human patients with thrombotic disorders is a rare route to intoxication.

Coumarin derivatives are the most widely used among various types of anticoagulant rodenticides (Wang and Board, 2007). Coumarin anticoagulant rodenticides are divided into two groups of hydroxycoumarin and indandione according to chemical structure. Types of coumarin derivatives that are commonly used and readily accessible over the counter include coumatetralyl, warfarin, flocoumafen, difethialone, difenacoum and bromadiolone.

Interfering in the function of vitamin K1 epoxide reductase by action of coumarin leads to lack of active vitamin K1 resulting in depletion of clotting factors 2, 7, 9 and 10 (Harrell, 2003; Murphy, 2007). Animals suffering from coumarin intoxication always show signs of generalized bleeding such as subcutaneous hemorrhage, hemoptysis, hematuria, hematochesia etc. (Kohn et al., 2003; Means, 2003; Murphy, 2007). Several macroscopic studies reported hemorrhage lesions in various organs including skin, mucus membrane, lung, liver, kidney and uterus (Padgett et al., 1998; Radi and Thompson, 2004). Palmer et al. (1996) also reported pulmonary bleeding in human who had received coumarin derivative. Histopathological examination of hemorrhage in thymus was also reported (Liggett et al., 2002). However, there have not been any studies that reveal the details of histopathology of the hemorrhagic lesion that occur from intoxication in a systematic way in dogs. Therefore, the purpose of this study is to examine histopathological lesions of the severity, location and pattern of hemorrhages in various organs that are related to coumarin intoxication in dogs. Severity scores of hemorrhagic lesions were modified and established in a systematic way to serve as the basic principle for classifying the following lesions.

**Table 1** Criteria and scoring systems of hemorrhagic lesions in various organs

Heart <sup>1</sup>		Liver and kidneys <sup>1</sup>	
Score	Criteria of hemorrhage	Score	Criteria of hemorrhage
0	Absent	0	Absent
1	Focus in one layer of heart	1	1-2 foci with diameter of focus around 100 µm or more
2	Multifocal to diffuse foci in one layer of heart	2	3-4 foci with diameter of focus around 100 µm or more
3	Multifocal to diffuse foci in two layer of heart	3	5-6 foci with diameter of focus around 100 µm or more
4	Multifocal to diffuse foci in all three layer of heart	4	≥ 7 foci with diameter of focus around 100 µm or more
Intestines <sup>1</sup>		Lungs <sup>2</sup>	
Score	Criteria of hemorrhage	Score	Criteria of hemorrhage
0	Absent	0	1-25 RBC/alveoli
1	Focus in one layer of intestine	1	26-50 RBC/alveoli
2	Multifocal to diffuse foci in two layer of intestine	2	1-3 alveoli with > 50 RBC
3	Multifocal to diffuse foci in three layers of intestine	3	4-6 alveoli with > 50 RBC
4	Mucosal hematomas and intraluminal blood clots	4	7-9 alveoli with > 50 RBC
		5	10 alveoli with > 50 RBC

<sup>1</sup> The scoring system was modified from Schmidt et al. (1991)<sup>2</sup> The scoring system was modified from Broccard et al. 1998

### Materials and Methods

**Animal cases:** 10 cases of dogs died from suspected anticoagulant rodenticide intoxication were necropsied at Department of Veterinary Pathology, Faculty of Veterinary Science, Chulalongkorn University. Routine pathological investigation was performed. For history taking, common signs prior to death of all cases were loss of appetite and died suddenly. Vomiting and polypnea were also seen in some dogs. Hemorrhage and hematoma at various sites of skin were observed varying in degree of severity.

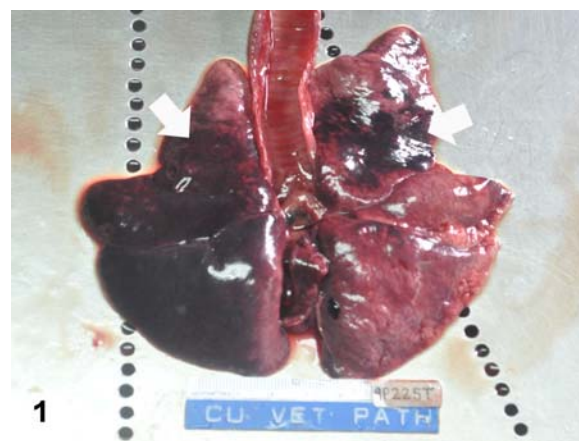
To confirm and identify the type of anticoagulant rodenticide using the thin layer chromatography (TLC) technique and the spectral analysis by derivative spectrophotometry, stomach content and livers were submitted to Toxicology unit, Department of Pharmacology, Faculty of Veterinary Science, Chulalongkorn University. Briefly, tissue samples were extracted with chloroform in vapor condition and homogenized with a tissue disperser. The extracts were filtered and the residual material was re-extracted and filtered again. The residue was reconstituted in 1 ml chloroform. TLC separation was performed using silica gel G plates as the stationary phase and methyl ethyl ketone : benzene (6:120, by vol) as the mobile phase. Standard solutions and control extracts of liver and ingesta were also prepared. The Quantification was performed by spiking extracts of liver with anticoagulant standards, running them under the standard TLC protocol. For spot detection of coumarin derivatives, a sodium hydroxide (H<sub>2</sub>O<sub>2</sub>) solution was overspray on plates and then a FeCl<sub>3</sub> solution was spray. The type of anticoagulant rodenticide analyzed by TLC technique and the spectral analysis was coumarin derivative of all cases examined.

### Histopathological evaluation and scoring system:

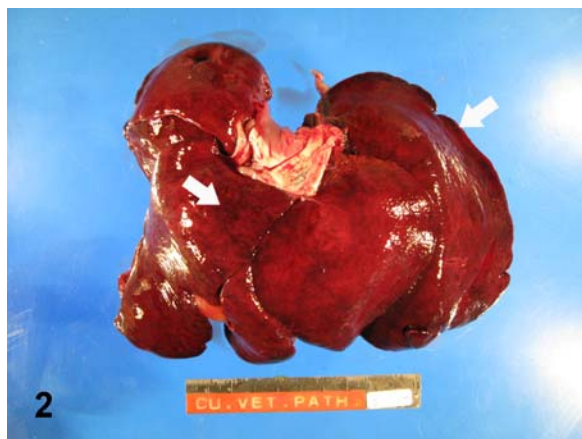Tissue samples approximately 1x1 cm<sup>2</sup> in size that showed hemorrhagic lesions in affected organs including liver, kidney, heart, lung and intestine were collected and fixed in 10% buffered formalin for routine histopathological processes and evaluations. The criteria and scoring systems of hemorrhagic lesion are shown in Table 1. Blind evaluation method was used to evaluate and score the lesions in each slide by two veterinary pathologists following the blind method for studying groups and sample areas. Three areas of each section were observed randomly using light microscope.

### Results and Discussion

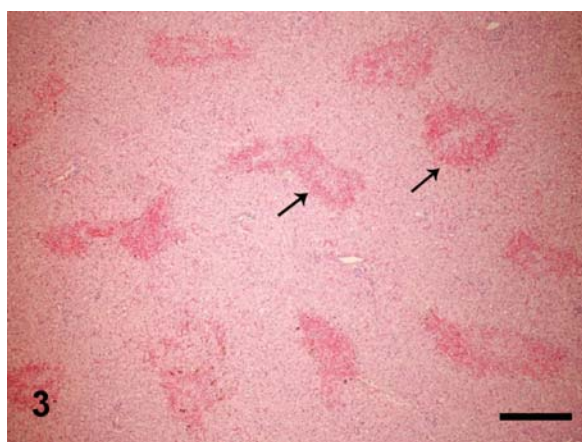
Generalized hemorrhages in various organs are the main lesions of this retrospective study. Macroscopic findings of all cases revealed generalized hemorrhages in various internal organs including lung (Fig 1), heart (Fig 2), liver, kidney and intestine. Microscopically, diffuse pattern of hemorrhages were found throughout the liver, especially centrilobular



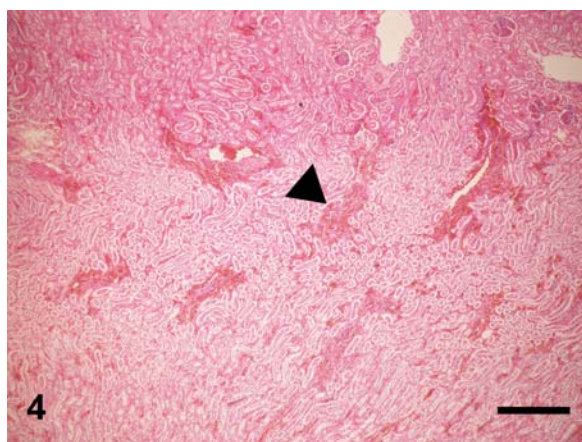
**Figure 1** Multifocal patchy hemorrhages (white arrows) in lung, dog



**Figure 2** Multifocal patchy hemorrhages (white arrows) in liver, dog

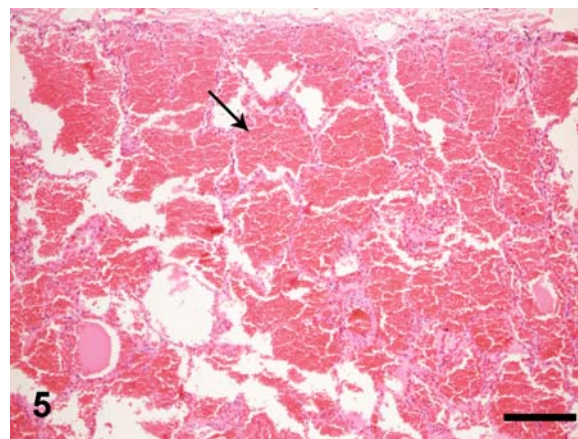


**Figure 3** Multifocal hemorrhagic lesions (arrows) were found throughout the liver; score of 4 (H&E, bar = 300  $\mu$ m).

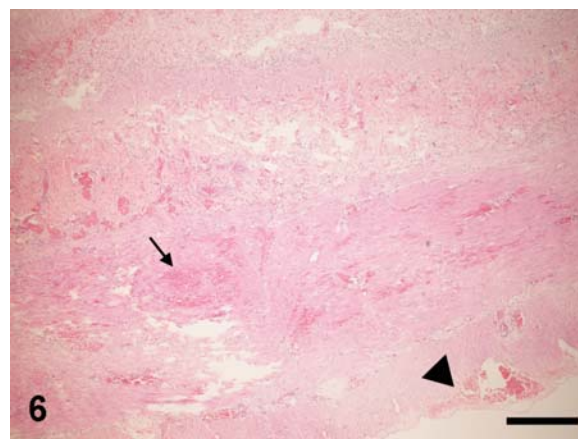


**Figure 4** Multifocal hemorrhages (arrow head) were observed in the medullar part of kidney ; score of 4 (H&E, bar = 300  $\mu$ m).

areas (Fig 3). The kidney showed a diffuse distribution of hemorrhages in which it is frequently found at cortico-medullary junction and medullar part (Fig 4). Multifocal to diffuse hemorrhagic lesions were observed in lungs (Fig 5) with some areas of edema and emphysema. Multifocal hemorrhages were found in submucosa, muscular layer or serosa of small intestines (Fig 5). Large multifocal hemorrhages were seen in endocardium, myocardium or



**Figure 5** Multifocal hemorrhages were found in alveoli of lung. Arrow presents focal hemorrhage that contain RBC more than 50 cells in one alveolus; score of 5 (H&E, bar = 250  $\mu$ m).



**Figure 6** Multifocal hemorrhages were found in the muscular (arrow) and serosal (arrow head) layers of small intestine; score of 2 (H&E, bar = 300  $\mu$ m).

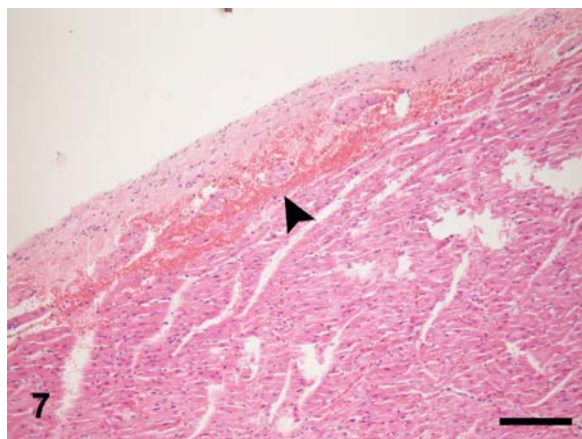
epicardium (Fig 6). Some cases showed hemorrhagic lesions involving 2 or 3 cardiac layers of the hearts. The severity of hemorrhagic lesion scored following criteria and scoring system is presented in table 2. Organ that had the highest hemorrhagic score in this retrospective study was the liver. Liver is a key organ in the elimination and metabolism of toxic substances, which is supported by a lot of blood supply. Moreover, vitamin K1 dependent coagulation factors, target points of anticoagulant rodenticide toxic mechanism, are also produced in liver.

**Table 2** The score of severity of hemorrhagic lesions in various organs

Organ	Severity of hemorrhage
Liver	2.28 $\pm$ 1.94
Kidney	2 $\pm$ 2
Intestine	1 $\pm$ 1.63
Heart	0.8 $\pm$ 1.68
Lung	1.1 $\pm$ 1.69

\*All data are expressed as means $\pm$ SD (n=10).





**Figure 7** Multifocal hemorrhages (arrow head) were seen in the epicardium of the heart; score of 2 (H&E, bar = 350  $\mu$ m).

Coumarin derivative is absorbed into the blood circulation and rapidly spread and accumulate mainly the liver (Murphy, 2002). Interfering in the function of vitamin K1 epoxide reductase and vitamin K1 reductase enzymes, which plays an important role in changing an inactive form of vitamin K1 to an active form, leads to a disruption to the synthesis of clotting factors factor II (prothrombin), factor VII (proconvertin), factor IX (christmas factor) and factor X (stuart-prower factor). The lack of the following clotting factors results in generalized coagulopathy and hemorrhage. Because the half-lives of the clotting factor II, VII, IX and X are 41, 6.2, 13.9 and 16.5 hours, respectively (Merola, 2002; Murphy and Talcott, 2006), the onset of clinical signs will develop within 3-5 days after exposure. However, the duration of onset and severity of clinical signs depend on the type of rodenticides and the exposure dose consumed (Murphy and Talcott, 2006; Murphy, 2007). Diffuse pattern of hemorrhages was found throughout the liver, especially in the area around the central vein or centrilobular areas, which are often firstly affected by the toxicant. The kidney also showed the diffuse distribution of hemorrhage. The lesions were frequently found at cortico-medullary junction and medullar part of kidney. Kidney also has a very rich blood supply and plays an important role in eliminating and biotransforming of toxicants. Other organs in which hemorrhage is found included heart, lung, intestine, thymus, adrenal gland and pancreas. All of these affected organs also have a very rich blood supply. The pattern of hemorrhagic lesions of each organ depends on anatomical structure and location of blood vessels that support the organs.

The difference of severity of hemorrhagic lesion in coumarin intoxication cases might be related to the type of anticoagulant rodenticides and the exposure dose (Kohn et al., 2003). To study the relation between the severity of hemorrhagic lesions and exposure dose of anticoagulant rodenticide, we need a methodical histologic evaluation correlated to a specific and sensitive method to detect the specific type and amount of rodenticide in each affected organs. To our knowledge there have not been any histopathological studies that evaluates the severity of hemorrhage lesion caused by coumarin intoxication.

This study modified a model for evaluating and scoring the severity of the hemorrhagic lesions in the systematic way (Broccard et al., 1998; Schmidt et al., 1991). However, the preliminary score system in this study must still be developed and tested for the sensitivity and specificity. The particular criteria for hemorrhage in each organ and the suitable collection of the tissue samples should be considered. The good model of scoring system for hemorrhage in affected organs may be used to correlate with the exposure dose of the rodenticides for a clearer study of pathogenesis and therapeutic management.

Other demerits of our study were the method to identify the type and measure the quantity of the rodenticides. In this retrospective study, thin layer chromatography technique (TLC) was the method used as the screening test to detect the coumarin derivative. Limitations of TLC technique included its inability to identify the specific type and measure the amount of coumarin derivative in each affected organ. Therefore, higher specific and sensitive methods such as High performance liquid chromatography (HPLC) will be a more suitable method to identify the specific type and quantity of the toxic substance intake.

In summary, this retrospective study tried to study the severity and pattern of hemorrhagic lesions that are related to coumarin intoxication in dogs. We modified a criteria and scoring system for evaluation of hemorrhagic lesions in various organs in animals that might be useful not just only for the anticoagulant rodenticide toxicity study, but also for other conditions or diseases that can produce generalized hemorrhage. To study the correlation between severity of hemorrhagic lesion and type with exposure dose of anticoagulant rodenticide, further quantitative determination method such as HPLC should be performed in affected organs for the benefit of diagnosis and treatment of intoxicated animals.

### Acknowledgements

This study was funded by grants from the Mexican Council of Science and Technology (CONACyT), project SAGARPA-CONACyT-2003-002-227). We thank Laboratorio de Biotecnología 1, Fac. de Ciencias Químicas, Universidad Autonoma de Chihuahua (Dr. G. Erosa de la Vega) for supplying the positive control and the laboratory facilities for this work.

### References

- Binev, R., Petko, P. and Rusenov, A. 2005. Intoxication with anticoagulant rodenticides bromadiolone in a dog—a case report. *Vet Archiv.* 75(3): 273-282.
- Broccard, A.F., Hotchkiss, J.R., Kuwayama, N., Olson, D.A., Jamal, S., Wangenstein, D.O. and Maini, J.J. 1998. Consequences of vascular flow on lung injury induced by mechanical ventilation. *Am J Respir Crit Care Med.* 157: 1935-1942.
- Eason, C.T., Murphy, E.C., Wright, G.R.G. and Spurr,

- E.B. 2002. Assessment of risks of brodifacoum to non-target birds and mammals in New Zealand. *Ecotoxicology (NZL Ecol)*. 11: 35-48.
- Harrell, T.W., Latimer, K.S., Batin, P.J. and Krimer, P.M. 2003. "Anticoagulant rodenticide Toxicosis in the dog and cat" [Online]. Available: <http://www.vet.uga.edu/VPP/clerk/Harrell/index.php>. Accessed Feb. 10, 2011
- Kohn, B., Weingart, C. and Gifer, U. 2003. Haemorrhage in seven cats with suspected anticoagulant rodenticide intoxication. *J Feline Med Surg*. 5: 295-304.
- Liggett, A.D., Thompson, J., Frazier, K.S., Styer, E.L. and Sangster, L.T. 2002. Thymic hematoma in juvenile dogs associated with anticoagulant rodenticide toxicosis. *J Vet Diagn Invest* 14: 416-419
- Means, C. 2003. Anticoagulant rodenticides. In: *Clinical Veterinary Toxicology*. K.H. Plumlee (ed.) St. Louis: Mosby: 444-446.
- Merola, V. 2002. Anticoagulant rodenticides: Deadly for pets, dangerous for pets. *Vet Med*. 97: 716-722.
- Murphy, M.J. 2002. Rodenticides. *Vet Clin Small Anim* 32: 469-484.
- Murphy, M.J. 2007. Anticoagulant rodenticide. In: *Veterinary Toxicology Basic and Clinical Principles*. R.C. Gupta (ed.) Amsterdam: Elsevier. 527-547, 1077-1082, 1156.
- Padgett, S.L., Stokes, J.E., Tucker, R.L. and Wheaton, L.G. 1998. Hematometra secondary to anticoagulant rodenticide toxicity. *J Am Anim Hosp Assoc*. 34(5): 437-439.
- Palmer, R.B. Alakija, P., de Beca, J.E. and Nolte, K.B. 1999. Fetal brodifacoum rodenticide poisoning: autopsy and toxicologic findings. *J Forensic Sci*. 44: 851-855.
- Radi, Z.A. and Thompson, L.J. 2004. Renal subcapsular hematoma associated with brodifacoum toxicosis in a dog. *Vet Hum Toxicol*. 46: 83-84.
- Schmidt, J., Rattner, D.W., Lewandrowski, K., Compton, C.C., Mandavilli, U., Knoefel, W.T. and Warshaw, A.L. 1991. A better model of acute pancreatitis for evaluating therapy. *Ann Surg*. 215: 44-56.
- Valchev, I, Binev, R., Yordaniva, V. and Nikolov, Y. 2008. Anticoagulant rodenticides intoxication in animals -A review. *Turk J Anim Sci*. 32(4): 237-243.
- Waddell, R. and Poppenga, L.S. 2004. Respiratory toxicology. In: *Textbook of Respiratory Disease in Dogs and Cats*. L.G. King (ed.) St. Louis: Saunders. 562-566.
- Wang, Y., Kruzik, P., Helsberg, A., Helsberg, I. and Rausch, W.D. 2007. Pesticide poisoning in domestic animals and livestock in Australia: 6 years retrospective study. *Forensic Sci Int*. 169: 157-160.