

ECG Quiz

Chollada Buranakarl^{1*} Saikaew Sutayatram¹

History

A 12-year-old castrated male pomeranian with 3.5 kilogram body weight, was referred to the Small Animal Teaching Hospital, Chulalongkorn University, on May 2017. The dog had been diagnosed for diabetic mellitus since November 2016 and treated with insulin and prescription diet ever since. Two days ago, the dog were anorexia while the owner continued the insulin injection. Dog was reported of hyperthermia (104 F), mild anemia, severe thrombocytopenia, mild azotemia (blood urea nitrogen or BUN 54 mg% and creatinine or Cr. 1.81 mg%), slightly elevated liver enzyme, mild hypoalbuminemia, hyperglycemia (blood glucose 468 mg%), and mild metabolic acidosis. The dog received medication prior to referring.

From physical examination, the dog was depressed, vomited with anuria. Although normal hydration status, blood profiled indicated metabolic acidosis, hyperglycemia (blood glucose 379 mg%), moderate anemia, mild leukocytosis, slightly elevated liver enzyme, mild hypoalbuminemia, mild hyperkalemia, hyperphosphatemia, and moderate azotemia, with positive for *Ehrlichia canis* from blood smear and *Anaplasma canis* from snap 4Dx test. Urinalysis from strip test showed proteinuria, glucosuria, hematuria, bilirubinuria, and leukocyturia. The dog received mannitol, antibiotics, supportive fluid and other symptomatic treatment as necessary.

Radiographic finding were left renomegaly, hepatomegaly, aging lung appearances, and severe hip degenerative joint disease. The ultrasonography confirmed left hydronephrosis or pyelonephrosis secondary from sand calculi and debris obstruction at proximal ureter, with right renal mineralization but normal shape and size, severe distension of urinary bladder, and focal splenic tail infraction with necrosis.

After six days of being admitted in the hospital, the dog was stable and underwent left nephrectomy and total splenectomy. The post operative treatments were performed in intensive care unit.

Second day after surgery, limb lead electrocardiography (ECG) was performed (picture 1A and 1B). Additional examination by echocardiography revealed moderate to severe mitral regurgitation and mild left atrial enlargement with normal systolic function. Positive inotrope, pimobendan, was prescribed. The antiarrhythmic drug, lidocaine was given periodically during sustained ventricular ectopy.

Three days after surgery, the diuretic, furosemide, was added while severe metabolic acidosis was maintained. Continuing monitoring and treatment were done with dog improvement. Six days post-surgery, the limb lead ECG was recorded (Figure 1C) with progressive improvement.

¹Department of Veterinary Physiology, Faculty of Veterinary Science, Chulalongkorn University

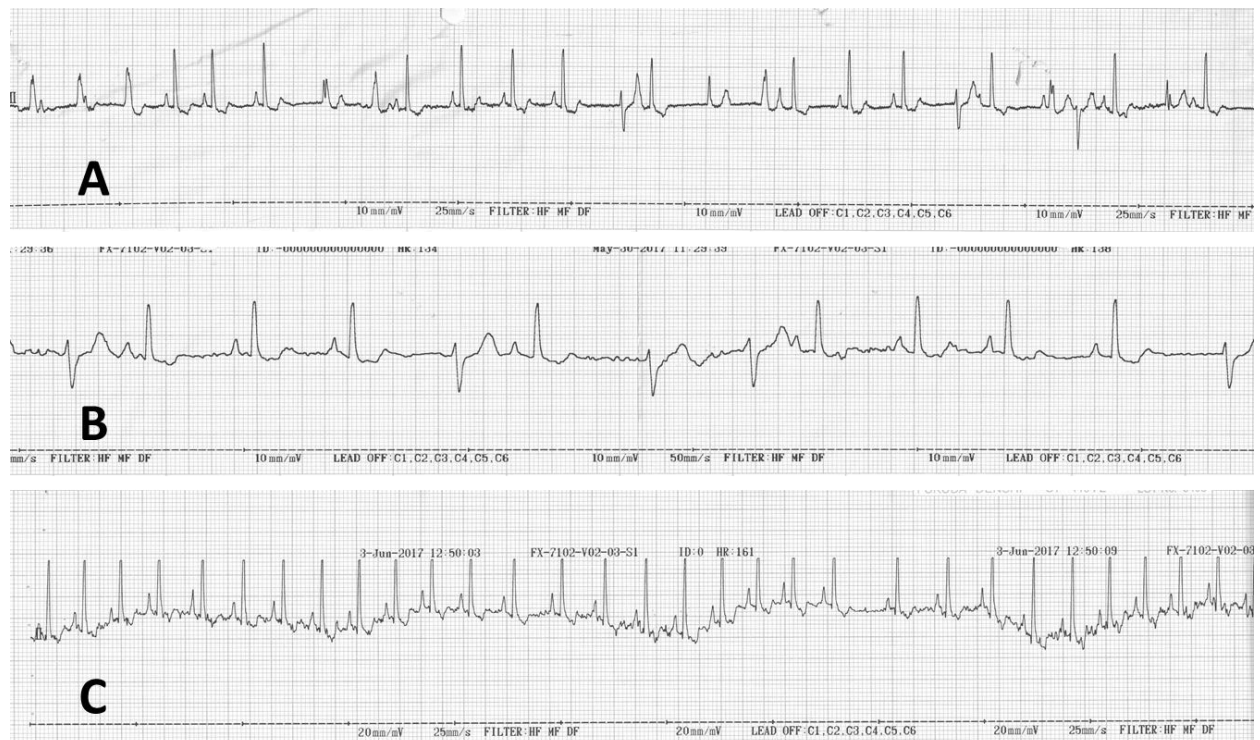
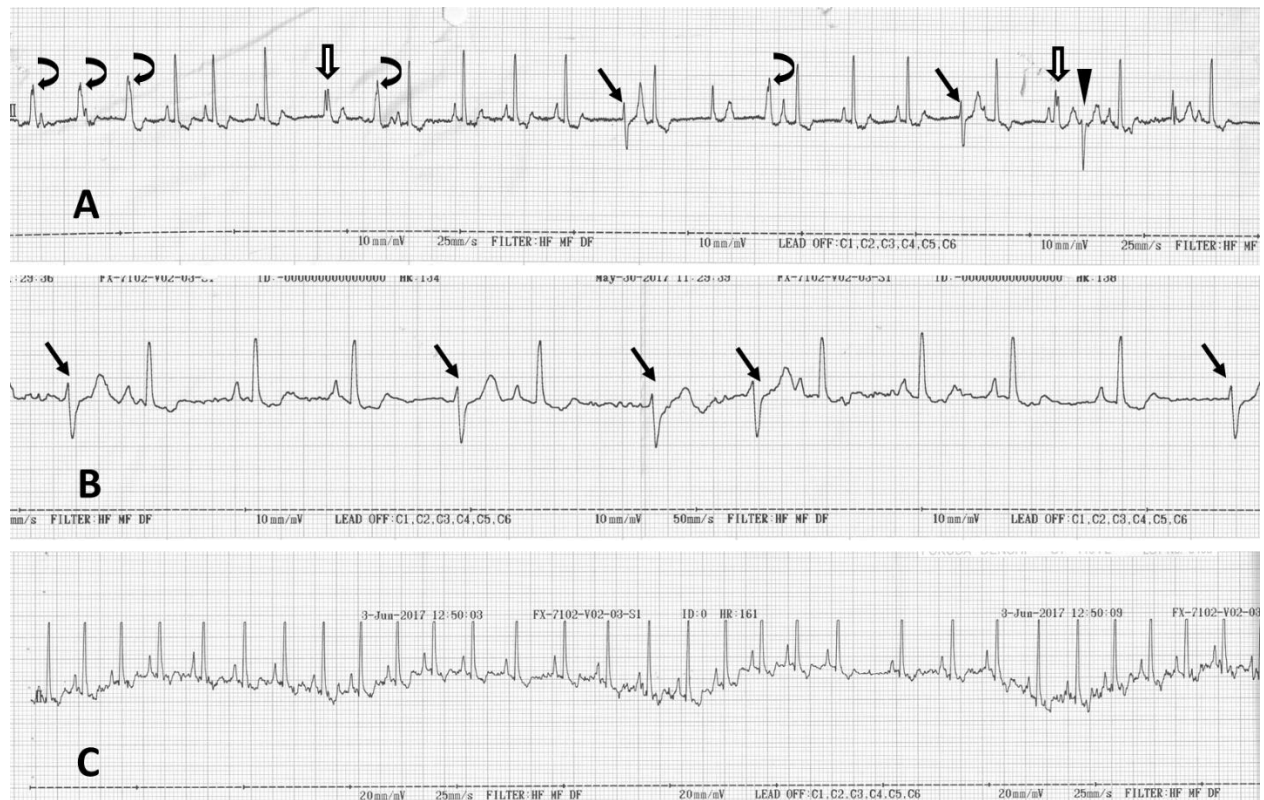

Figure 1 ECG recorded in a dog in intensive care unit 2 days after laparotomy to performed left nephrectomy and splenectomy at paper speed of 25 mm/sec (A) and 50 mm/sec (B). The ECG was repeated 6 days after surgery (C).

Interpretation

Figure 1A and 1B - Sinus rhythm with ventricular ectopy and some fusion beats
Figure 1 C - Sinus arrhythmia



The tracings in figure 1A and 1B had paper speed of 25 and 50 mm/second, respectively. In Figure 1A, many shapes of ECG waveforms that have both left and right axis deviation are seen. The basal intrinsic sinus rhythms could be seen with the rate of approximately 125 to 150 beats per minute. However, there inconsistent R- R interval suggesting that the respiratory sinus arrhythmia occurs. Please notice two different kinds of ECG waveforms with right axis deviation (dark straight arrows and triangle). These waveforms are originated in different locations below the atrioventricular junction inside the ventricle since the preceding p-wave was not seen. The emerging ventricular waveforms were usually presenting when the rate of sinus was slow down during respiratory cycle. Thus, the accelerated idioventricular rhythm was accomplished. Other bizarre waveforms with wide and upward reflections (curve arrows and opened arrows) were seen without p-wave. Thus, the delayed depolarization of left part of ventricle in which impulses do not travelling along the left bundle branch was suggested. Some ECG waveforms have characteristic in between two different shapes. The last opened arrow ECG complex show the combined shape of sinus and ectopic waveform. Thus, the electrical signal can be fused to make another different waveform called the "fusion beat". The severity of ECG abnormalities will depend upon whether the

ectopic beats can cause electrical instability or unstable blood pressure. These types of ventricular ectopy may not involve the intrinsic heart disease but may cause by other factors such as abnormal autonomic modulation such as high sympathetic enhancement especially during big surgery involved abdominal organs. Also the abnormal electrolyte both Na and K can cause the ECG abnormalities. In this patient, the dog had multiple diseases although the specific cause of arrhythmia may not be demonstrated. The abnormal ECG was seen 2 days after splenectomy which corresponding to the previous findings that ventricular arrhythmia may occur in dogs a few days after splenectomy and was found due to autonomic imbalance especially impaired parasympathetic regulation of the heart. Also, impaired the cardiac autonomic function occurred in dog suffering from diabetes mellitus. Thus, the ventricular ectopy in this case was not surprising.

The supportive treatment and maintained the normal homeostasis both electrolytes, acid-base balance including pain management will be crucial. The antiarrhythmic drug may be necessary if the blood pressure could not be maintained causing inadequate perfusion. On day 6 after surgery, dog still had the tachycardia although ventricular ectopy was unseen. The underlying disease should be control to ensure normal heart rate.