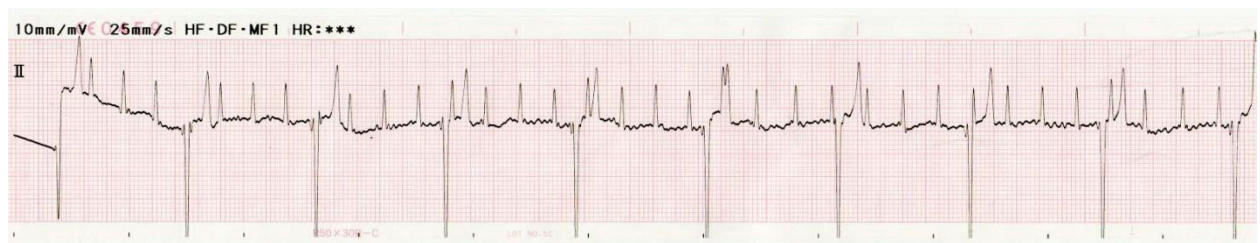

## ECG Quiz

Chollada Buranakarl<sup>1</sup>

A nine-years old intact male Miniature Pinscher weighting 4.8 kg with body condition score 4 out of 5. He was referred from private hospital with a history of chronic coughing, periodic panting and exercise intolerance. Previous thoracic radiograph revealed heart enlargement without pulmonary edema. The dog was previously prescribed the cardiac drugs including angiotensin converting enzyme inhibitor, diuretic drug (furosemide) and Coenzyme Q10 for a period of 6 month. By the time he presented in the hospital, dog showed no clinical signs of heart or respiratory disease. The dog never had any fainting or syncope. From physical examination, the lung sound was normal with abnormal heart sound. The heart sound not only had a soft low tone with high rate but also the louder sound with slower rate. Blood tests were performed and the complete blood counts showed slightly leukocytosis ( $WBC = 14,860 \text{ cell/mm}^3$ ) while the biochemical profiles for liver and kidney function tests including glucose concentration were normal. The electrocardiogram was recorded and lead

II ECG was shown in Figure 1. The thoracic radiograph was re-performed and the results showed whole heart enlargement with an enlarged pulmonary vessels. Dog also had hepatomegaly and mild splenomegaly. No evidence of pulmonary edema was found. From echocardiography showed the both cardiac chambers enlargement especially the right side. The thickening and insufficiency of both tricuspid and mitral valves were found with  $LA/Ao = 1.79$ . Fractional shortening was 44 – 64%. The main pulmonary pressures were approximately 27 mmHg. The caudal vena cava distention was also observed. Abdominal radiograph showed cholecystitis, mild pathological changes at the body of pancreas, mild to moderate BPH and sand calculi packed at prostatic urethra. The positive inotrope, pimobendan and bronchodilator were added along with angiotensin converting enzyme inhibitor and diuretic. Antibiotic was prescribed to control infection. One week after medication dog was more alert with improved exercise tolerance and less coughing.



**Figure 1** ECG tracing recorded during the first admission

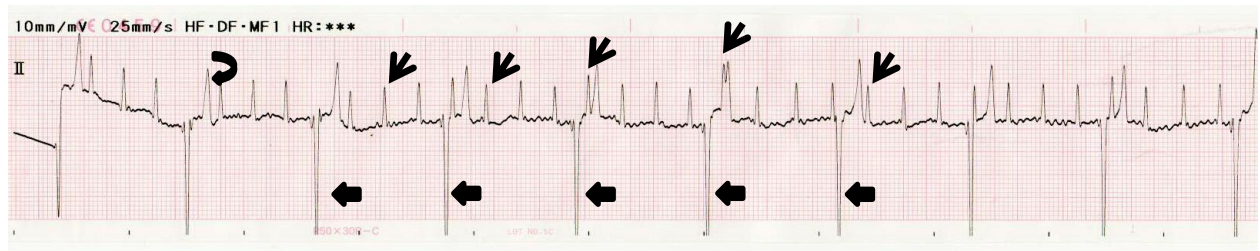
Please answer before turning to the next page.

---

<sup>1</sup>Department of Veterinary Physiology, Faculty of Veterinary Science, Chulalongkorn University

## Interpretation

**Figure 1 - Complete atrio-ventricular (AV) dissociation**



The ECG tracing was recorded during the first admission in dogs with a clinical signs of periodic coughing and difficult in breathing especially at night for a short time period. Dog was overweight with body condition score 4 from 5. The heart sound appeared to be arrhythmia with unique louder sound call "cannon heart sound". The possible cannon sound could be heard on the last complexes with curve arrow in which the duration from P-wave was close to the impulse originated from ventricle or the atrial contraction was closed to the ventricular contraction. Therefore, the atrioventricular valve at that time was still open. When the ventricle was contracted, the first heart sound will be louder. This sound could be detected and specific for the third degree AV block or complete AV dissociation.

The small thin arrows from tracing demonstrated the P-waves that originated from sinoatrial node with the rate of approximately 200 beats per minute. Some P-wave may superimposed on the T-wave of ectopic beat as seen in the 4<sup>th</sup> arrow. The complexes with bizzared shape (solid big arrows) were originated from ventricular in origin with rate of 50

beats per minute. All P-waves did not follow with normal QRS complexes suggest that none of them travelling pass AV node through Bundle of His and eventually reach ventricle. The intrinsic rate of ventricular pacemaker was much lower than SA node which determined whether the cardiac output is compromised. In this case, the dog showed no prominent signs of heart failure. However, since the ventricular rate was slow, therefore, blood pressure should be checked frequently. The sign of respiratory distress may be associated with airways disease or bronchial stenosis which is commonly found in obese dog. The echocardiography confirmed that the dog had both mitral and tricuspid valve insufficiency. Therefore, the positive inotrope, preload reducer and afterload reducer were prescribed. The problem of mechanical event may be corrected by medication but the electrical impulses which were blocked at the level of atrioventricular node should also be concerned. Frequent physical checkup and monitoring of ECG is required. The clinical symptoms were improved but reduced body weight was still recommended.