

Efficacy of Scalp Electroencephalography (EEG) as a Supportive Diagnostic Tool in Canine Epilepsy using Dexmedetomidine

Pichayaporn Soison¹ Waraporn Aumarm^{1*} Bordin Tiraphut¹ Chalernpol Lekcharoensuk¹

Apasri Lusawat² Kanjana Unnwongse² Khwanrat Wangphonphatthanasiri² Ubol Paramee²

Abstract

The objectives of the present study were to evaluate the electroencephalography (EEG) patterns between healthy and epileptic dogs, to analyze the diagnostic value of scalp EEG for canine epilepsy under sedation with dexmedetomidine and to provide canine standard protocol. EEG of 29 epileptic dogs and 17 control dogs was recorded. Normal patterns, interictal epileptiform, and non-epileptiform abnormalities were interpreted using visual analysis by board-certified epileptologists. Results revealed that 34% of the dogs with epilepsy did not show discernible abnormalities on their EEG recordings. Approximately 38% of the epileptic dogs presented interictal epileptiform discharges, 28% had only non-epileptiform discharges, and 24% had both abnormalities. Sixteen of the control dogs had normal EEG pattern while one of them had non-epileptiform pattern. To identify the interictal epileptiform discharges, EEG had 37.93% sensitivity and 100% specificity for the epilepsy group compared with the normal dogs. The interictal scalp EEG, as a result, had high specificity for supporting the diagnosis of epilepsy in dogs. Moreover, administration of 5-8 mcg/kg of dexmedetomidine via the intravenous (IV) route was recommended for canine EEG study because it provided non-rapid eye movement (REM) sleep EEG, together with awake period in each tracing which was valuable for EEG interpretation. EEG, as a result, is one of the considerably useful tools to evaluate cerebral functions and epileptiform discharges. Therefore, our study suggested that EEG should be a routine diagnostic tool for ruling in canine epilepsy.

Keywords: dexmedetomidine, dogs, electroencephalography, epilepsy, sensitivity, specificity

¹Department of Companion Animal and Clinical Sciences, Faculty of Veterinary medicine, Kasetsart University, Bangkok, 10900 Thailand

²Department of Neurology and Pediatric Neurology, Prasat Neurological Institute, Bangkok, 10400 Thailand

*Correspondence: foetwpa@ku.ac.th

Introduction

Seizures and epilepsy in dogs have been the most common neurological disorders at Kasetsart University Veterinary Teaching Hospital (KUVTH). These dogs were diagnosed by history and clinical signs. Scalp electroencephalography (EEG) is very useful for supporting the diagnosis and confirming epilepsy, particularly ictal-epilepsy. EEG is a safe, inexpensive, and less-invasive method. Similar to human, veterinarians mainly use EEG to confirm epileptic seizure (Holliday and Williams, 1998; Jaggy and Bernardini, 1998; Pellegrino and Sica, 2004; Jeserevics et al., 2007; Poma et al., 2010; Sheth and Abram, 2010), classify seizure type, and localize epileptic focus (Berendt and Gram, 1999; Licht et al., 2002; Podell, 2004). EEG abnormalities may be classified as epileptiform and non-epileptiform discharges. Epileptiform discharges are specific for epilepsy diagnosing and provide seizure focus. Non-epileptiform discharges are associated with non-specific cerebral dysfunction and sometimes due to a demonstrable structural lesion. Even though EEG plays a crucial role in clinical diagnosis, management of epileptic disorder and monitoring of status epilepticus (Raith et al., 2010), routine utilization in veterinary practice is less for epileptic dogs due to the lack of a universal standard for the recording technique, the absence of a common chemical restraint method, and the deficiency of information on EEG patterns of normal dogs under each type of chemical restraint. Movement and muscular artifacts are major problems in non-sedated patients for EEG recording. To obtain high-quality tracings, chemical restraint is required.

Dexmedetomidine (DEXDOMITOR™, Zoetis, Orion Pharma, Orion Corporation, Espoo, Finland) is a selective α -2 adrenoceptor agonist, approved for short-term use as sedative and analgesic agents. According to a number of researches, it could be assumed that sedation under dexmedetomidine imitates natural sleep; moreover, it produces an easily arousable state of moderate-to-deep sedation (Bekker and Jorden, 2004; Ray and Tobias, 2008). For this reason, dexmedetomidine is an appropriate sedative agent for EEG study. However, the study of EEG patterns under dexmedetomidine has been limited. The purposes of this study, consequently, were to evaluate the EEG patterns in healthy and epileptic dogs under sedation with dexmedetomidine, to clarify the specificity and sensitivity of EEG in order to evaluate veterinary clinical profit, and to provide EEG protocol with dexmedetomidine sedation and electrode positioning.

Materials and Methods

Dogs: Physical and neurological examinations were performed in all patients. Epilepsy, afterwards, was diagnosed by indications of clinical seizures. The selection criteria for those in epilepsy group were to have a history of at least 2 epileptic seizures and no clinical seizure during examinations. As for control group, those without history of seizure or neurological diseases before entering the study were included. Moreover, all underwent normal physical and

neurological examinations and did not have any systemic disease. Blood collection was conducted in the dogs from both groups to check complete blood count, liver enzyme (alanine aminotransferase, ALT), and creatinine in order to examine general state of health before sedation. Only those with no significant abnormalities on their blood profiles were selected. In addition, owners of all dogs participating in the study were required to complete a consent form for the study. All procedures were approved in advance by the Ethics Committee of Kasetsart University.

Equipment and Parameters of EEG: EEG was recorded using Harmonie version 7.0a EN, Stellate vita ICU EEG equipment (HSYS-REC-DUO-PP, Stellate, Montreal QC, Canada). Platinum or stainless needles, 10 mm in length, were used for active, reference, and ground electrodes. EEG recording setup were: sensitivity = 7.5 mV/mm, high filter = 70Hz, low filter = 1 Hz, notch filter = 50 Hz, paper speed = 3 cm/sec; impedance of the electrodes was less than 10 kilo-ohm.

Sedation protocol: Food and water were withheld for 8 hr prior to sedation in all dogs. A catheter was placed either into the cephalic or the lateral saphenous veins, then 0.9% saline solution was administered intravenously (IV) at a rate of 10 mL/kg/h. All EEG recordings were performed in all animals under dexmedetomidine sedation in a quiet, dark, and cool room (24-25°C). Dexmedetomidine was IV administered using a dosage of 3-4 mcg/kg. In case a dog was not ready for EEG preparation, an additional 1-2 mcg/kg of dexmedetomidine was IV administered until the dog slept by 10-15 min after the initial injection. The optimum depth of sedation was the light sleep, stage of consciousness from awake to non-REM (rapid eye movement) sleep. A lead II electrocardiogram (ECG) was recorded via two subdermal needle electrodes of the electroencephalograph at both sides of the thorax. Body temperature, heart rate, and respiration rate were monitored during sedation. Each recording was performed in the same manner at the Electro-Diagnosis Unit, of the Neurological Clinic at the KUVTH. After recording, all electrodes were removed and then the dogs were slowly administered with an atipamezole (Antisedan®, Zoetis, Orion Pharma, Orion Corporation, Espoo, Finland), antidote to dexmedetomidine, via the IV route using the same amount as the initial dexmedetomidine given.

Procedure: After sedation, the skull was measured and marked for positions of electrode placement. The positions of electrode were modified from the 10-20 international system. However, either 11 or 15 electrodes were applied according to skull sizes. Then, needle electrodes were inserted subcutaneously into the marked points in the cranio-caudal direction. EEG montages were selected depending on body weight. "SMDOG" was used in dogs having small skulls and up to 10 kg body weight (Fig 1A). This montage needed 11 active electrodes that were positioned in the frontal (Fz, F3 and F4), central (Cz, C3 and C4), parietal (Pz, P3 and P4), and occipital (O1 and O2) areas. Another two were a reference electrode placed on the bridge of the

nose and a ground electrode caudal to the external occipital protuberance. A different montage, "Double banana" (Fig 1B), was used in dogs weighing more than 10 kg. It used 15 active electrodes on the frontopolar (Fp1 and Fp2), frontal (Fz, F3, and F4), central (Cz, C3, and C4), parietal (Pz, P3, and P4), occipital (O1 and O2), and temporal (T3, T4) areas. The

reference and ground electrodes were placed on the same area as the SMDOG montage. Each EEG was recorded continuously for at least 20 min. To obtain awake EEG, no sedative drug was added in the last 10 min. In case of uncooperative dogs, physical restraint was gently required.




Figure 1 Positions of the electrodes for small-sized dogs (A.) and medium-to-large-sized dogs (B.)

EEG Interpretation: Bipolar and reference montages were used for visual examination of all EEG outputs. Interictal epileptiform discharges consisted of sharp wave (transient, clearly distinguishable from background activity, with a duration of 70-200 milliseconds), spike (same as sharp wave but with duration of 20 to < 70 ms), spike and wave complex (a spike followed by a slow wave), polyspikes (two or more spikes associated with one or more slow waves), and train of rhythmic slow theta activity in temporal area. In contrast, non-epileptiform EEG abnormalities comprised abnormal slow activity, asymmetry (>50% amplitude with asymmetry and 2 Hz or more

frequency with asymmetry) and excess fast activity. Apart from EEG abnormalities, electroencephalographers were also asked to define normal sleep structure (slow wave sleep, vertex sharp transients, and sleep spindle). EEG patterns were reviewed and reported by a veterinarian based on human EEG characteristics and were, finally, approved by experienced human epileptologists/electroencephalographers at the Prasat Neurological Institute, Bangkok, Thailand. Yields of EEG abnormalities were compared between the two experimental groups of dogs.

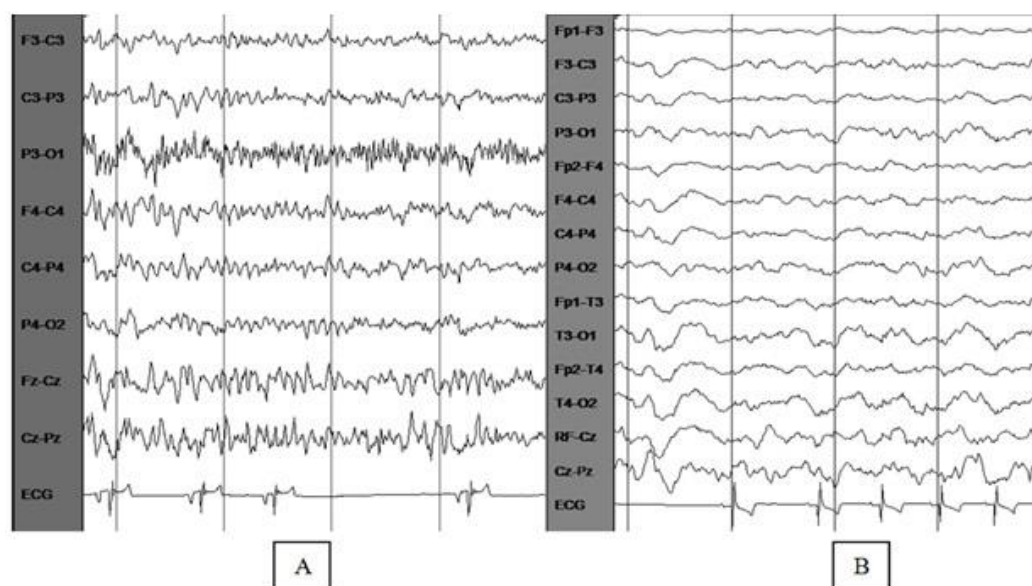


Figure 2 (A.) During awake, muscle artifacts and alpha activity, 10-12 HZ, and 10-30 were waxing and waning in EEG tracing of 10-month-old Chihuahua. (B.) Normal EEG pattern during sleep in dog under sedation with dexmedetomidine.

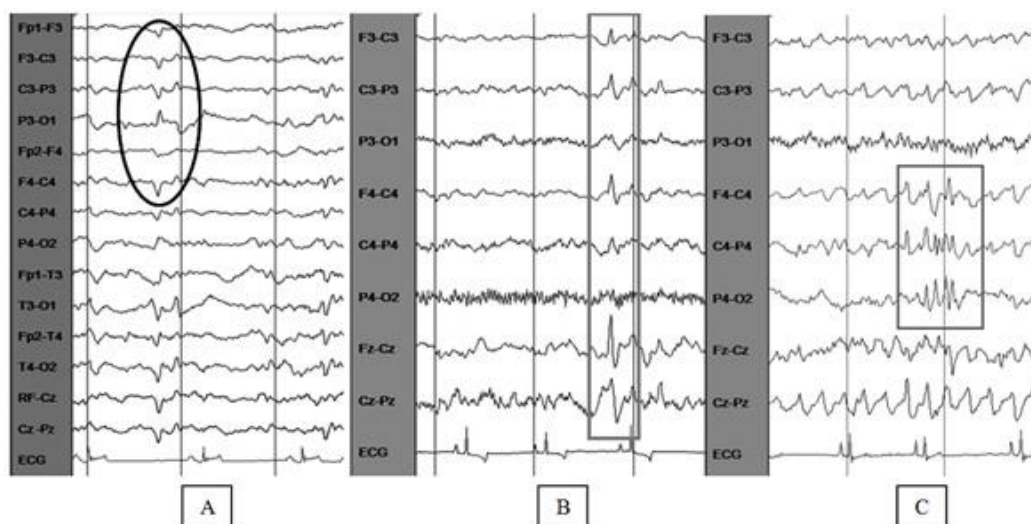


Figure 3 Three EEG tracings showing interictal epileptiform discharge including (A) sharp wave, regional bilateral parieto-occipital region, maximum negativity at left parietal region (B) spike and wave complex in bilateral frontal area, maximum negativity at Fz. and (C) polyspikes in right fronto-centro-parietal region, maximum negativity at C4

Other outcomes: Total dosages (mcg/kg) of dexmedetomidine were recorded. The awake stage was estimated by the presence of alpha activities, eye movement (eyes closed and eyes opened), muscle artifacts, or any movement of the body parts. The sleep period in each EEG tracing was calculated as a percentage of the total EEG recording.

Statistical analysis: Descriptive statistics were performed for all dogs, including the data on the EEG

pattern and characteristics of sedation. The sensitivity, specificity and predictive values of each EEG pattern were analyzed by Win Episcopo 2.0® software (version 2.0, Epidecon, Wageningen University, Wageningen, NL). Age, sex, weight, percentage of sleep and dosage of dexmedetomidine were analyzed by non-parametric Mann-Whitney U and chi-square to find significant differences between the epilepsy and control groups. Results were considered significant if $p < 0.05$.

Table 1 Descriptive statistics (mean±SD) of dogs between epilepsy and control groups

	Epilepsy (n=29)	Control (n=17)
Age (year)	3.80±3.38	4.22±2.58
Sex		
-Female (%)	37.93 (n=11)	41.18 (n=7)
-Male (%)	62.07 (n=18)	58.82 (n=10)
Weight (kg)	12.67±11.84	12.81±10.42
Percentage of Sleep* (%)	70.86±23.34	47.35±35.36
Dosage of Dexmedetomidine (mcg/kg)	7.92±5.04	5.63±2.90

* Duration of sleep x 100/ total time of recording

Table 2 Various breeds of dogs in control and epilepsy group

Control group	Epilepsy group
Poodle (5), Cross-bred (4), Golden Retriever (2), Beagle (1), Cocker Spaniel (1), Pomeranian (1), Pug (1), Shih Tzu (1), Yorkshire Terrier (1).	Pomeranian (6), Chihuahua (6), Beagle (4), Cross-bred (4), Golden Retriever (2), Siberian Husky (2), American Pit Bull (1), Cocker Spaniel (1), Jack Russell (1), Shih Tzu (1), Yorkshire Terrier (1)

Results

In total, 29 dogs in the epilepsy group, 5 myoclonic seizure, 6 tonic seizure and 18 generalized

tonic-clonic seizure dogs were included. Descriptive statistics of the dogs both in the epilepsy and control groups are informed in Table 1. Various breeds of dogs in the control and epilepsy groups are shown (Table 2).

In the epilepsy group the final diagnosis was done in 15 dogs; cerebrovascular accident (n=3), granulomatous meningoencephalitis (n=1), hydrocephalous (n=6), meningoencephalitis (n=1), traumatic brain injury (n=1) and brain tumor (n=2) and cryptogenic epilepsy (n=1).

Most of the dogs had both sleep and conscious periods during recording. The movement of body parts was observed in some dogs during recording. The alpha activity, 8-13 Hz, was seen in the end phase of recording of all dogs awakened (Fig 2A). During sleep, all dogs in both groups had normal sleep pattern (Fig 2B). In addition, all dogs showed sinus arrhythmia, 41.7% of the epileptic dogs and 58.8% of the control dogs presented bradycardia during sedation. From our study, it was found that the dogs in the epilepsy group had significantly higher percentage of sleep than those in the control group ($P = 0.01$).

The EEG results of both groups are presented in Table 3. Seven dogs in the epilepsy group had both

EEG abnormalities (interictal epileptiform and non-epileptiform), while four dogs had only interictal epileptiform. The characteristics of interictal EEG pattern were described by 69% sharp waves (Fig 3A), 15.5% spikes and wave (Fig 3B), and 15.5% polyspikes (Fig 3C). Only one dog had EEG seizure without clinical signs during EEG recording. Eight dogs presented only non-epileptiform discharge. This pattern comprised 35% intermittent focal slow, 35% continuous focal slow, 18% intermittent generalized slow, and 12% continuous generalized slow. Ten dogs in the epilepsy group had normal EEG pattern.

The normal EEGs were found in 16 control dogs, while one dog had non-epileptiform discharges. For statistical analysis, the diagnostic test evaluation of the EEGs showed interictal epileptiform discharges with 37.93% sensitivity and 100.00% specificity. Positive and negative predictive values were and 100% and 48.57%, respectively (Table 4).

Table 3 EEG results of dogs in epilepsy and control groups

Group	EEG pattern		
	Normal (Dog)	Non-epileptiform (Dog)	Interictal epileptiform (Dog)
Epilepsy	10	15	11
Control	16	1	0

Table 4 Diagnostic test evaluation

Test/condition	Epilepsy	Control (Healthy)	Total
Positive for epileptiform	11 (true positive)	0 (false positive)	11
Negative for epileptiform	18 (false negative)	17 (true negative)	35
Total	29	17	

Discussion

EEG was considered a good supporting diagnostic tool for human epilepsy patients even though its sensitivity varies from 25 to 56%. However, many literatures reported that the specificity of EEG was high, ranging between 78-98% (Smith, 2005). In veterinary medicine, EEG has been used since the 1950s; however, the information about EEG for detecting canine epilepsy is insufficient due to a number of limitations. A number of studies reported that 12.5-86% of dogs with seizure showed interictal epileptiform (Holliday and Williams, 1998; Jaggy and Bernardini, 1998; Berendt and Gram, 1999; Podell, 2004; Chandler, 2006; Jeserevics et al., 2007; Akos et al., 2012). The present study showed that EEG in dogs under sedation with dexmedetomidine had low sensitivity (37.93%, 95% CI = 22.7, 56) for detecting interictal epileptiform activities but high specificity (100%) at 95% CI (81.6, 100). The positive and negative predictive values were 100% and 48.57%, respectively. The possibilities of different EEG yields in this study were the effect of sedative agent. Dexmedetomidine enhances an endogenous sleep pathway and mimics a natural sleep (Wagner and Brummett, 2006; Ray and Tobias, 2008; Tepper and Shores, 2014); normal sleep structures were demonstrated in the EEG tracing of

most dogs in this study, moreover, it had minimal effect on electrocortical activities. Other studies got lower yields of EEG due to the use of other sedative or anesthetic agents such as propofol, barbiturates, or halothane, which suppress the cortical activity (Farber et al., 1997; Bekker and Jorden, 2004). For example, in the study of Akos et al. (2012) conducted in dogs with symptomatic and idiopathic epilepsy under propofol anesthesia, the epileptiform discharges were observed only in 12.5% of the epileptic dogs (5/40). Moreover, Brauer's research (2012b), in which EEGs were recorded in epileptic dogs under general anaesthesia with propofol and muscle relaxant, rocuronium bromide, reported epileptiform activities in 20% of dogs with idiopathic epilepsy, and 28% with symptomatic epilepsy.

There is argument regarding the potential convulsant effects of dexmedetomidine. Some studies reported that high dose of dexmedetomidine reduced the seizure threshold in animal models (proconvulsant effect) (Mirski et al., 1994; Miyazaki et al., 1999), whereas anticonvulsive effects were noticed in other researches in which dexmedetomidine increased the dose of cocaine (Whittington et al., 2002) and the dose of either levobupivacaine or bupivacaine (Tanaka et al., 2005) required to cause seizure in rat. However, in the study of Mason (2005), influence of dexmedetomidine

sedation on the visual EEG was compared to natural stage II sleep in children with epilepsy and the authors suggested that dexmedetomidine sedation elicited an EEG pattern similar to that of stage II sleep and did not change or add new spike foci (Mason et al., 2009). In addition, dexmedetomidine was used successfully in epileptic patients during awake craniotomy for seizure focus resection (Bekker and Sturaitis, 2005). Accordingly, dexmedetomidine seems to be a promising agent for sedation in canine EEG study due to its features in action and as an antidote, effectiveness, and safety.

EEG was recorded at both awake and sleep stages in human (Diaz-Negrillo, 2013). The various patterns in both awake and sleep studies have additional value to diagnose the severity of encephalopathy. Awake EEG explains conscious brain function while sleep EEG significantly shows increasing incidence of interictal epileptiform activities (Smith, 2005). Our study gained the results in both awake and sleep stages. Thus, they increased the specificity to diagnose epilepsy.

This study applied more electrodes to cover more areas of the brain. For a decade, many EEG recording techniques have been used, for example, the technique proposed by Pellegrino based on anatomical site using 12 electrodes (Pellegrino and Sica, 2004; Poma, 2010), Redding montage (Brauer et al., 2012a; Brauer et al., 2012b) using 5 sub-dermal needle electrodes (F3, F4, Cz, O1, and O2), and modified 10-20 international methods (Bergamasco et al., 2003). This study applied the international 10-20 technique and used 11 and 15 electrodes for different sizes of skull.

From our study, the majority of dogs (7 of 11 dogs) presenting interictal epileptiform discharges were clearly diagnosed with structural epilepsy, while the others could not finally be diagnosed. In addition, it is vastly interesting that 5 out of 7 dogs suffering from hydrocephalus were diagnosed with the interictal EEG. Therefore, according to the findings of Akos et al. (2012), this study concluded that the types of epilepsy, particularly a structural symptom, might be related to epileptiform abnormality detection.

In humans, the prevalence of epileptiform discharges in routine EEG is 0.5% in healthy adults and 2-4% in healthy children (Smith, 2005). Moreover, in veterinary aspect, the study of Jeserevics et al. (2007) reported paroxysmal epileptiform activity in 1 of 16 healthy dogs (6.25%). However, interictal epileptiform was not revealed in any healthy dog; it probably resulted from the little sample size. Hence, a future study should be conducted in bigger scale to explore the genuine specificity of EEG.

The present study demonstrated normal sleep pattern in every dog and alpha activity in all awake dogs. This study could capture the stages of consciousness from awake to non-REM sleep in each examination; however, each age had difference in frequency and amplitude.

Excessive beta activity is only a non-epileptiform EEG abnormality and was not found in our study. However, this excessive fast activity was frequently revealed in patients prescribed sedative agents such as chloral hydrate (a common drug used in children). This manifestation obscurely affected many

EEG features, especially epileptiform activities. For this reason, dexmedetomidine is the proper sedative drug for EEG study.

From our study, the dogs in the epilepsy group had higher percentage of sleep than those in the control group since most of the epilepsy dogs were given anti-epileptic drugs, contributing to the depression of the central nervous system. Hence, it could be concluded that the potential for drug interaction took place when they received both dexmedetomidine and anti-epileptic drugs (Vernau and LeCouteur, 2008). In addition, those in the epilepsy group were administered higher mean dosage of dexmedetomidine.

This study applied the modified international 10-20 system method. It is simple, consistent, and available for everyone including people who do not have canine anatomical knowledge. It could also be used in dogs with a variety of ages, sizes, breeds and skull types, and could be compared over time. Moreover, it allows adjusting the number of electrodes appropriately to very small skulls. Besides, this study applied 15 electrodes in the small dogs and 19 electrodes in the large ones (including reference, ground, and two ECG electrodes) to cover more extensive areas of the cerebral cortex, resulting in more effective detection of interictal epileptiform. For only the double banana montage, it could be applied over orbitofrontal and temporal areas; thus, it was appropriate for large-to-medium skull. However, SMDOG was still useful for puppies having tiny skulls.

Since the seizure threshold decreases during sleep (Podell, 2013), the percentage of sleep in the control group, which was less than that in the epilepsy group, could cause lower incidence of interictal epileptiform discharge. Therefore, it could not be confirmed that true specificity was acquired in this study.

A short action of IV dexmedetomidine resulted in EEG recording for only 20-30 min in most dogs. The photic stimulation was not used in this study because the dogs awakened easily under this sedation, especially in the last period, and they tried to remove the electrodes in the preliminary study. Moreover, the diagnostic value could not be increased by using photic stimulation (Brauer, 2011).

In summary, Dexmedetomidine is an appropriate sedative drug for canine EEG study since it is safe, has a minimal effect on EEG, and does not produce excessive beta fast activity interfering with an EEG interpretation. Based on the results of the present study, it could be concluded that the IV administration of dexmedetomidine 5-8 mcg/kg provided non-REM sleep EEG together with awake period in each tracing. However, 41.7% of the dogs in the epilepsy group and 58.8% of the dogs in the control group had bradycardia under sedation; therefore, bradycardia from drug effects should be concerned.

The diagnostic yield of EEG in epileptic dogs was demonstrated: the sensitivity and specificity was 37.93% and 100%, respectively. Furthermore, EEG is one of the considerably useful tools to evaluate cerebral functions and epileptic discharges, whereas other investigations lack these abilities. This study, therefore,

recommend EEG as a routine diagnostic tool for ruling in canine epilepsy.

References

- Akos P, Thalhammer JG, Leschnik M, and Halasz P 2012. Electroencephalographic examination of epileptic dogs under propofol restraint. *Acta Vet Hung.* 60(3): 309-324.
- Bekker A and Jorden VSB 2004. Alpha-2 agonists in neuroanesthesia. *Semin Anesth Perio M.* 23(3): 181-191.
- Bekker A and Sturaitis MK 2005. Dexmedetomidine for neurological surgery. *Neurosurgery.* 57(1): 1-10.
- Berendt M, Gram L 1999. Epilepsy and seizure classification in 63 dogs: a reappraisal of veterinary epilepsy terminology. *J Vet Intern Med.* 13: 14-20.
- Bergamasco L, Accatino A, Priano L, Neiger-Aeschbacher G, Cizinauskas S and Jaggy A 2003. Quantitative Electroencephalographic Findings in Beagles Anaesthetized with Propofol. *Vet J.* 166(1): 58-66.
- Brauer C, Kastner SBR, Schenk HC, Tümsmeyer J and Tipold A 2011. Electroencephalographic Recordings in Dogs: Prevention of Muscle Artifacts and Evaluation of Two Activation Techniques in Healthy Individuals. *Res Vet Sci.* 90(2): 306-311.
- Brauer C, Kastner SBR, Kulka AM and Tipold A 2012a. Activation Procedures in the Electroencephalograms of Healthy and Epileptic Cats under Propofol Anaesthesia. *Vet Rec.* 170(14).
- Brauer C, Kastner SBR, Rohn K, Schenk HC, Tümsmeyer J and Tipold A 2012b. Electroencephalographic Recordings in Dogs Suffering from Idiopathic and Symptomatic Epilepsy: Diagnostic Value of Interictal Short Time EEG Protocols Supplemented by Two Activation Techniques. *Vet J.* 193(1): 185-192.
- Chandler K 2006. Canine epilepsy: what can we learn from human seizure disorders? *Vet J.* 172: 207-217.
- Diaz-Negrillo A 2013. Influence of sleep and sleep deprivation on ictal and interictal epileptiform activity. *Epilepsy Res Treat.* 49:2524.
- Farber NE, Poterack KA and Schmeling WT 1997. Dexmedetomidine and halothane produce similar alterations in electroencephalographic and electromyographic activity in cats. *Brain Res.* 774: 131-141.
- Holliday TA and Williams DC 1998. Interictal paroxysmal discharges in the electroencephalograms of epileptic dogs. *Clin Tech Small Anim Pract.* 13: 132-143.
- Jaggy A and Bernardini M 1998. Idiopathic epilepsy in 125 dogs: a long-term study. Clinical and electroencephalographic findings. *J Small Anim Pract.* 39: 23-29.
- Jeserevics J, Viitmaa R, Cizinauskas S, Sainio K, Jokinen TS, Snellman M, Bellino C and Bergamascoet L 2007. Electroencephalography findings in healthy and Finnish Spitz dogs with epilepsy: visual and background quantitative analysis. *J Vet Intern Med.* 21: 1299-1306.
- Licht BG, Licht MH, Harper KM, Lin S, Curtin JJ, Hyson LL and Willard K 2002. Clinical presentations of naturally occurring canine seizures: similarities to human seizures. *Epilepsy Behav.* 3: 460-470.
- Mason KP, O'Mahony E, Zurakowski D and Libenson MH 2009. Effects of dexmedetomidine sedation on the EEG in children. *Paediatr Anaesth.* 19(12): 1175-1183.
- Mirski MA, Rossell LA, McPherson RW and Traystman RJ 1994. Dexmedetomidine decreases seizure threshold in a rat model of experimental generalized epilepsy. *Anesthesiology.* 81(6): 1422-1428.
- Miyazaki Y, Adachi T, Kurata J, Utsumi J, Shichino T and Segawa H 1999. Dexmedetomidine reduces seizure threshold during enflurane anaesthesia in cats. *Br J Anaesth* 82(6): 935-937.
- Pellegrino FC and Sica RE 2004. Canine electroencephalographic recording technique: findings in normal and epileptic dogs. *Clin Neurophysiol.* 115: 477-487.
- Podell M 2004. Seizures. In: *BSAVA Manual of Canine and Feline Neurology* 3rd ed SR Platt and NJ Olby (ed) Gloucester: British Small Animal Veterinary Association 95-112.
- Podell M 2013. Seizures. In: *BSAVA Manual of Canine and Feline Neurology* 4th ed SR Platt and NJ Olby (ed) Gloucester: British Small Animal Veterinary Association 117-135.
- Poma R, Ochi A and Cortez MA 2010. Absence seizures with myoclonic features in a juvenile Chihuahua dog. *Epileptic Disord.* 12: 138-141.
- Raith K, Steinberg T and Fischer A 2010. Continuous electroencephalographic monitoring of status epilepticus in dogs and cats: 10 patients (2004-2005). *J Vet Emerg Crit Care (San Antonio).* 20: 446-455.
- Ray T and Tobias JD 2008. Dexmedetomidine for sedation during electroencephalographic analysis in children with autism, pervasive developmental disorders, and seizure disorders. *J Clin Anesth.* 20: 364-368.
- Sheth RD and Abram HS 2010. Absence epilepsy with focal clinical and electrographic seizures. *Semin Pediatr Neurol.* 17: 39-43.
- Smith SJ 2005. EEG in the diagnosis, classification, and management of patients with epilepsy. *J Neurol Neurosurg Psychiatry.* 76 Suppl 2: ii2-7.
- Tepper L and Shore A 2014. Electroencephalographic Recordings in the Canine: Effects of Low Dose Medetomidine or Dexmedetomidine Followed by Atipamezole. *Open Journal of Veterinary Medicine.* 4: 7-13.
- Vernau KM and LeCouteur RA 2008. Anticonvulsant drugs. In: *Small Animal Clinical Pharmacology* 2nd ed JE Church, W Maddisonstephen and B Pagedavid (ed) Edinburgh: W.B. Saunders 368-371.
- Wagner DS and Brummett CM 2006. Dexmedetomidine: as safe as safe can be. *Semin Anesth Perio M.* 25: 77-83.

บทคัดย่อ

ประสิทธิภาพของ Scalp Electroencephalography (EEG) เครื่องมือช่วยวินิจฉัยโรคลมชัก ในสุนัขภายใต้ Dexmedetomidine

พิชญากร สร้อยสน¹ วราภรณ์ อ่วมอ่วม^{1*} บดินทร์ ตีระพัฒน์¹ เฉลิมพล เล็กเจริญสุข¹ อาภาศรี ลุสวัสถ์²
กาญจนา อ้นวงศ์² ขวัญรัตน์ หวังผลพัฒนศิริ² อุบล ปารมี²

การศึกษานี้มีวัตถุประสงค์ เพื่อศึกษารูปแบบของ electroencephalography (EEG) ในสุนัขปกติ และสุนัขที่เป็นโรคลมชัก ศึกษาความถูกต้องของผลการตรวจสุนัขที่เป็นโรคลมชัก ด้วย scalp EEG ภายใต้การระงับประสาท dexmedetomidine และหาเทคนิคมาตรฐานสำหรับการตรวจ EEG ในสุนัข กลุ่มตัวอย่างที่ใช้ในการศึกษา สุนัขที่เป็นโรคลมชัก 29 ตัว สุนัขปกติที่เป็นกลุ่มควบคุม 17 ตัว ได้รับการตรวจด้วย EEG และวิเคราะห์ผลการตรวจด้วยสายตา จากผู้เชี่ยวชาญโรคลมชัก โดยแบ่งรูปแบบเป็น normal, interictal epileptiform และ non epileptiform ผลการศึกษาพบว่าร้อยละ 34 ของสุนัขที่เป็นโรคลมชัก ไม่พบความผิดปกติของรูปแบบ EEG ร้อยละ 38 พบรูปแบบ interictal epileptiform และ ร้อยละ 28 พบ non-epileptiform discharge ร้อยละ 24 พบความผิดปกติทั้ง 2 รูปแบบ สุนัขสิบหกตัวในกลุ่มควบคุม พบรูปแบบ normal ของ EEG และ 1 ตัวพบ non-epileptiform. การตรวจ interictal epileptiform โดยใช้ EEG เพื่อช่วยวินิจฉัยโรคลมชักในสุนัข พบว่ามีความถูกต้องจำเพาะสูง โดยเมื่อเปรียบเทียบกับในกลุ่มสุนัขที่เป็นโรคลมชักและสุนัขปกติ พบว่ามีความไวในการตรวจร้อยละ 37.93 และ มีความถูกต้องจำเพาะร้อยละ 100 นอกจากนั้น จากผลการศึกษาแนะนำการให้ยา dexmedetomidine เข้าทางเส้นเลือดดำในขนาด 5-8 mcg/kg ทำให้พบรูปแบบ non-rapid eye movement (REM) และ awake period ในการตรวจ EEG ซึ่งมีส่วนช่วยในการวิเคราะห์ผลเป็นอย่างดี จากผลการศึกษาชี้ให้เห็นว่า EEG สามารถใช้เป็นเครื่องมือเพื่อตรวจการทำงานของสมอง และตรวจยืนยัน โรคลมชักในสุนัขได้ดี.

คำสำคัญ: dexmedetomidine สุนัข electroencephalography โรคลมชัก ความไว ความถูกต้องจำเพาะ

¹ ภาควิชาเวชศาสตร์คลินิกสัตว์เล็ก คณะสัตวแพทยศาสตร์ มหาวิทยาลัยเกษตรศาสตร์ กรุงเทพฯ 10900

² ภาควิชาการุณเวชศาสตร์ประสาทวิทยา สถาบันประสาทวิทยา กรุงเทพฯ 10400

*ผู้รับผิดชอบบทความ E-mail: fvetwpa@ku.ac.th