

Flash Visual Evoked Potentials in Normal Pomeranian Dogs and Those with Canine Cognitive Dysfunction

Thanawut Hamnilrat^{1,2} Chalernpol Lekcharoensuk⁴ Piyathip Choochalernporn³

Aree Thayananuphat^{4*}

Abstract

Visual evoked potential (VEP) is a useful technique for evaluation of optic nerve pathway and diagnosis of human Alzheimer's disease. Canine cognitive dysfunction (CCD) is an age-related neurobehavioural syndrome which is commonly underdiagnosed in dogs. In the present study, VEPs were recorded from 28 Pomeranian dogs including 9 normal dogs aged between 1-8 years, 9 normal dogs aged over 8 years, and 10 dogs with signs of CCD. Brain atrophy in 8 CCD dogs was confirmed by CT scan. The other two dogs with signs of CCD had tumor which was confirmed by CT scan and cerebrospinal fluid. The VEP components of dogs over and under 8 years old were not statistically different ($p>0.05$). P2 and P3 of the dogs with CCD were longer than those of the normal dogs ($p<0.05$). The VEPs in dogs with CCD and tumor had different patterns. In conclusion, VEP is a promising tool for the diagnosis of CCD in aging dogs.

Keywords: brain atrophy, cognitive dysfunction, dog, Pomeranian, visual evoked potential

¹Center of Agriculture Biotechnology, Kasetsart University, Nakhon Pathom 73140, Thailand

²Center of Excellence on Agricultural Biotechnology; (AG-BIO/PERDO-CHE), Nakhon Pathom 73140, Thailand

³Kasetsart Veterinary Teaching Hospital, Faculty of Veterinary Medicine, Kasetsart University, Bangkok 10900, Thailand

⁴Department of Companion Animal Clinical Sciences, Faculty of Veterinary Medicine, Kasetsart University, Kamphaengsaen Campus, Nakhon Pathom 73140, Thailand

*Correspondence: foetatr@ku.ac.th

Introduction

Canine cognitive dysfunction (CCD) or canine dementia is a neurobehavioural syndrome in aged dogs. This syndrome characterizes by deficit in several characteristics such as learning, memory and spatial awareness. Social interactions and sleeping patterns are possibly changed in CCD dogs (Landsberg et al., 2003). Several studies have identified CCD as a common problem in aged dogs. However, recent epidemiological surveys in the United States suggested that the disease was severely underdiagnosed with up to 85% of potentially affected animals failing to be identified (Salvin et al., 2010; Osella et al., 2007).

CCD shares several aspects with human dementia which include the progression of clinical syndrome (Cummings et al., 1996). CCD may, therefore, serve as a useful translational model for human dementia. However, the current major limiting factor for both research and community dog health is the absence of an evidence based tool for assessment and accurate monitoring of clinical progression or response to therapy.

Visual evoked potential (VEP), which indicates electrophysiological response from the retina to visual cortex, was reported as a useful technique for evaluation of optic pathway and also a sensitive indicator for human dementia, especially Alzheimer's disease. A recent study indicated that dogs over 9 years had prolonged latency of P2, N2 and P3 approximately 10% of normal physiological condition (Kimotsuki et al., 2006) and latency of dementia dogs might be above their normal physiological condition. Moreover, dementia problem in aging dogs may occur in old dogs with encephalitis and brain tumor which may result in different wave forms of VEPs. Therefore, the purpose of this study was to compare the VEP components of normal young and aging Pomeranian dogs with CCD Pomeranian dogs and investigate the VEP patterns in dogs with CCD and dogs with brain tumor.

Materials and Methods

Animals: Twenty-eight Pomeranian dogs were used in this study. All dogs had normal eye structure, vision and blood tests (CBC, BUN, creatinine, ALT). The samples consisted of 9 normal dogs at the age of 1-8 years old, 9 normal dogs at the age over 8 years, and 10 dogs with signs of CCD classified by modified DISHA questionnaire (CDS checklist, Landsberg et al., 2012). Skull size was measured by vertical length (from nasion to occipital protuberance), and horizontal length (from both anterior ear lobes). All dogs with signs of CCD were further diagnosed by CT scan for their brain atrophy and other abnormalities. Cerebrospinal fluid was further collected after CT scan in dogs with signs of CCD and without brain atrophy from CT scan.

VEP Recordings: Flash VEPs were performed in a dark shield room. Needle electrodes (Platinum subdermal electrode; GRASS Technologies, An Astro-Med, Inc. Subsidiary: USA) were used to record responses. Areas for electrodes were prepared by 70% alcohol cleaning. Electrode impedances were kept below 5 kohm and difference of impedances between electrode sites did

not differ by more than 20% to reduce electrical interference. The VEPs were recorded by a 3-channel electrode recording system. Electrodes of recording, reference and ground were placed over O1, O2, Oz (recording), Fpz (reference) and Cz (ground). All names and positions followed the 10-20 International system (Odom et al., 2010). Stimuli consisted of white flash light at a rate of 1/sec (1 Hz) with an intensity of 1 joule using Photoc stimulator (SLE, CPS-20; Medilec Synergy, VIASYS, Medison, USA). A flash generator unit was held approximately 20 cm and 30 degree deviation from midline away from the eye. The contralateral eye was covered by a dark bandage during recordings. All dogs were sedated with 0.02 mg/kg dexmetomidine (Dexdometer; pfizer animal health, Orion Corporation; Espoo Finland) intravenously to restrain and avoid muscle artifact (Bekker et al., 2004).

Separate VEPs were taken from both eyes of each animal. An average of 30 responses were recorded and repeated 3 times for each eye to assess repeatability. Three average waveforms of 30 responses for each eye were composed of responses from O1, O2 and Oz followed by recording electrode. A bandpass filter was set at 1 Hz low and 100 Hz high. The responses were collected with a computer-based electrodiagnostic signal averaging system (Medilec Synergy, VIASYS, Medison, USA). Measurements consisted of the latencies of each peak. Amplitudes were measured from peak to peak rather than from baseline to peak amplitude on conventional of previous studies to determine the influence of age and CCD (Kimotsuki et al., 2005).

CT scan: CT scan of the brain was performed in 10 dogs diagnosed with CCD from modified DISHA questionnaire. All CCD dogs received intravenously 0.02 mg/kg dexmetomidine for sedation and intravenously 10 mg/kg propofol for induction. The anesthesia was maintained with 2% isoflurane inhalation. All dogs with CCD signs were investigated by CT scan for their brain abnormality with 64-slice multidetector computed tomography (OPTIMA 660; GE Medical System, Milwaukee, WI) and a contrast study was conducted with intravenously Iohexol (300 mg iodine/cc) (Omnipaque; GE health care, AS Nycoveien) 600 mg iodine/kg.

CSF analysis: Cerebrospinal fluid (CSF) was obtained from 10 dogs after CT scan. CSF was collected from the cerebellomedullary cistern with the site of collection clipped and aseptically prepared. Endotracheal tube was used to reduce the chance of tracheal tube kinking and the cuff was deflated to reduce tracheal trauma before neck flexion. One to two milliliter of CSF was immediately measured for CSF total protein (microalbumin) by a colorimetric method using ILab 650 analyzer (Instrumentation Laboratory, USA) and total nucleated cell count (TNCC) by CELL-DYN 3700 (Abbott, USA). Slide preparations were performed by cytocentrifugation with Cytospin3 (Shandon, USA) at 550-700 rpm for 5 min depending on TNCC and stained with modified Wright's Giemsa.

Data Analysis: Descriptive statistics consisting of the mean, standard deviation (SD), and range for each latency and amplitude measurements were calculated. One way ANOVA was used for testing statistical significance between the latency and amplitude of the components in VEP among the 3 groups. If a significance ($p < 0.05$) was found, post hoc comparison with Tukey method was performed. Linear regression was also performed between the latency or amplitude of the components in VEPs and age. If the regression model was significant, values of the latency or amplitude of VEP components were proposed for detection of early CCD by substituting age (95% confidence) in the model with the value of mean age - $1.96 \times \text{SD}$.

Results

Of total 28 dogs, 16 (57%) were male and 12 (43%) were female. The mean body weight of all dogs was 3.6 ± 1.22 kg (2.3-4.8 kg). The mean skull size of all dogs by vertical length was 8.3 ± 0.65 cm (7.5-9 cm) and by horizontal length was 7.5 ± 1 cm (6.5-8.5 cm). The group of dogs under 8 years consisted of 4 males and 5 females. The group of dogs over 8 years consisted of 4 males and 5 females. The group of dogs with signs of CCD consisted of 8 males and 2 females. The average ages of dogs under 8 years, over 8 years, and with CCD signs were 4.1 ± 1.76 (1 to 8 years) years old, 10.6 ± 2.18 (9 to 15 years) years old, and 13.6 ± 2.18 (11 to 16 years) years old, respectively.

Eight out of ten dogs with signs of CCD had brain atrophy (Table 1). The CT scan images showed decrease in the frontal lobe brain volume and ventricular dilatation. The other two dogs had brain

tumor by showing signs of leptomeningeal contrast enhancement and periventricular contrast enhancement following dye injection (Fig 1).

The flash VEP waveform consisted of 6 peaks. Negative peak troughs were labeled "N" and positive peak troughs were labeled "P", followed by its sequence number (identified as N1, P1, N2, P2, N3 and P3). The amplitudes and latencies were measured from peak to peak (N1-P1, P1-N2, N2-P2, P2-N3, N3-P3). The Flash VEP waveform in this study started from the first negative peak N1 similar to human protocol (Odom et al., 2010).

The VEP components of the Pomeranians under and over 8 years old had no significant difference (Table 3). Aging in Pomeranians might insignificantly cause mild prolonged latencies and decreased amplitudes. The Flash VEP waveform pattern of the CCD dogs had a similar pattern to that of the normal dogs. The VEP components in the CCD dogs had prolonged latencies of P2 ($p < 0.05$) and P3 ($p < 0.05$) compared to those of the normal aging dogs (Fig 3). Dogs number 9 and 10, which were diagnosed with brain tumor, were excluded from the group of CCD in order to calculate the mean of latency and amplitude. The flash VEP waveform pattern of the dogs with brain tumor were obviously different from the VEP patterns in the normal and CCD dogs (Fig 2). From regression analysis, the equation of P2 was $51.46 + (2.53 \times \text{age})$ and P3 was $154.59 + (3.93 \times \text{age})$. From this equation and the data of mean age - $1.96 \times \text{SD}$ (= 9.33 years) may predict that P2 might be 75.06 msec and P3 might be 191.25 msec for detecting of early CCD (Fig 4).

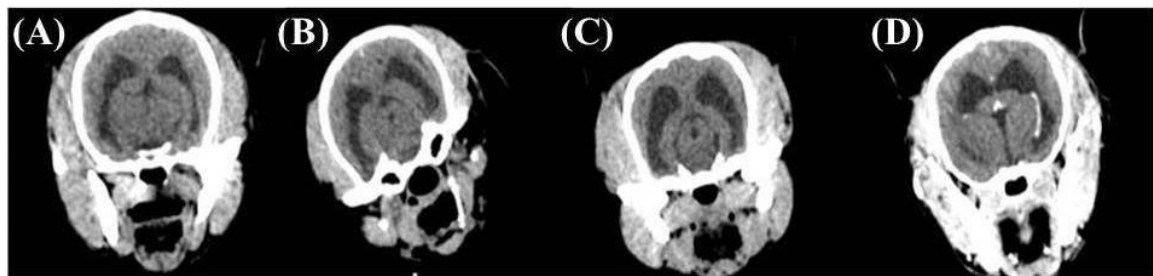


Figure 1 CT scan images showing brain atrophy from mild to severe (from A to C) and brain tumor (D); note the leptomeningeal contrast enhancement and periventricular contrast enhancement

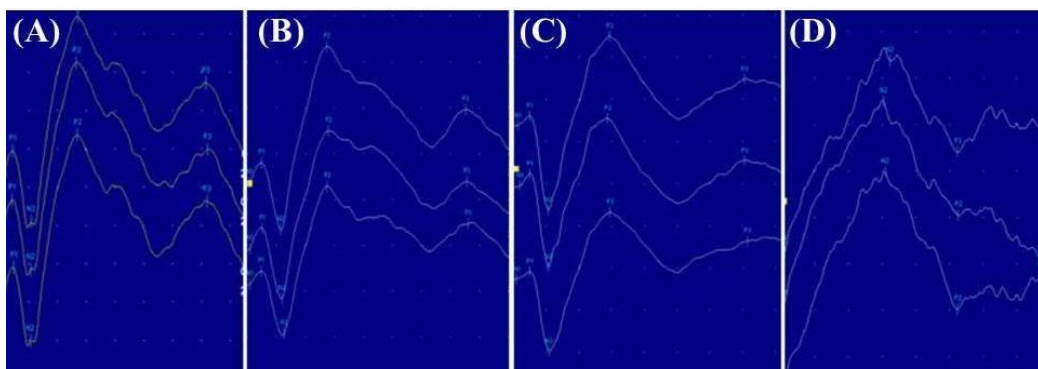


Figure 2 Waveforms of flash VEPs (invert form) in: a normal dog under 8 years old (A), a normal dog over 8 years old (B), a dog with CCD (C) and a dog with brain tumor (D)

Table 1 Clinical signs of CCD from DISHA questionnaire

Dog number	Sign	Sex	Age	Diagnosis
1	Decreased recognition of family and pets/ decreased playing/ increased day time sleeping	Male	14	Mild CCD
2	Decreased recognition of family and pets/ increased reaction to auditory and visual stimuli/ increased day time sleeping/ licking air	Male	14	Mild CCD
3	Decreased recognition of family and pets/ decreased playing/ increased day time sleeping	Male	16	Mild CCD
4	Decreased recognition of family and pets/ decreased playing/ increased day time sleeping	Female	12	Mild CCD
5	Decreased socialization/ decreased response to commands/ altered relationship with people/ eliminate in sleeping area	Male	15	Mild CCD
6	Decreased socialization/ decreased response to commands/ altered relationship with people/ decreased signaling/ increased appetite	Female	15	Mild CCD
7	Decreased greeting behavior/ food dropping/ aimless wandering/ separate anxiety/ walking at night/ separation/ decreased response to familiar commands	Male	12	Moderate CCD
8	Increased day time sleeping/ walking at night/ aimless wandering/ decreased greeting behavior/ separation/ decreased response to commands	Male	11	Moderate CCD
9	Decreased recognition of familiar people/ getting struck/ decreased response to auditory and visual stimuli/ avoiding contact/ altered relationship with people/ walking at night/ aimless wandering/ decreased play/ vocalization/ separation/ decreased response to familiar commands	male	14	Brain Tumor
10	Decreased recognition of familiar people/ getting struck/ avoiding contact/ altered relationship with people/ walking at night/ aimless wandering/ decreased playing/ vocalization/ separation/ decreased response to familiar commands	male	11	Brain Tumor

Table 2 CSF analysis result from dogs diagnosed with brain tumor (*TNCC: total nucleated cell count)

Dog number	TNCC*(cell)	CSF protein (g/dL)	Cytological findings
9	13	28	Some lymphocyte and scattered macrophages, cluster of plexus cells effected by cell degenerative change
10	37	36	Some neutrophils, lymphocytes, macrophages, fat eating macrophages and myelin figure; large lymphoid cell

Table 3 Average (SD) latencies and amplitudes of normal dogs under 8 years old, normal dogs over 8 years old and CCD dogs

Group	Latency (msec)						Amplitude (microvolt)			
	N1	P1	N2	P2	N3	P3	P1-N2	N2-P2	P2-N3	N3-P3
<=8 year	1.85 (1.46)	11.89 (1.80)	28.89 (2.08)	59.89 (8.49)	118.70 (8.43)	177.00 (11.01)	9.30 (6.67)	21.80 (3.73)	15.90 (8.13)	12.50 (3.71)
>8 year	1.81 (1.04)	11.89 (2.04)	31.18 (3.26)	66.52 (8.28)	119.71 (11.75)	173.85 (18.09)	9.10 (5.34)	27.50 (15.29)	33.20 (15.36)	9.50 (8.01)
CCD	2.87 (2.03)	18.21 (5.62)	44.54 (14.34)	100.92* (35.70)	164.32 (41.88)	224.37* (18.20)	7.78 (6.56)	31.90 (16.60)	22.60 (11.19)	9.70 (6.25)

* represents significant difference ($p < 0.05$, Tukey post hoc comparison).

Discussion

A previous study in dogs reported that the first peak was the positive peak (P1) and the first negative peak (N1) was labeled after P1 (Strain et al., 1999). In that study, VEPS were recorded after flash stimulation for 15 msec. The first negative peak (N1) latencies normally were 6-9 msec after stimuli. In contrast, this study recorded VEPS after the flash stimulation for 5 msec. Because this study could detect the negative peak first, N1 was used as the first peak.

However, in several human studies, N1 was reported as the first negative peak of the waveform which appeared prior to other peaks. In addition, N1 has been described as the retinal potential response which is important for evaluation of visual pathway (Celesia, 1998). Due to the capability to identify the negative peak prior to the positive P1 peak, we decided to follow the human pattern of the waveform by labeling the negative N1 prior to the positive P1 peak.

As the same physiology of vision, the flash VEP waveform pattern of dogs had the same pattern as

human waveform. However, both latencies and amplitudes of VEP components of these two species are different. The reason is that VEP parameters are influenced by skull sizes and shapes (Gegori et al., 2006). The use of human pattern and nomenclature should be of benefit to further studies of CCD as a model for human dementia.

In the present study, the flash VEPs were effective to differentiate CCD from tumor by different patterns of waveform. Moreover, the latency of P3 showed high potential for identifying CCD in Pomeranian dogs at least until the age of 15. The latency of P2 was also different between the normal and CCD dogs, but it had less potential than the latency of P3. Twenty percent (2/10) of the dogs with CCD signs from the modified DISHA questionnaire were not eventually diagnosed with CCD. Using only DISHA questionnaire could mislead the diagnosis of brain tumor in some patients. CT scan and CSF analysis

could provide further diagnosis of other intracranial problems. However, an early stage of brain tumor or even CCD might affect only their functions before structural change was noticeable and some structural change might not affect the clinical signs. In addition, meningeal calcification might be difficult to differentiate from meningeal tumor in some patients (Borras et al., 1999). Therefore, using VEP, which is a quick and noninvasive technique, would be useful to increase the accuracy for differentiation of CCD and other intracranial abnormalities such as tumor. Using VEPs for the diagnosis of an early stage of CCD may be beneficial for prolonged or return of the quality of life. Moreover, in a human study, the latency of P3 was found to correlate with clinical sign and stage of AD (Orwin et al., 1986). Using flash VEPs may be a useful technique to evaluate and follow the progression of CCD.

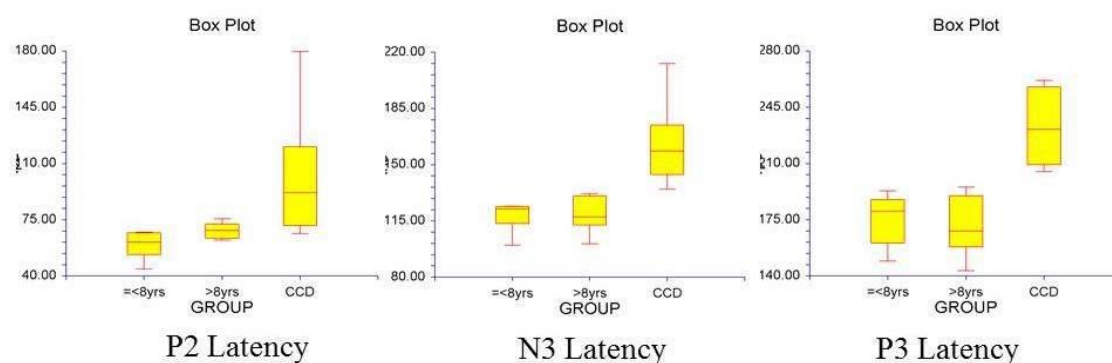


Figure 3 Box plots of average latency P2, N3 and P3 in 3 groups of dogs

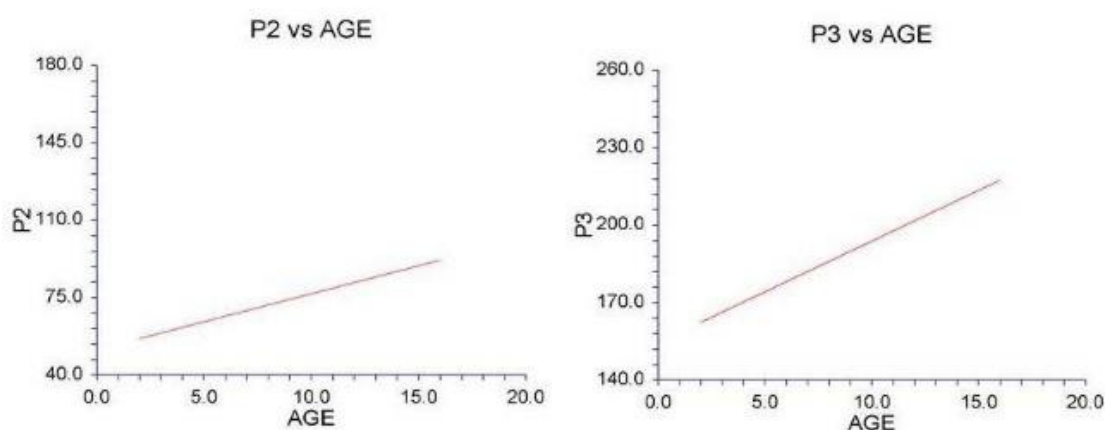


Figure 4 Regressive analysis of P2 and P3

In contrast, a previous study of Kimotsuki et al. (2006) stated that dogs at 9 years of age had latency of P2 and latter peaks more prolonged than dogs under 9 years. The breeds of dog might be a reason for this difference. Pomeranian is a small breed which usually has longer lifespan than the medium and large breeds. In addition, the differences in skull size and shape could affect the latency and amplitude of flash VEP waveform (Gegori et al., 2006). Due to the difference in the skull size and lifespan, VEPs of individual breed

should be clarified for normal reference including the aging process.

In conclusion, VEPs of individual breed should be evaluated for a normal reference. Flash VEPs is a promising tool for the differentiation of CCD and brain tumor. VEPs for CCD might be a useful model for the study of human dementia.

Acknowledgements

The authors would like to thank Center for Agricultural Biotechnology, Kasetsart University and Center for Agricultural Biotechnology: (AG-BIO/PERDO-CHE) for financially supporting part of this study.

References

- Bekker A and Jorden VSB 2004. Alpha-2 agonists in neuroanesthesia. *Seminars in anesthesia, perioperative medicine and pain*. 23(3):181-191.
- Borras D, Ferrer I and Pulmolla M 1999. Age-related changes in the brain of the dog. *Vet Pathol*. 36:202-211.
- Celesia GG 1988. Anatomy and physiology of visual evoked potential and electroretinograms. *Neurol Clin*. 6(4):657-679.
- Coburn KL, Arruda JE, Estes KM and Amoss RT 2003. Diagnostic utility of visual evoked potential change in Alzheimer's disease. *J Neuropsychiatry Clin Neurosci*. 15(2):175-179.
- Cummings BJ, Head E, Ruehl W, Milgram NW and Cotman CW 1996. The canine as an animal model of human aging and dementia. *Neurobiol Aging*. 17(2):259-268.
- Ekesten B 2007. Ophthalmic examination and diagnosis part 4: electrodiagnostic evaluation of vision. In: *Veterinary Ophthalmology*. 4th ed. KN Gelatt (ed) Iowa: Blackwell Publishing. 520-535.
- Gegori B, Pro S, Bombelli F and Narucia M 2006. VEP Latency: sex and head size. *Clin Neurophysiol*. 117(5):1154-1157.
- Head E and Zicker SC 2004. Nutraceutical, aging, and cognitive dysfunction. *Vet Clin North Am Small Anim Pract*. 34: 217-228.
- Head E, Barabas S and Craze PG 2007. Nutritional supplement in case of canine cognitive dysfunction-A clinical trial. *Appl Anim Behav Sci*. 105:284-296.
- Head E, Rofina J and Zicker S 2008. Oxidative stress, aging and central nervous system disease in the canine model of human brain aging. *Vet Clin of North Am Small Anim Pract*. 38(1): 167-178.
- Kimotsuki T, Yasuda M, Tamahara S, Matsuki N and Ono K 2005. Topographic analysis of flash visual evoked potentials in dogs. *J Vet Med Sci*. 67(9):869-875.
- Kimotsuki T, Yasuda M, Tamahara S, Tomihari M, Matsuki N and Ono K 2006. Age-associated change of flash visual evoked potentials in dog. *J Vet Med Sci*. 68(1):79-82.
- Landsberg GM 2002. Behavior and brain aging. Symposium on brain aging and related behavior changes in dogs. Hill's Pet Nutrition, Inc: 23-26.
- Landsberg GM, Nichol J and Araujo JA 2012. Cognitive dysfunction syndrome a disease of canine and feline brain aging. *Vet Clin Small Anim*. 42:749-768.
- Odom JV, Bach M, Mitchell Brigell, Holder GE, McCulloch DL, Tormene AP and Vaegan 2010. ISCEV standard for clinical visual evoked potentials. *Doc Ophthalmol* 120:111-119.
- Orwin A, Wright CE, Harding GFA, Rowan DC and Rolfe EB 1986. Serial visual evoked potential recording in Alzheimer's disease. *Br Med J*. 293: 9-10.
- Osella MC, Re G, Odore R, Giardi C, Babino P, Barbero R and Barganaco U 2007. Canine cognitive dysfunction syndrome: prevalence, clinical signs and treatment with neuroprotective nutraceutical. *Appl Anim Behav Sci*. 105(4):297-310.
- Pineda S, Olivares A, Mas B and Ibanez M 2014. Cognitive dysfunction syndrome: updated behavioral and clinical evaluations as a tool to evaluate the well-being of aging dogs. *Arch Med Vet*. 46: 1-12.
- Salvin HE, McGreevy PD, Sachdev PS and Valenzuela MJ 2010. Under diagnosis of canine cognitive dysfunction: A cross-sectional survey of older companion dogs. *Vet J*. 184(3):277-281.
- Shull EA 2002. Neurologic disorders in aged dogs. Symposium on brain aging and related behavior changes in dogs. Hill's Pet Nutrition, Inc: 17-19.
- Strain GM, Jackson RM and Tedford BL 1990. Visual evoked potentials in the clinically normal dog. *J Vet Intern Med*. 4(4):223-225.
- Tartaglione A, Spadavecchia L, Maculotti M and Bandini F 2012. Resting stage in Alzheimer's disease analysis of flash-visual evoked potentials and quantitative EEG. *BMC Neurol*. 12:145.

บทคัดย่อ

การตรวจวินิจฉัยด้วย Flash visual evoked potentials ในสุนัขปอมเมอเรเนียนที่ปกติและที่อยู่ในภาวะความจำเสื่อม

ธนวุฒิ เหมนิลรัตน์^{1,2} เฉลิมพล เล็กเจริญสุข⁴ ปิยทิพย์ ชูเฉลิมพล³ อารีย์ ทยานานุกัทร^{*}

Visual evoked potential (VEP) เป็นเทคนิคการตรวจวินิจฉัยที่มีประโยชน์ในการประเมินการทำงานของเส้นประสาทตาและการวินิจฉัยโรค Alzheimer ในมนุษย์ ภาวะความจำเสื่อมในสุนัขเป็นกลุ่มอาการที่เกี่ยวข้องกับระบบประสาทที่ส่งผลกระทบต่อพฤติกรรมในสุนัขซึ่งสัมพันธ์กับช่วงอายุ สุนัขที่อยู่ในภาวะนี้บางส่วนไม่ได้รับการวินิจฉัย การศึกษานี้ได้ทำการทดสอบด้วยการตรวจ VEP ในสุนัขพันธุ์ปอมเมอเรเนียนทั้งหมด 28 ตัว ประกอบด้วยสุนัขปกติในช่วงอายุระหว่าง 1-8 ปีจำนวน 9 ตัว สุนัขปกติช่วงอายุ 8 ปีขึ้นไปจำนวน 9 ตัว และสุนัขที่แสดงอาการภาวะความจำเสื่อมจำนวน 10 ตัว สุนัข 8 ใน 10 ตัวนี้พบภาวะสมองฝ่อสืบจากการวินิจฉัยด้วยภาพ CT scan และ 2 ใน 10 ตัวตรวจพบเนื้องอกในสมองซึ่งยืนยันโดยภาพ CT scan และการตรวจน้ำไขสันหลัง ลักษณะของคลื่นไฟฟ้า VEP ในกลุ่มสุนัขปกติอายุ 1- 8 ปีและกลุ่มอายุมากกว่า 8 ปีไม่ได้มีความแตกต่างกันอย่างมีนัยสำคัญ ($p>0.05$) แต่องค์ประกอบของคลื่นไฟฟ้า VEP ในส่วน P2 และ P3 มีช่วงยาวขึ้นในสุนัขที่มีภาวะความจำเสื่อมเมื่อเทียบกับสุนัขปกติอย่างมีนัยสำคัญ ($p<0.05$) รูปแบบของคลื่นไฟฟ้า VEP ในสุนัขที่มีภาวะความจำเสื่อมแตกต่างจากสุนัขที่มีเนื้องอกในสมอง สรุปได้ว่า VEP เป็นเทคนิคที่น่าเชื่อถือในการตรวจวินิจฉัยภาวะความจำเสื่อมในสุนัขสูงอายุ

คำสำคัญ: สมองฝ่อสืบ ภาวะความจำเสื่อม สุนัข สุนัขปอมเมอเรเนียน visual evoked potential

¹ศูนย์เทคโนโลยีชีวภาพเกษตร มหาวิทยาลัยเกษตรศาสตร์ วิทยาเขตกำแพงแสน จ.นครปฐม 73140

²ศูนย์ความเป็นเลิศด้านเทคโนโลยีชีวภาพเกษตร สำนักพัฒนาบัณฑิตศึกษาและวิจัยด้านวิทยาศาสตร์และเทคโนโลยี สำนักงานคณะกรรมการการอุดมศึกษา กรุงเทพฯ 10900

³โรงพยาบาลสัตว์เพื่อการเรียนการสอน คณะสัตวแพทยศาสตร์ มหาวิทยาลัยเกษตรศาสตร์ วิทยาเขตบางเขน กรุงเทพฯ 10900

⁴ภาควิชาเวชศาสตร์คลินิกสัตว์เลี้ยง คณะสัตวแพทยศาสตร์ มหาวิทยาลัยเกษตรศาสตร์ วิทยาเขตกำแพงแสน จ.นครปฐม 73140

^{*}ผู้รับผิดชอบบทความ E-mail: fvetatn@ku.ac.th