

ECG Quiz

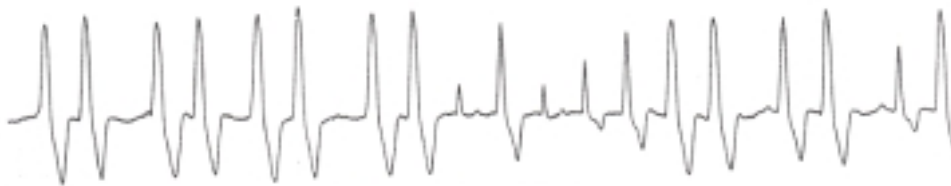
Chollada Buranakarl* Kris Angkanaporn*

Strip A



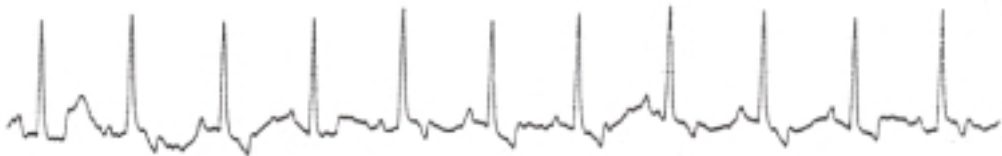
Calibration 0.5 cm/mV

Strip B



Calibration 0.5 cm/mV

Strip C



Calibration 1.0 cm/mV

The paper speed is 25 mm/sec

A 13 year-old Bouvier des Flanders dog weighing 33 kg, with a history of chronic weakness of both hindlimbs, was presented to a veterinary hospital. Physical examination revealed a subcutaneous mass near the left thorax behind the left limb. The mass was removed after the dog was sedated with acepromazine and given local analgesic injection. Atropine

was also given as a premedication. The hematologic values and plasma electrolytes (Na, K and Cl) were within normal limits. The dog showed sign of panting 15 hrs later. An electrocardiogram was recorded and complex lead II strip is shown as strip A. The ECG was repeated two days later (strip B) and also 12 days after the second recording. (strip C)

Please make your interpretation and turn to the next page

Answer

- Strip A** Ventricular tachycardia
Strip B Multiform ventricular tachycardia
Strip C Normal sinus rhythm

The heart rate was 170 beats/min at the first recording (strip A). Please notice the shape of the ECG complexes which is resemble between each other and may indicate the ectopic foci originate from the same location. The rapid heart rate, regular rhythm with no fixed relationship to visible P waves and the bizarre QRS complexes, support the diagnosis of ventricular tachycardia. The electrical impulse does not travel through the specialized conduction system but through ordinary muscle which caused a delay. The morphology of the wide QRS complexes helps to eliminate the diagnostic possibility that it is supraventricular in origin. Strip B shows the complexes that are different in amplitude.

The ventricular tachycardia is classified as multiform because of the varying configuration of ventricular ectopic complexes. The last strip (strip C) shows a normal ECG waveform although the baseline is not stable. The amplitude and shape of QRS are normal since the impulse travels through the normal conducting pathway.

Bolus injections of lidocaine are required to convert ventricular tachycardia to a normal sinus rhythm. Maintenance therapy with procainamide, given orally, with or without propranolol, can be used successfully. In this case, the treatment was not required since ventricular tachycardia resolved itself. The arrhythmia may have been due to hypotension caused by the sedative drug given during the operation to a geriatric dog. However, other possible causes need to be ruled out, including myocarditis, trauma, congenital defects and toxicity. Thoracic radiographs, biochemistry blood profiles and an echocardiogram may be necessary if the condition persists.