

รายงานสัตว์ป่วย : การตรวจการติดเชื้อเฮอร์ปีส์ไวรัส ที่ทำให้เกิดการแท้งในลูกม้าโดยเทคนิคอิมมูโนฮิสโตเคมี

นพดล พิพารัตน์* วิจิตร เกียรติพัฒนสกุล* ชีรวัฒน์ ธาราสนิต**
ปัทมา ฤทธิฤชัย** ยุมิ อุเนะ*** ยาซุโอะ โนมูระ***

Abstract

Nopadon Pirarat* Wjit Kiatipattanasakul* Theerawat Tharasanit**
Pattama Rittruechai** Umi Une*** Yasuo Nomura***

THE DETECTION OF EQUINE HERPESVIRUS ANTIGEN IN AN ABORTED FOAL USING IMMUNOHISTOCHEMISTRY : A CASE REPORT

Formalin fixed tissues from an aborted foal which had been diagnosed as having Equine Herpesvirus (EHV) infection, on histopathological criteria, were examined for EHV antigen using immunohistochemistry. EHV antigen was found in the focal necrotic area of the liver, especially in hepatocytes and Kupffer cells. Intranuclear and intracytoplasmic, immuno-positive labelings were also prominent in bronchiolar epithelial cells. The method allowed the visualization of the antigenic site distribution and their subsequent correlation with histopathological changes.

Keywords : foal, Herpesvirus, histopathology, immunohistochemistry

*Department of Veterinary Pathology

** Department of Obstetrics Gynecology and Reproduction, Chulalongkorn University, Bangkok 10330 Thailand.

***Department of Veterinary Pathology, Azabu University, Kanagawa 229-0006 Japan.

*ภาควิชาพยาธิวิทยา

**ภาควิชาสูติศาสตร์ เภสัชเวชวิทยา และวิทยาการสืบพันธุ์ จุฬาลงกรณ์มหาวิทยาลัย กรุงเทพฯ 10330

***ภาควิชาพยาธิวิทยาทางสัตว์แพทย์ มหาวิทยาลัยอะซะฮะบุ คานากาวา 229-0006 ประเทศญี่ปุ่น

บทคัดย่อ

นพดล พิพารัตน์* วิจิตร เกียรติพัฒนสกุล* ชีรวัฒน์ ธาราตานิต**

ปัทมา อรุณรัชชัย** ยุมิ อุเนะ*** ยาซุโอะ โนมูระ***

รายงานสัตว์ป่วย : การตรวจการติดเชื้อเฮอร์ปีส์ไวรัสที่ทำให้เกิดการแท้งในลูกม้าโดยเทคนิคอิมมูโนฮิสโตเคมี

ทำการตรวจการติดเชื้อเฮอร์ปีส์ไวรัสในลูกม้าที่แท้งด้วยวิธีการทางจุลพยาธิวิทยา ร่วมกับการใช้อิมมูโนฮิสโตเคมีเพื่อตรวจหาแอนติเจนในชิ้นเนื้อที่ฝังในพาราฟิน ผลการศึกษาพบแอนติเจนของเฮอร์ปีส์ไวรัส บริเวณเนื้อตายของตัว โดยเฉพาะเซลล์ตัว คัพเฟอร์เซลล์ และเซลล์เยื่อบุทางเดินหายใจในปอด ทั้งในนิวเคลียสและไซโตพลาสซึม จากวิธีการตรวจดังกล่าวทำให้สามารถทราบถึงตำแหน่งหรือเซลล์เป้าหมายที่ติดเชื้อไวรัส ลักษณะการกระจายตัวของเชื้อไวรัส ซึ่งมีความสัมพันธ์กับลักษณะรอยโรคทางจุลพยาธิวิทยา

คำสำคัญ : ลูกม้า เฮอร์ปีส์ไวรัส จุลพยาธิวิทยา อิมมูโนฮิสโตเคมี

Introduction

Abortion is an embryonic or foetal loss at any point between recognizable pregnancy and parturition. It is an important factor in the overall problem of reproductive failure. Horses suffer a higher incidence of foetal loss than other domestic species, affecting between 5-15% of pregnancies, especially in older mares (Patrick et al., 1991). Many potentially pathogenic organisms, such as viruses, bacteria or fungi, can contaminate the uterus during breeding and foaling. If remnants of these organisms remain after conception, they can cause endometritis, placentitis and subsequent abortion. Common viral causes of abortion are Equine Herpesvirus-1 (EHV-1), Equine Viral Arteritis (EVA) and occasionally Equine Herpesvirus-4 (EHV-4).

EHV-1 is an α -herpes virus and important cause of neonatal death, abortion, respiratory problems and debilitating neurological diseases (Sutton et al., 1998). As this infectious agent spreads through a herd, it can infect pregnant mares and cross the placenta to infect the foetus, sometimes resulting in abortion. Field studies have shown that 95% of EHV-1 abortions occur in the last 4 months of gestation (Machida et al., 1996). Immunity stimulated by natural infection or vaccination, is generally short-lived. Consequently, horses may suffer from repeated infections resulting in serious economic loss (Maanen et al., 2000).

The purpose of this study was to detect equine herpesvirus in an aborted foal using an immuno-histochemical method.

Materials and methods

Histopathology

Formalin-fixed tissues from an aborted foal born to a 13-year-old mare were submitted to the Department of Veterinary Pathology, Faculty of Veterinary Science, Chulalongkorn University. The history of mare revealed poor conception rate and no vaccination against EHV-1. The abortion had occurred in the last 4 months of gestation with no prior clinical symptoms. The aborted foetus was slipped with little effort and was followed immediately after by the placenta. The sample were taken, fixed in formalin and sliced into 0.5 cm. thick, serial sections, routinely histopathologically processed and embedded in paraffin wax. The blocks were sectioned 4 μ m. thick and stained with hematoxylin and eosin (H&E) for microscopic examination.

Immunohistochemistry

Four μ m formalin-fixed paraffin sections of liver and lung on 3-aminopropylene-coated slides were used for immunohistochemistry. Sections were deparaffinized, rehydrated by immersion in xylene, graded alcohols and distilled de-ionized water and placed in a phosphate buffer saline solution (PBS). Endogenous peroxidase activity was blocked using 0.2% hydrogen peroxide at room temperature for 30 minutes (mins), washing with PBS for 15 mins. and incubating with 10% skimmed milk for 20 mins. in order to block non-specific reactions. Sections were incubated with polyclonal rabbit antibody against EHV-1 (HH-1 strain, 1:100 dilution, courtesy of Dr. K. Tsuchiya) in PBS at 4°C

overnight. After another rinse in PBS, sections were consecutively incubated with peroxidase conjugated 2nd antibody polymer (Nichirei, Japan) at 37°C for 30 mins. The sections were developed to show a brown colour, in 3-amino-9-benzidine (DAB) solution, for 1-2 mins. and counter-stained with Harris hematoxylin. Sections were dehydrated and observed by microscopy. Tissues of liver and lung from an EHV-1 negative aborted foetus and non-immune serum from EHV-1 negative horses were used as negative controls.

Results

Histopathology

Lung histopathologically revealed interstitial pneumonia, bronchial and alveolar epithelial cell necrosis with homogeneous eosinophilic intranuclear inclusion bodies in both the intact and degenerated bronchial and alveolar epithelial cells (Fig. 1). There was hyperplasia of pneumocytes type II, severe lung congestion, interseptal and perivascular oedema, hyaline membrane formation and fluid-filled alveoli. The liver showed severe fatty degeneration, multifocal necrosis (Fig. 2) with homogeneous pale eosinophilic intranuclear inclusion bodies in the hepatocytes (Fig. 3) and Kupffer cells.

Immunohistochemistry

Staining revealed strongly positive EHV antigen in both the nuclei and the cytoplasm of intact and degenerated bronchial and alveolar epithelial cells (Fig. 4), the alveolar macrophages as well as the necrotic debris in the bronchial lumen and occasionally in endothelial cells. The liver showed

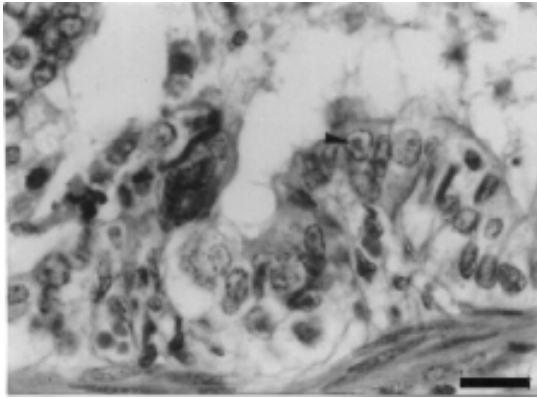


Figure 1. Bronchial, epithelial cell necrosis with homogeneous eosinophilic, intranuclear inclusion bodies (arrow head, H&E, bar = 25 μ m.)

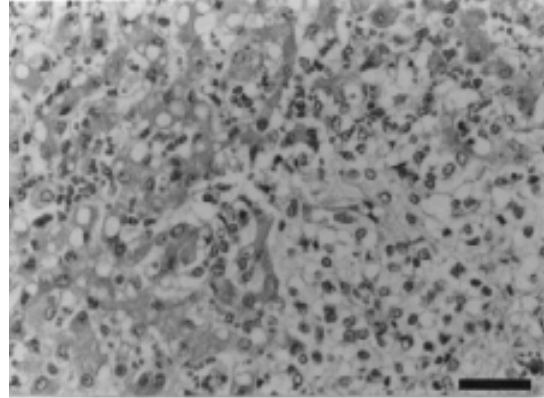


Figure 2. Severe vacuolar, fatty degeneration with multifocal, coagulative necrosis of liver (H&E, bar = 50 μ m.)

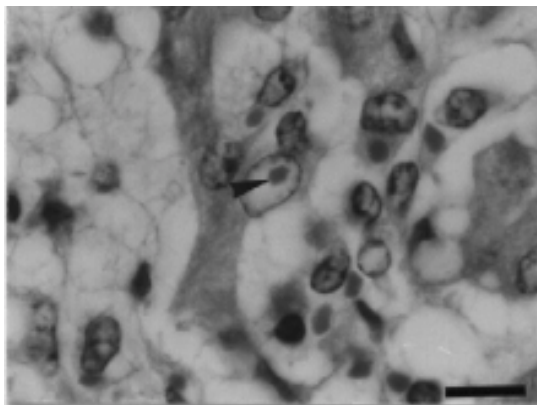


Figure 3. Focal necrosis with homogeneous, pale, eosinophilic, intranuclear inclusion bodies in the hepatocytes. (arrow head, H&E, bar = 15 μ m.)

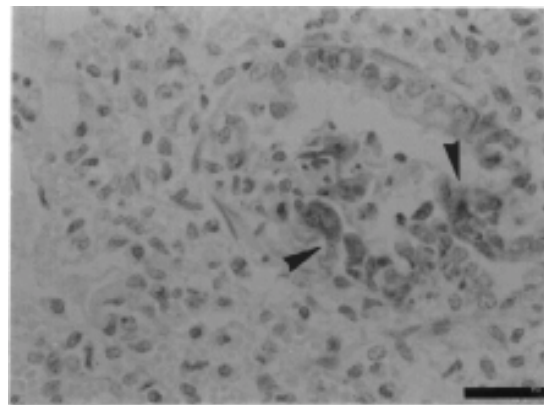


Figure 4. EHV antigen positive in both the nuclei and the cytoplasm of intact and degenerated bronchial and alveolar epithelial cells (arrow head, IHC, bar = 50 μ m.)

positive EHV antigen in degenerated hepatocytes located in the necrotic area.

Discussion

In this study, we had diagnosed EHV abortion base on typical histopathological changes and IHC labeling of viral antigen. The polyclonal antibody used in this study could not distinguish EHV-1 from EHV-4 but the strong positive reaction to EHV antigen confirmed this aborted foetus was truly infected. The presence of EHV-1 antigen within several cell types such as endothelium, epithelium and macrophages indicated its cellular polytropism. The inflammation associated with the vascular lesions was mostly comprised of T-lymphocytes and macrophages. T- lymphocytes may have a significant cytotoxic effect on EHV-1 infected cells, contributing to the severity of cytolysis within the vascular lesion. This cytolytic activity may be mediated by major histocompatibility complex class I-restricted CD8⁺ T cells. The small amounts of EHV-1 antigen in the pulmonary vessels in this case might be possibly due to the phase of the infection when endothelial viral replication was at it's peak and it's consequent cytopathic effects which had already occurred (Del Piero et al., 2000). Vascular injury associated with platelet aggregation in thrombosis is known to cause the local release of vasoactive substances such as serotonin, thromboxanes and prostaglandins. Such prostaglandin release as a result of uterine viral thrombosis in late pregnancy may play an important role in EHV-1 abortion (Smith et al., 1996).

Routine diagnostic methods to confirm EHV-1 infection include viral isolation or direct fluorescent antibody tests to detect the viral antigen in fresh foetal tissues. These techniques sometimes fail to confirm the presence of EHV-1, even in cases where the clinical history, pathologic lesions, and maternal serum antibodies titres to EHV-1 are highly suggestive of infection. Diagnosis of EHV-1 abortion can be performed on the basis of both serological and histopathological examinations. Serological tests are difficult to interpret as almost every adult horse possesses antibody for EHV-1. Furthermore, the infection may precede abortion by several weeks.

Immunohistochemical methods for detecting antigens in formalin-fixed tissues are very useful in a diagnostic laboratory. The method is rapid, inexpensive, sensitive and allows visualization of the sites of antigen distribution allowing correlation with histopathological changes (Jonsson et al., 1989; Rimstad and Evensen, 1993). The use of formalin-fixed tissues simplifies sample submission and provides an opportunity for conducting retrospective studies on archival specimens.

Acknowledgements

We would like to thank Dr. Tsuchiya Kataro, Nippon Institute of Biological Science, Japan for kindly providing EHV-1 antibody and Pathology laboratory, Azabu University, Kanagawa, Japan for laboratory facilities.

References

- Del Piero, F., Wilkins, P.A., Timoney, P.J., Kadushin, J., Vogelbacker, H., Lee, W.J., Berkowitz, S.J. and La Perle, K.M.D. 2000. Fatal Nonneurological EHV-1 Infection in a yearling filly. *Vet. Pathol.* 37: 672-676.
- Jonsson, L., Beck-Friis, J., Renstrom, L.H.M., Nikkila, T. P. and Sundquist, B. 1989. Equine Herpes Virus 1 (EHV-1) in liver, spleen and lung as demonstrated by immunohistology and electron microscopy. *Acta. Vet. Scand.* 30: 141-146.
- Maanen, V.C., Vreeswijk, J., Moonen, P., Brinkhof, J. and Boer-Luijze, D.E. 2000. Differentiation and genomic and antigenic variation among fetal, respiratory, and neurological isolates from EHV1 and EHV4 infections in the Netherlands. *Vet. Quart.* 22: 88-93.
- Machida, N., Taniguchi, T., Nakamura, T. and Kiryu, K. 1997. Cardio-histopathological observations on aborted equine fetuses infected with equid Herpesvirus 1. *J. Comp. Pathol.* 116: 379-385.
- Parick, T.C., Ian, G.M., Alfred, M.M. and James, N.M. 1991. *Equine Medicine and Surgery*. 4th ed. Vol. II, California: American Veterinary Publication, Inc. 1066-1068.
- Rimstad, E. and Evensen, Q. 1993. The identification of equid herpesvirus 1 in paraffin-embedded tissues from aborted fetuses by polymerase chain reaction and immunohistochemistry. *J. Vet. Diag. Invest.* 5: 174-183.
- Smith, K.C., Mumford, J.A. and Lakhani, K. 1996. A comparison of Equid Herpesvirus-1 (EHV-1) vascular lesions in the early versus late pregnant equine uterus. *J. Comp. Pathol.* 114: 231-247.
- Sutton, G.A., Viel, L., Carman, P.S. and Boag, B.L. 1998. Pathogenesis and clinical signs of equine Herpesvirus-1 in experimentally infected ponies *in vivo*. *Can. J. Vet. Res.* 62: 49-55.