

ULTRASOUND DIAGNOSIS

Phiwipha Kamonrat*

History

A two-year-old, intact, female squirrel was presented at Chulalongkorn University, Small Animal, Veterinary Teaching Hospital showing inappetance after being attacked by a cat four days previously. On palpation, the left cranial abdominal wall appeared painful with a fixed, soft tissue mass, about 2 cm in diameter present. Abdominal radiography revealed an area of increased soft

tissue density in the left cranial part of the abdomen. The abdominal organs were in normal position. At the second visit, five days later, the mass had become larger, about 4 cm in diameter, and hard in consistency. The squirrel was anorexia and had diarrhoea. Ultrasonography of this mass was performed to obtain more specific information.

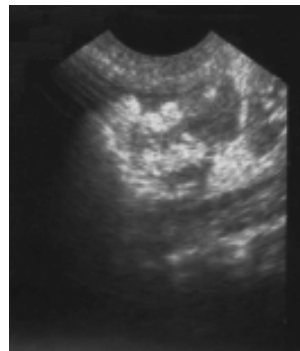

Figure 1 A sagittal ultrasonographic image of the left, cranial, abdominal mass in a two-year-old, female squirrel, in dorsal recumbency. A 2.6 by 3.4 -cm, well-defined mass, with smooth echogenic border, was located in the abdominal wall, just cranial to the left kidney position. There were several large hyperechoic areas within the hypoechoic center.

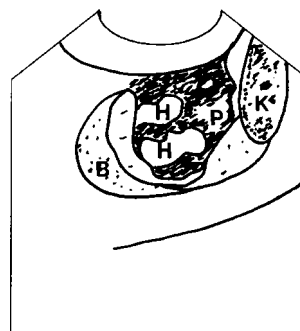


Figure 2 Schematic of the relative position of the structures scanned in Figure 1. B -echogenic border; K -left kidney; H -hyperechoic area; P -hypoechoic center

Ultrasonographic Findings

Ultrasonographic examination of the left, cranial, abdominal mass was performed using a real-time scanner with an 8-5 MHz broadband, convex, phased array transducer. The mass was well-defined, heteroechoic, 2.6 by 3.4 cm in diameter, and located in the abdominal wall, just cranial to the left kidney position (figs 1 and 2). The border of the mass was smooth and echogenic. There were several large hyperechoic areas within the hypoechoic center. This was suggestive of a purulent exudate in its fluid-filled center. Aspiration of the mass confirmed it to be an abscess.

Diagnosis

Ultrasonographic diagnosis—Focal abdominal abscess.

Comments

Ultrasonographic examination of the abdomen is a safe, noninvasive method to identify and evaluate a suspected septic lesion when there are poor in definitive clinical, laboratory, and radiographic details. The sonographic appearance of an abscess is variable (Konde et al., 1986; Mattoon and Nyland, 1995). Intra-abdominal abscesses are typically thick and irregularly-walled and variable in size and number. The center of the mass usually contains hyperechoic debris or gas within the hypoechoic purulent exudate. Distal acoustic enhancement may be either present or absent varying with the viscosity of the exudate and amount of cellular elements.

A deep muscle abscess may, ultrasonographically, appear as a hypoechoic-to-hyperechoic mass, with a thickened wall in a mature abscess and no clear wall in an immature abscess (Hager, 1986). The hypoechoic fluid at the center may contain variable degrees of bright echos from the debris and gas. However, it is not advisable to use only ultrasonography for a definitive diagnosis of an abscess, due to variations in the ultrasonographic patterns of these intra- and extra-abdominal abscesses.

References

- Hager D.A. 1986. The diagnosis of deep muscle abscesses using two-dimensional real time ultrasound. In: Proceedings of the American Association of Equine Practitioners. 523-529.
- Konde L.J., Lebel J.L., Park R.D. and Wrigley R.H. 1986. Sonographic application in the diagnosis of intraabdominal abscess in the dog. *Vet. Radiol.* 27(4): 151-154.
- Mattoon J.S. and Nyland T.G. 1995. Ultrasonography of the General Abdomen. In: *Veterinary Diagnostic Ultrasound*. T.G. Nyland and J.S. Mattoon (eds). Philadelphia: W.B. Saunders Company. 43-51.