

WHAT IS YOUR DIAGNOSIS

Pranee Tuntivanich

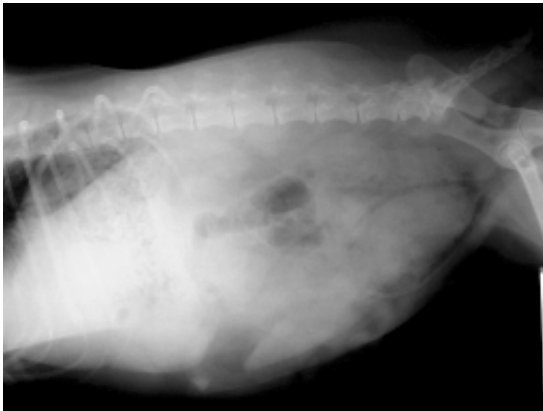


Figure 1 Lateral position of an abdomen of a dog.

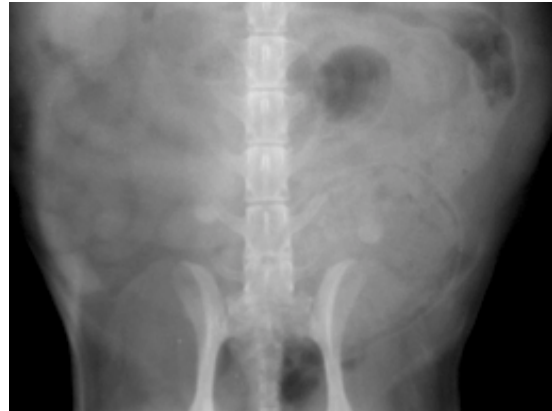

Figure 2 Ventro-dorsal position of the same dog.

History :

A 6 years-old female mixed breed dog was suffering from blood in the urine and occasional vulva bleeding. Pyometra was suspected.

Radiographs were taken in the lateral and ventro-dorsal positions of the abdomen. A pneumocystography was also performed.

Give your diagnosis and turn to page 90.

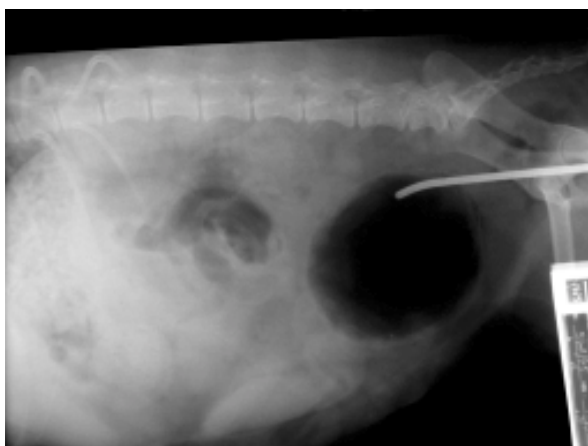


Figure 3 Pneumocystogram of the same dog.

Radiographic Diagnosis

Cystitis.

Radiographic Findings and Comments

The lateral view of an abdomen revealed thickening of the urinary bladder which was filled with urine and gas. A left lateral deviation of the urinary bladder, superimposed on the distal colon which was filled with feces was seen in the ventro-dorsal position.

Pneumocystography revealed a gas filled urinary bladder with thickening of the bladder wall. There was spondylosis between the last lumbar and the first sacral vertebra. There was no evidence of any other abnormalities.

Radiographic changes are not present in cases of acute cystitis. Thickening of the bladder wall usually ranges from 3-4 mm. up to 1-2 cm. Diffuse bladder wall thickening may occur with chronic cystitis and has to be differentiated from neoplasia.