

WHAT IS YOUR DIAGNOSIS

Pranee Tuntivanich

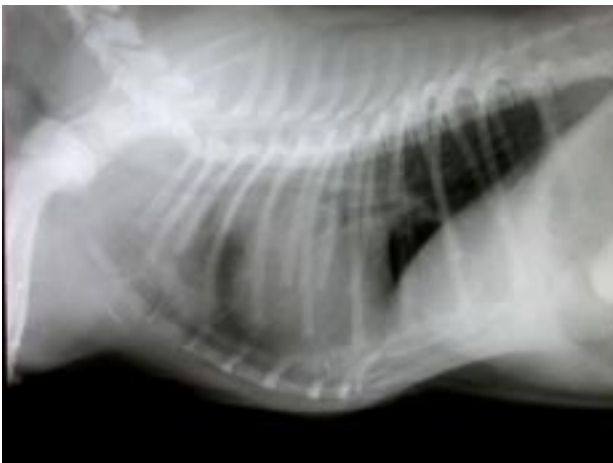


Figure 1 Lateral position of the thorax of a dog.

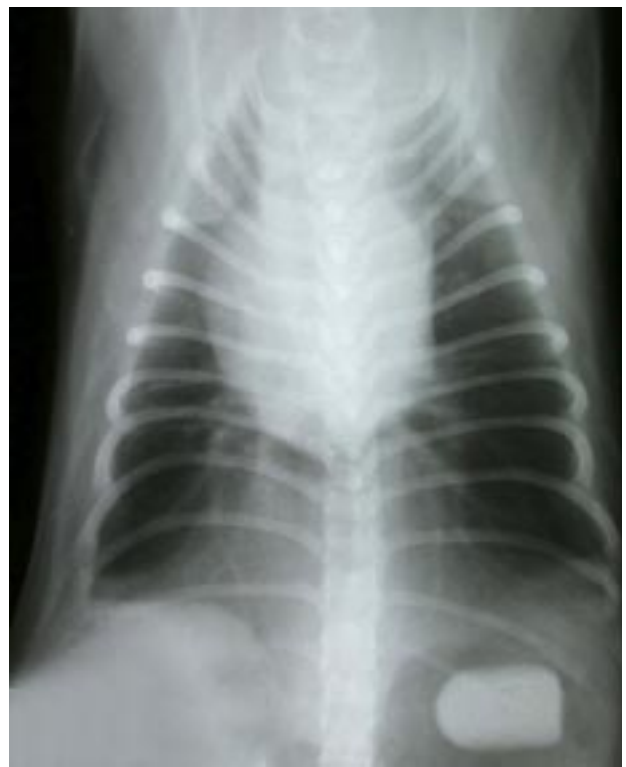

Figure 2 Ventro-dorsal position of the thorax of the same dog.

History :

A six-month-old male Pug was presented with symptoms of anorexia, respiration sounds similar to the obstruction of an air way and a serous nasal discharge.

Radiographs were taken in both the lateral and the ventro-dorsal positions.

Give your diagnosis and turn to page 90.

Radiographic Diagnosis

Trachial collapse.

An opaque foreign body in the stomach.

Radiographic Findings and Comments

The lateral radiograph of the thorax reveals a narrowing of the lumen of the trachea along the cervical and thoracic parts. The heart is displaced dorsally due to a sternal deformity and a soft dense tissue is seen between

the heart and the sternum. There is an opaque foreign body in the stomach.

The tracheal diameter varies slightly from breed to breed. Most tracheal problem are dynamic in nature, resulting in a variation in tracheal size and related to the phase of the respiratory cycle. This variation is most often seen in toy dog breeds because of a weakness in the structural rigidity of the trachea.