

WHAT IS YOUR DIAGNOSIS

Pranee Tuntivanich

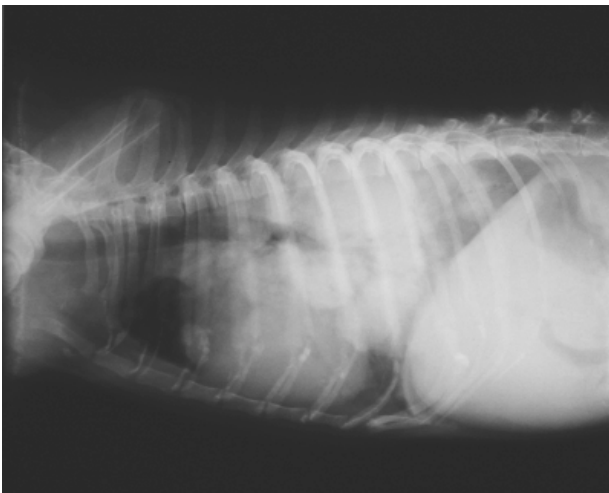


Figure 1 Lateral position of the thorax of a 13 year old dog.

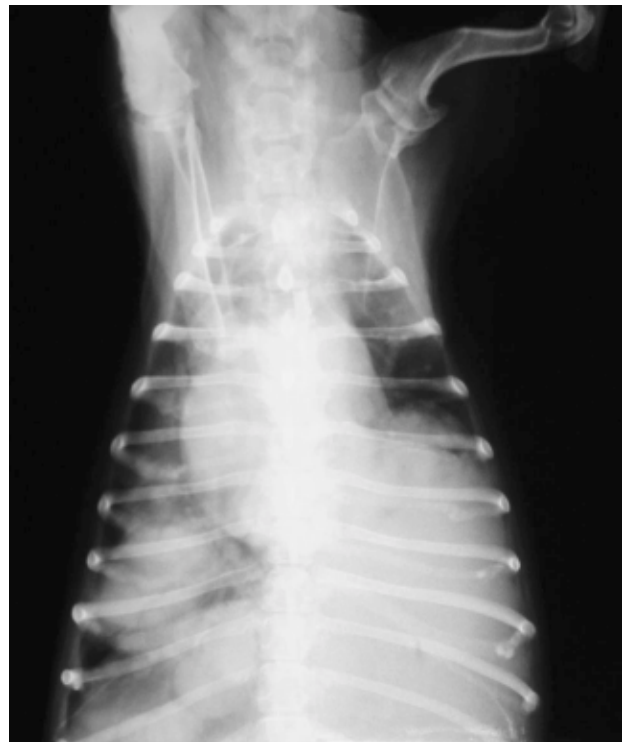

Figure 2 Ventro-dorsal position of the same dog.

History :

A 13 years old female Shihtzu dog was presented with atypical lung sounds and a nasal secretion. The dog has received surgery on a mammary gland tumor in 1999.

Radiographs were taken in the lateral and ventro-dorsal positions.

Give your diagnosis and turn to page 126.

Radiographic Diagnosis

Thoracic masses.

Radiographic Findings and Comments

There are multiple masses in the lung field. Three masses in the right and one in the left diaphragmatic lobe, presented in the dorso-ventral view. The diameter of the right hand masses are about 2 inches while the left one is about 3.5 inches. Calcification of the costochondral junction is seen in the lateral view and is normally found in a 13 year old dog.

A tumour of the lung can originate as a primary tumor. It can also be secondary originating from any elsewhere in the body. A secondary tumor or metastatic tumor, is usually presented as a multiple small or miliary tumor, spread over all the lung. However, as this dog had a history of a mammary gland tumor surgery in 1999, the mammary gland should be suspected as the origin of a secondary tumor in the lung of this dog.