

IMMUNOHISTOCHEMICAL STUDIES OF THE ESTROGEN RECEPTOR ALPHA IN THE OVARIES AND UTERI OF THE DOMESTIC CAT AT DIFFERENT STAGES OF THE OESTROUS CYCLE

Damri Darawiroj* Kongkiat Srisuwatanasagul Sinchai Pianchop Sayamon Sukjumlong

Abstract

Damri Darawiroj* Kongkiat Srisuwatanasagul Sinchai Pianchop Sayamon Sukjumlong

IMMUNOHISTOCHEMICAL STUDIES OF THE ESTROGEN RECEPTOR ALPHA IN THE OVARIES AND UTERI OF THE DOMESTIC CAT AT DIFFERENT STAGES OF THE OESTROUS CYCLE

The expression of the estrogen receptor alpha ($ER\alpha$) was investigated in domestic cat ovaries and uteri by mean of immunohistochemistry, using monoclonal antibody against $ER\alpha$. The stages of the oestrous cycle were determined by vaginal cytology and serum steroid levels which were taken before operation. In the uterus, positive staining was found in the nuclei of all uterine cell types in different proportions and staining intensity. During oestrous, the staining intensity and the proportion of positive cells were highest in the epithelium (both the surface epithelium and the glandular epithelium) as well as in the myometrium. At dioestrous, $ER\alpha$ expression was clearly low in the surface epithelium and myometrium but not in the germinal epithelium. During anoestrous, weak staining as well as low proportion of positive cells was observed in most of the compartments of the uterus, apart from the stroma, the proportion and the intensity of positive cells was not markedly different during all stages of the oestrous cycle. In the ovary, positive staining was only found in some ovarian cells. During oestrous, strong staining was seen in the germinal epithelium and in the stroma of the ovaries. Additionally, faint staining was also observed in some luteal cells. However, no positive staining of Era was detected in other ovarian samples collected at the other stages.

In conclusion, the study showed that estrogen elicits its function mainly via $ER\alpha$ in all uterine cell types. In the ovary, the observation that not all ovarian cell types express $ER\alpha$ could suggest that the estrogen receptor, subtype alpha, is neither the major nor the only protein that causes estrogen to elicit its effect the role of the estrogen receptor, subtype beta ($ER\beta$), should be further clarified in this respect.

Keywords : immunohistochemistry, estrogen receptor, ovary, uterus

Department of Anatomy, Faculty of Veterinary science, Chulalongkorn University, Pathumwan, Bangkok, 10330.

*Corresponding author

ภาควิชากายวิภาคศาสตร์ คณะสัตวแพทยศาสตร์ จุฬาลงกรณ์มหาวิทยาลัย ปทุมวัน กรุงเทพฯ 10330

*ผู้รับผิดชอบบทความ

บทคัดย่อ

คำริ ดาราวีโรจน์* ก้องเกียรติ ศรีสุวรรณสกุล ศิลปชัย เพียรชอบ ศยามณ สุขจำลอง

การศึกษาตำแหน่งและการกระจายตัวของตัวรับเอสโตรเจน แอลฟา ในรังไข่และมดลูกของแมวบ้านที่ระยะต่างๆ ของการเป็นสัด ด้วยวิธีอิมมูโนฮิสโตเคมี

การศึกษาตำแหน่งและการกระจายตัวของตัวรับเอสโตรเจนแอลฟา (ER α) ด้วยวิธีอิมมูโนฮิสโตเคมี โดยการเก็บตัวอย่างมดลูกและรังไข่จากแมวบ้านที่ระยะ oestrus, anoestrus และ dioestrus โดยประเมินระยะของวงจรการเป็นสัดจากการตรวจเซลล์เยื่อบุช่องคลอด และระดับฮอร์โมนเอสโตรเจน และโปรเจสเตอโรนในกระแสเลือด พบว่าสามารถพบตัวรับเอสโตรเจนแอลฟาในของเซลล์มดลูกทุกชนิดแต่มีระดับการติดสีในนิวเคลียสของเซลล์ในแต่ละระยะการเป็นสัดที่แตกต่างกันและสามารถพบเซลล์ที่มีตัวรับเอสโตรเจนแอลฟาในเซลล์ของรังไข่บางชนิดเท่านั้น ในระยะ oestrus สามารถพบตัวรับเอสโตรเจนแอลฟาปริมาณมากที่เยื่อบุมดลูก เยื่อบุต่อม (glandular epithelium) และเยื่อบุพื้นผิว (surface epithelium) รวมทั้งในเซลล์ในชั้นกล้ามเนื้อ (myometrium) ขณะที่ในระยะ dioestrus ปริมาณของตัวรับเอสโตรเจนแอลฟาในเยื่อบุต่อมน้อยลงอย่างเห็นได้ชัด ที่ระยะ anoestrus พบการติดสีของตัวรับเอสโตรเจนแอลฟาค่อนข้างจางในเซลล์ต่างๆ ของมดลูกเกือบทุกส่วนยกเว้นในชั้นเนื้อเยื่อเกี่ยวพันซึ่งติดสีค่อนข้างเข้มเมื่อเปรียบเทียบกับส่วนอื่นๆ ของมดลูกในระยะเดียวกัน ส่วนในรังไข่พบว่ารังไข่ที่เก็บจากแมวในระยะ oestrus พบตัวรับเอสโตรเจนแอลฟาชัดเจนในเซลล์เยื่อบุรังไข่ (germinal epithelium) และเซลล์ในชั้นเนื้อเยื่อเกี่ยวพัน นอกจากนี้ยังพบการย้อมติดสีจางของตัวรับเอสโตรเจนแอลฟาปริมาณเล็กน้อยในเซลล์ของคอร์ปัส ลูเทียมบางเซลล์ อย่างไรก็ตามไม่ปรากฏการติดสีตัวรับเอสโตรเจนแอลฟาในเซลล์รังไข่จากแมวในระยะการเป็นสัดอื่น

จากการศึกษาครั้งนี้แสดงให้เห็นว่าฮอร์โมนเอสโตรเจนแสดงหน้าที่ผ่านตัวรับเอสโตรเจนแอลฟาเป็นส่วนใหญ่ในเซลล์ของมดลูกทุกชนิด แต่ในรังไข่ตัวรับเอสโตรเจนแอลฟาอาจจะไม่ใช่ตัวรับหลักของฮอร์โมนเอสโตรเจนในการแสดงหน้าที่ของมัน ดังนั้นควรจะมีการศึกษาถึงตัวรับเอสโตรเจนชนิดอื่นเช่น ตัวรับเอสโตรเจนเบต้า (ER β) ในเซลล์รังไข่ของแมวด้วย

คำสำคัญ: อิมมูโนฮิสโตเคมี ตัวรับเอสโตรเจนแอลฟา รังไข่ มดลูก

Introduction

Following the decrease of wild felidae populations such as the lion, tiger and cheetah, new technologies have been applied to solve such problems (Pope, 2000) but even with these the populations and birth rates of wild felidae are still low compared with the other animals. This may be due to insufficient knowledge of the reproductive biology and physiology in these felidae species. The domestic cat (*Felis catus*), as a member of the felidae family, could be a useful model of the endangered species, in this family, for the study of reproductive biology and physiology.

The structure as well as the functions of female reproductive organs are under the influence of ovarian steroid hormone, oestrogen and progesterone. Oestrogen acts through its specific receptor protein which is termed an oestrogen receptor (Katzenellenbogen, 1996). There are several studies indicating that the oestrogen receptor, subtype alpha, is the main subtype for regulating reproductive functions in the female. Therefore, a study of the oestrogen receptor, subtype alpha, was thought to be necessary to evaluate the mechanisms of oestrogen action in felidae reproductive organs. The objective of the present study was to investigate the localisation and distribution of oestrogen receptors in the reproductive organs, mainly

the uterus and the ovary of domestic cats, which could lead to a better understanding of reproductive physiology and pathology in the endangered species, using domestic cats as the model.

Materials and Methods

Experimental animals

All the queens used in the present study were spayed at the Obstetric and Gynecology unit, Chulalongkorn University Small Animal Hospital. Before ovariectomy, blood samples were taken and vaginal cytology was performed to determine the stage of the oestrous cycle.

Tissue collection

Uteri and ovaries were collected from twelve queens at different stages of the oestrous cycle. The samples were at oestrus (n=3), anoestrus (n=3) and dioestrus (n=3). Immediately after surgery, the samples were fixed in 4% paraformaldehyde for 24-36 hrs. They were then embedded in paraffin wax and stored until immunohistochemistry was performed.

Immunohistochemistry procedure

An indirect method (avidin-biotin-peroxidase) of immunohistochemical staining was used to evaluate the oestrogen receptors, alpha, in the uteri and ovaries. Each sample from the same queen was cut 4 µm thick sections and placed on the same glass slide. Before immunohistochemistry was performed, an antigen retrieval technique was used to enhance the reaction between antigen and antibody, by heating the tissue sections in a citrate buffer (0.01M, pH 6.0) using a microwave oven at 800 watt, for 5 min. The following procedures were done at room temperature (RT) with the tissue sections being washed with PBS (phosphate buffer saline 0.01M, pH 7.4) at each step in between, except before applying the primary antibody. Non-specific endogenous peroxidase was blocked by treating the

section with 3% hydrogen peroxide in methanol, for 10 mins. After treatment with normal horse serum for 30 mins, primary antibody which was mouse monoclonal antibody to ERα (NCL-ER-6F11, Novocastra Laboratories Ltd., United Kingdom), in a dilution of 1:25, was applied to the sections for 1 hr. Thereafter, the tissue sections were incubated with biotinylated horse anti-mouse IgG (Vectastain, Vector), in a dilution of 1:200, for 30 mins. The sections were then incubated with a horseradish peroxidase-avidin-biotin complex (Vectastains Elite, Vector) for 30 mins. Finally, the reaction was visualized by using 3,3'-diaminobenzidine as a chromogen (DAB kit; Vector) which stained brown when positive. All tissue sections were counterstained with hematoxylin and mounted with glycerine-gelatin for investigation under a light microscope.

Evaluation of the results

The results of immunohistochemical staining were evaluated by semiquantitative methods. For the uterus, each of the uterine compartments, which consisted of the surface epithelium, the connective tissue stroma (STR), the glandular epithelium (GE) and the myometrium (M) were analysed separately and the results were shown according to the range of positive staining intensity. For the ovary, the results were described for each separate compartment which were the germinal epithelium, the follicular cells, the luteal cells and the interstitial cells. In each compartment, the staining intensity was evaluated at three different levels: +/- weak intensity, ++/ moderate intensity and +++/ strong intensity. In some compartments, when the staining intensity was not uniform, the result was shown as a range: +/-++ = weak to moderate and ++/ +++ = moderate to strong intensity.

Results

Positive cells were stained brown in their nuclei by the DAB chromogen whereas the nuclei of negative cells were stained blue by Mayer's hematoxylin counterstaining. The result was reported as an average

staining intensity of positive cells in the uterus (table 1) and in the ovary (table 2). Among all the uterine compartments, the proportion of positive stained cells was different in the stroma, where only half of all the connective tissue stromal cells were stained positive.

Immunohistochemistry of ER α in the uterus

Positive staining was detected in all cell types in the uterus. During oestrus, stronger staining intensity was found in stromal cells and glandular epithelium than in the surface epithelium and the myometrial cells. During anoestrus and dioestrus, weak nuclear staining was found in the surface epithelium and the myometrial cells, whereas the staining intensity was moderate to strong in the

glandular epithelium and the stromal cells. However, when comparing the different oestrous stages, the staining intensity was strongest during oestrus than at other stages of the oestrous cycle, in all compartments.

Immunohistochemistry of ER α in the ovary

During anoestrus, positive immunostaining was found only in the germinal epithelium of the ovary. Weak nuclear staining was only found in the germinal epithelium during dioestrus as well. However, during oestrus, positive results were demonstrated in follicular cells and interstitial cells. In addition, the intensity of immunoreactivity of ER α in the germinal epithelium was remarkably increased during oestrus.

Table 1 Average staining intensity of ER α in the uterus at different stages of the oestrous cycle.

Stages	Surface epithelium	Glandular epithelium	Stroma	Myometrium
Oestrus	++	+++	++/+++	+/>++
Dioestrus	+/>++	++/+++	++	+
Anoestrus	+	++	++	+

Staining intensity: + = weak, ++ = moderate, +++ = strong
+/>++ = weak to moderate, ++/+++ = moderate to strong

Table 2 Average staining intensity of ER α in the ovary collected at different stages of the oestrous cycle

Stages	Germinal epithelium	Follicular cells	Luteal cells	Interstitial cells
Oestrus	++/+++	+	Not observed	+
Dioestrus	+	--	--	--
Anoestrus	+	--	--	--

Staining intensity: + = weak, ++ = moderate, +++ = strong
+/>++ = weak to moderate, ++/+++ = moderate to strong

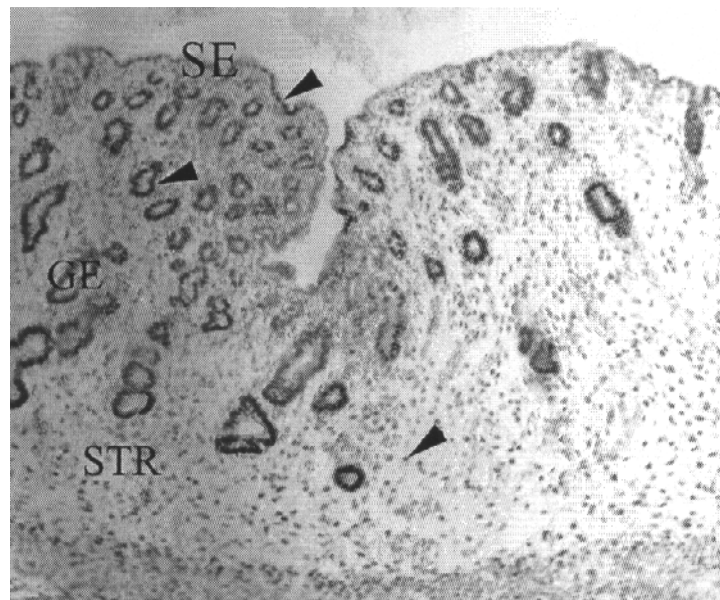


Fig 1 Immunostaining of ER α in the uterus of the domestic cat, positive cells (arrow head) was shown with brown staining in the nuclei. SE = Surface epithelium, GE = glandular epithelium and STR = connective tissue stroma

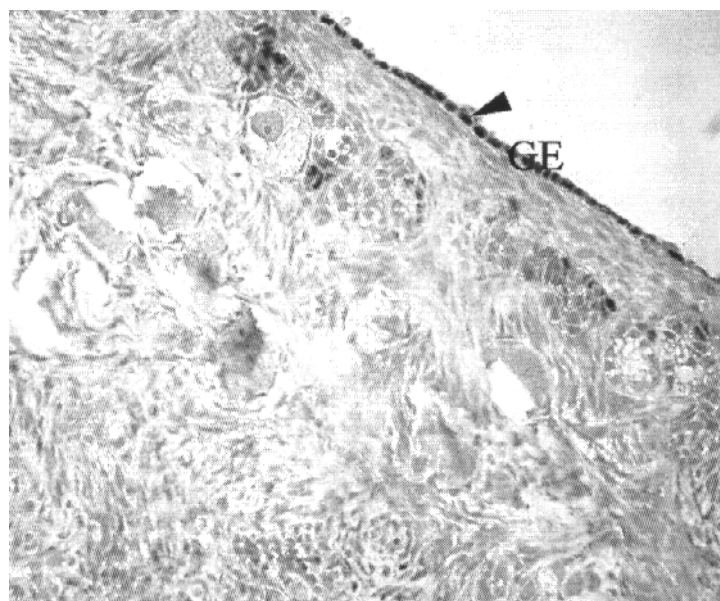


Fig 2 Immunostaining of ER α in the ovary of domestic cat. Positive cell was shown by arrow head, GE = Germinal epithelium of the ovary

Discussion

Positive staining was seen in the nuclei of all cell types of the uterus which was in agreement with most oestrogen receptor studies (Cherny et al., 1991; De Cock et al., 1997; Vermeirsch et al., 2002). When comparison is made between the ovaries and the uteri, more staining was observed in the uteri. This reason for this could be that ER α was not the main subtype for regulating reproductive physiology in the ovary. Instead, another subtype, oestrogen receptor beta (ER β) which has been discovered later, should be considered (Drummond et al., 1999; Chiang et al., 2000; Mowa and Iwanaga, 2000; Pelletier and El-Alfy, 2000; Wang et al., 2000; Jansen et al., 2001; Slomczynska and Wozniak, 2001).

In the uterus, ER α protein was prominent during oestrus in all compartments, in agreement with earlier studies that found that ER was high during oestrus when the level of oestrogen was also high (Dhaliwal et al., 1997; Vermeirsch et al., 1998). There was one study showed that oestrogen can up-regulate oestrogen receptor protein in the uterus but this effect depended upon specific uterine cell types (Ing and Tornesi, 1997). This finding was supported by the present study which showed that different compartments had different intensities of ER α staining, even during the same oestrous stage. In addition, the ER α level in the uterus during oestrus was not apparently different from that during dioestrus. This result implied that a high progesterone level during dioestrus had a weak impact on the presence of ER α in the cat uteri.

In the ovary, the strong staining found in the germinal epithelium during oestrus supported the concept that epithelial ingrowth of the ovary was mediated by oestrogen via ER α (De Cock et al., 1997). In other compartments of the ovary, such as the follicular granulosa cells, the luteal cells and the ovarian stromal cells, positive stained cells were rarely observed. This suggested that these compartments of the ovary were not the main target organs for oestrogen, in mediating its

effect through the ER α protein. However, ER α may exist in the ovary even at dioestrus and anoestrus but in lower concentrations than could be detected by immunohistochemistry.

There is a study that showed oestrogen-induced, uterine epithelial proliferation is mediated indirectly by ER alpha-positive stroma (Cooke et al., 1997; Buchanan et al., 1999; Sukjumlong et al., 2003). The present study supported this finding for at oestrus, ER staining was high in the connective tissue stroma and could be that epithelial proliferation in the cat uterus during oestrus is also regulated by oestrogen acting through ER α in the stroma in a paracrine manner.

In conclusion, the study showed that the differences between the uterus and ovary during the oestrous cycle could be due to different mechanisms for regulating steroid receptor expression in these two tissues. In the uterus, estrogen elicits its function mainly via ER α whereas in the ovary, the finding that not all ovarian cell types express ER α may postulate that the estrogen receptor, subtype alpha, is neither the major nor the only receptor protein for estrogen and ER β should also be investigated in the cat ovary.

References

- Buchanan, D. L., Setiawan, T., Lubahn, D. B., Taylor, J. A., Kurita, T., Cunha, G. R. and Cooke, P. S. 1999. Tissue compartment-specific estrogen receptor-alpha participation in the mouse uterine epithelial secretory response. *Endocrinology*. 140(1): 484-491.
- Cherny, R. A., Salamonsen, L. A. and Findlay, J. K. 1991. Immunocytochemical localization of oestrogen receptors in the endometrium of the ewe. *Reprod. Fertil. Dev.* 3(3): 321-331.
- Chiang, C. H., Cheng, K. W., Igarashi, S., Nathwani, P. S. and Leung, P. C. 2000. Hormonal regulation of estrogen receptor alpha and beta gene expression in human granulosa-luteal cells in vitro. *J. Clin. Endocrinol. Metab.* 85(10): 3828-3839.

- Cooke, P. S., Buchanan, D. L., Young, P., Setiawan, T., Brody, J., Korach, K. S., Taylor, J., Lubahn, D. B. and Cunha, G. R. 1997. Stromal estrogen receptors mediate mitogenic effects of estradiol on uterine epithelium. *Proc. Natl. Acad. Sci. USA.* 94(12): 6535-6540.
- De Cock, H., Ducatelle, R. and Logghe, J. P. 1997. Immunohistochemical localization of estrogen receptor in the normal canine female genital tract. *Domest. Anim. Endocrinol.* 14(3): 133-147.
- Dhaliwal, G. K., England, G. C. and Noakes, D. E. 1997. Immunocytochemical localization of oestrogen and progesterone receptors in the uterus of the normal bitch during oestrus and metoestrus. *J. Reprod. Fertil. Suppl.* 51: 167-176.
- Drummond, A. E., Baillie, A. J. and Findlay, J. K. 1999. Ovarian estrogen receptor alpha and beta mRNA expression: impact of development and estrogen. *Mol. Cell Endocrinol.* 149(1-2): 153-161.
- Ing, N. H. and Tornesi, M. B. 1997. Estradiol up-regulates estrogen receptor and progesterone receptor gene expression in specific ovine uterine cells. *Biol. Reprod.* 56(5): 1205-1215.
- Jansen, H. T., West, C., Lehman, M. N. and Padmanabhan, V. 2001. Ovarian estrogen receptor-beta (ERbeta) regulation: I. Changes in ERbeta messenger RNA expression prior to ovulation in the ewe. *Biol. Reprod.* 65(3): 866-872.
- Katzenellenbogen, B. S. 1996. Estrogen receptors: bioactivities and interactions with cell signaling pathways. *Biol. Reprod.* 54(2): 287-293.
- Mowa, C. N. and Iwanaga, T. 2000. Differential distribution of oestrogen receptor-alpha and -beta mRNAs in the female reproductive organ of rats as revealed by in situ hybridization. *J. Endocrinol.* 165(1): 59-66.
- Pelletier, G. and El-Alfy, M. 2000. Immunocytochemical localization of estrogen receptors alpha and beta in the human reproductive organs. *J. Clin. Endocrinol. Metab.* 85(12): 4835-4840.
- Pope, C. E. 2000. Embryo technology in conservation efforts for endangered felids. *Theriogenology.* 53(1): 163-174.
- Slomczynska, M. and Wozniak, J. 2001. Differential distribution of estrogen receptor-beta and estrogen receptor-alpha in the porcine ovary. *Exp. Clin. Endocrinol. Diabetes.* 109(4): 238-244.
- Sukjumlong, S., Kaeoket, K., Dalin, A. M. and Persson, E. 2003. Immunohistochemical studies on oestrogen receptor alpha (ER alpha) and the proliferative marker Ki-67 in the sow uterus at different stages of the oestrous cycle. *Reprod. Domest. Anim.* 38(1): 5-12.
- Vermeirsch, H., Simoens, P. and Lauwers, H. 1998. Variation in the estrogen receptor content of canine uterine tissue throughout the estrous cycle. *Ital. J. Anat. Embryol.* 103(4 Suppl 1): 267-275.
- Vermeirsch, H., Van Den Broeck, W., Coryn, M. and Simoens, P. 2002. Immunolocalization of sex steroid hormone receptors in the canine uterine tube and their relation to sex steroid hormone concentrations. *Reprod. Fertil. Dev.* 14(3-4): 241-250.
- Wang, H., Eriksson, H. and Sahlin, L. 2000. Estrogen receptors alpha and beta in the female reproductive tract of the rat during the estrous cycle. *Biol. Reprod.* 63(5): 1331-1340.