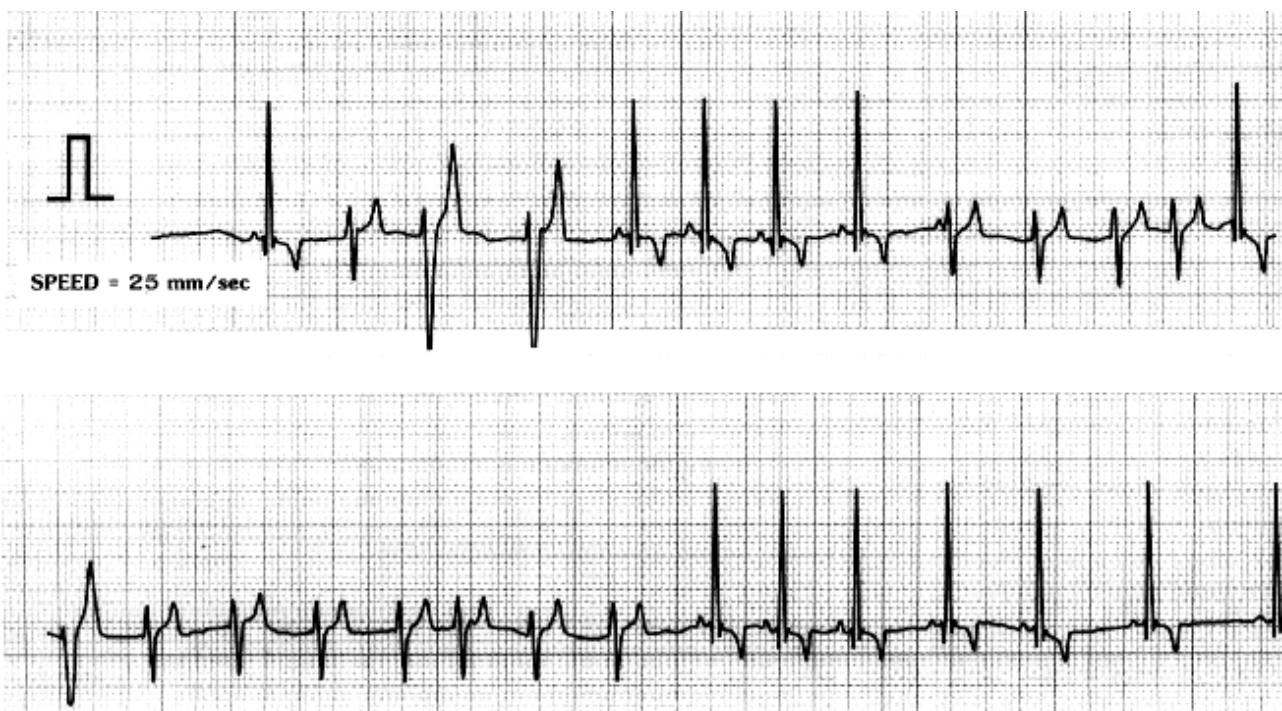

## ECG Quiz

**Chollada Buranakarl\* Kris Angkanaporn**

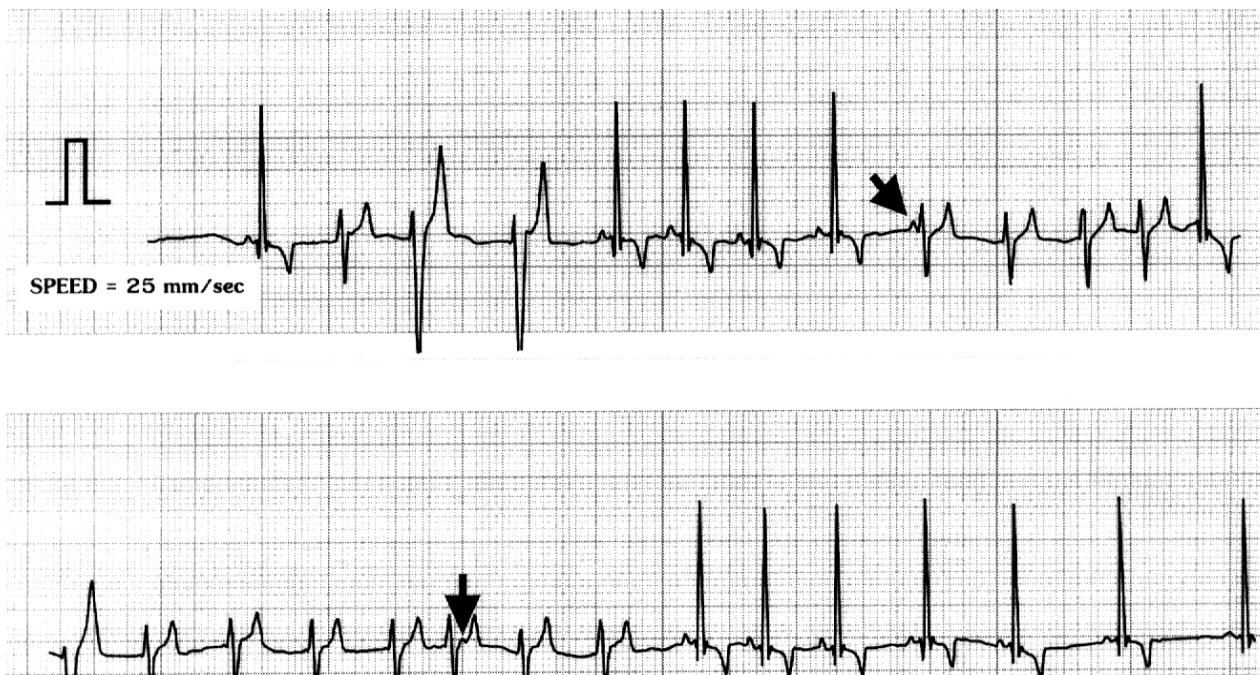


Paper speed = 25 mm/sec

A 6-year-old, Golden Retriever, male dog weighing 27 kg was referred to the Chulalongkorn Small Animal Hospital with a history of azotemia (BUN 188 mg/dl, creatinine 10.2 mg/dl and inorganic phosphorus 15 mg/dl). Physical examination revealed halitosis, depression, anorexia, a purulent ocular discharge and panting. A complete blood count (CBC) indicated anemia (RBC

$3.16 \times 10^6$  cell/ $\mu$ l, Hct 19.5 % and Hb 6.5 g%) and leukopenia (WBC 4,320 cell/ $\mu$ l). Other serum chemistry profiles were within normal limits. A thoracic radiograph showed pleural effusion and an interstitial pattern in the lungs. An ECG was made and is shown above.

Please make your interpretation before turning to the next page



### Accelerated ventricular rhythm

This strip showed the sinus complexes with an impulse rate that was variable. When the impulses from the sinus slows down below the diastolic potential of the accelerated ventricular pacemaker, ventricular ectopic beats appear and take over by overruling the overdrive suppression of the basic sinus rhythm. Please noted that there are some P waves (dark arrows) in this tracing which are non-conducting P waves. The shape of the ventricular premature complexes (VPCs) was variable which may be due to multiple locations of the ectopic pacemaker or a combination of waveform from different pacemaker locations, causing fusion beats. The shape of the fusion beats may be

seen between the sinus and the ectopic beats. This example is a non-paroxysmal ventricular tachycardia since true paroxysmal ventricular tachycardia (PVT) has no fusion beats and the coupling interval of the first VPC with a sinus beat will be constant. Also, the rate of the sinus beat after the VPC in true PVT will not exceed the rate of ectopic beats which is actually seen in this case.

The cause of an accelerated ventricular rhythm may not always be associated with organic disease of the heart. It may be found in cases of trauma, gastric torsion or splenic tumor. This arrhythmia will disappear when the underlying problem is resolved. Since the heart rate does not exceed 160 beats/min (HR = 128 beats/min), the stroke volume will be adequate in this case.