

# MALIGNANT CATARRHAL FEVER IN SWAMP BUFFALOES (*BUBALUS BUBALIS*): A RETROSPECTIVE PATHOLOGICAL STUDY OF OUTBREAKS IN THAILAND

Komkrich Teankam<sup>1\*</sup> Rachod Tantilertcharoen<sup>2</sup> Thanasak Boonserm<sup>3</sup>  
Siriwat Suadsong<sup>4</sup> Wijit Banlunara<sup>1</sup>

## Abstract

Komkrich Teankam<sup>1\*</sup> Rachod Tantilertcharoen<sup>2</sup> Thanasak Boonserm<sup>3</sup> Siriwat Suadsong<sup>4</sup> Wijit Banlunara<sup>1</sup>

## MALIGNANT CATARRHAL FEVER IN SWAMP BUFFALOES (*BUBALUS BUBALIS*): A RETROSPECTIVE PATHOLOGICAL STUDY OF OUTBREAKS IN THAILAND

Malignant catarrhal fever (MCF) is a highly fatal disease of ruminants which has not been extensively studied in Thailand. The aim of this study was to describe the clinical signs and pathological findings of MCF-affected buffaloes ( $n = 13$ ), in the Nakhonpathom province of Thailand. All cases were collected between May 1996 and August 2000. Before the 1998 outbreak, four clinically normal sheep were moved into a pen adjacent to the buffaloes' pens. The animals developed clinical signs of severe depression, anorexia, high fever, hypersalivation, and corneal opacity-associated excessive lacrimation. Necropsy revealed severe haemorrhages in various organs including the oropharynx, trachea, heart, kidneys and urinary bladder. Ulcerative stomatitis and abomasitis was often present. Diphtheritic tracheitis and/or pharyngitis were seen in 7/9 (77.8%) cases. Histopathologically, generalised vasculitis with occasional fibrinoid degeneration was a pathognomonic lesion detected in all cases in this study. Lymphoid infiltration was recognized in various organs, including the liver, eyes, and meninges, tracheal and intestinal submucosa. In this study, interstitial nephritis and non-suppurative myocarditis were markedly noticed. A skin lesion, consisting of chronic vasculitis, was observed in one buffalo, and is an unusual feature of MCF. The diagnoses of MCF in this study were based on histopathology and a nested polymerase chain reaction (PCR) result in one case. In conclusion, MCF was a highly fatal disease of buffaloes, and generalised vasculitis was clearly detectable in all cases. It is possible to speculate from the history of the outbreak, that MCF in buffaloes, in this study, was associated with sheep.

---

**Keywords :** Malignant catarrhal fever, buffaloes, vasculitis, Thailand.

<sup>1</sup>Department of Pathology, <sup>2</sup>Veterinary Diagnostic Laboratory Unit, <sup>3</sup>Department of Veterinary Medicine, <sup>4</sup>Department of Obstetrics Gynaecology and Reproduction, Faculty of Veterinary Science, Chulalongkorn University, Bangkok 10330, Thailand.

\*Corresponding author

## บทคัดย่อ

คมกฤษ เทียนคำ<sup>1\*</sup> รัชฎ์ ดันติเลิศเจริญ<sup>2</sup> ธนศักดิ์ บุญเสริม<sup>3</sup> ศิริวัฒน์ ทรวงทรง<sup>4</sup> วิจิตร บรรณนารา<sup>1</sup>

### การศึกษาย้อนหลังทางพยาธิวิทยาของโรคไวรัส Malignant catarrhal fever ของการระบาดในกระบือปลักในประเทศไทย

โรค Malignant catarrhal fever (MCF) เป็นโรคที่เกิดกับสัตว์เคี้ยวเอื้องหลายชนิด และมีอัตราการตายสูง การศึกษาครั้งนี้มีวัตถุประสงค์ในการอธิบายอาการ และรอยโรคทางพยาธิวิทยาที่เกิดขึ้นในกระบือปลัก ซึ่งตายจากโรค (MCF) ที่จังหวัดนครปฐม ในช่วงระหว่างปี พ.ศ. 2539-2543 ก่อนการระบาดอย่างรุนแรงในปี พ.ศ. 2541 ได้นำแกะเข้ามาเลี้ยงรวมในบริเวณคอกกระบือปลัก ในกระบือที่ป่วยพบอาการแสดงทางคลินิก ชีพมาก เบื่ออาหาร ไข้สูง น้ำลายไหลมาก และมีน้ำตาไหลมากกว่าปกติ ร่วมกับกระจกตาขุ่น ผลการชันสูตรซาก รอยโรคที่พบบ่อย คือ พบเลือดออกรุนแรงในอวัยวะต่างๆ ได้แก่ คอหอย ปาก หลอดลม หัวใจ ไต และกระเพาะปัสสาวะ การอักเสบแบบมีแผลหลุมในช่องปากและกระเพาะอาหารแท้ รอยโรคหลอดลมอักเสบชนิดเป็นแผ่นเนื้อตายยึดติดบนเยื่อหลอดลม พบได้ในกระบือปลัก 7 ตัว จาก 9 ตัว (77.8%) ในทางจุลพยาธิวิทยาพบรอยโรคหลอดเลือดอักเสบกระจายทั่วร่างกายในกระบือทุกตัว และพบการแทรกเข้ามาของเซลล์ลิมโฟไซต์ในอวัยวะต่างๆ ได้แก่ ตับ ตา เยื่อหุ้มสมอง หลอดลม และชั้นใต้เยื่อเมือกลำไส้ ในการศึกษาครั้งนี้ยังพบไตอักเสบแบบเรื้อรังไม่มีหนองและการอักเสบแบบไม่มีหนองของกล้ามเนื้อหัวใจ นอกจากนี้ยังพบรอยโรคหลอดเลือดอักเสบเรื้อรังทั่วร่างกายโดยเฉพาะที่ผิวหนังในกระบือปลัก 1 ตัว รอยโรคที่ผิวหนังดังกล่าว จัดเป็นรอยโรคที่พบได้น้อยมากในสัตว์ที่ป่วยเป็นโรคนี้ จากการศึกษาครั้งนี้ คาดว่าการระบาดของโรค MCF ในกระบือครั้งนี้ น่าจะมีส่วนเกี่ยวข้องกับแกะ

**คำสำคัญ :** กระบือปลัก Malignant catarrhal fever หลอดเลือดอักเสบ ไทย

<sup>1</sup>ภาควิชาพยาธิวิทยา <sup>2</sup>หน่วยชันสูตรโรคสัตว์ฯ <sup>3</sup>ภาควิชาสัตวศาสตร์ <sup>4</sup>ภาควิชาอายุรศาสตร์ คณะสัตวแพทยศาสตร์ จุฬาลงกรณ์มหาวิทยาลัย

กรุงเทพฯ 10330

\*ผู้รับผิดชอบบทความ

## Introduction

Malignant catarrhal fever (MCF) is a highly fatal disease that occurs in cattle, buffaloes, deer and other ruminants (Barker et al., 1993; Schultheiss, et al., 2000). MCF is characterised by clinical signs of corneal opacity with severe lacrimation, high fever and anorexia. Ulceration of the mucosa, including the oral mucosa, intestinal mucosa and urinary tract, is a prominent lesion in affected cattle. Striking microscopic lesions include a severe generalised vasculitis, especially in the kidney, liver, meninges and carotid rete (Liggitt and DeMartini, 1980<sup>a, b</sup>). It has been previously established that MCF is an acute disease with high mortality (Plowright, 1990 and Barker et al., 1993); however, in recent years chronic cases and recovered cases have been increasingly recognised (Milne and Reid, 1990; O'Toole et al., 1997; Penny 1998; Schultheiss et al., 1998). The etiologic

agent is classified as two types of gamma herpesvirus: alcelaphine herpesvirus 1 (AHV-1) which causes wildebeast-associated MCF (WA-MCF) and ovine herpesvirus 2 (OHV-2) which causes sheep-associated MCF (SA-MCF) (Plowright, 1990). Wildebeast and sheep are natural carriers of the two viruses, respectively. Recently, caprine-associated herpesvirus 2 (CpHV-2) has been recognised in domestic goats, and the virus has been associated with MCF in deer (Li et al., 2001; Crawford et al., 2002). In Africa, WA-MCF occurred in cattle which had been in contact with wildebeast, and AHV-1 was successfully isolated. Though the causative virus of SA-MCF has never been isolated, it is genetically, closely related to AHV-1. It is known that sheep are asymptomatic carriers of OHV-2, shedding the virus and passing it to other ruminants (Plowright, 1990; Wiyono et al., 1994). SA-MCF has been reported in cattle and other ruminants

in such locations as the Americas (Pierson et al., 1973), Europe (Selman et al., 1974; M<sub>ller</sub>-Doblies et al., 2001) and New Zealand (Tham, 1997). Outbreaks in buffaloes have been recorded in India (Singh and Gill, 1995), New Zealand (Hill et al., 1993), Malaysia (Vanselow, 1980) and Indonesia (Hoffmann et al., 1984).

In Thailand, there is very little information about MCF in cattle or buffaloes, only one case before this report has previously been recorded (Banlunara et al., 2003). Details of the pathological findings of MCF in buffaloes are also scarce. The objective of this study was to describe the clinical signs and pathological findings of MCF in the 13 buffaloes, diagnosed in the Nakornpathom province of Thailand during the period from 1996 to 2000. Those observations could possibly prompt veterinarians in Thailand to consider the disease as a possible differential diagnosis when confronted with fatal diseases in buffaloes, cattle and other exotic ruminants, especially when these animals have been in contact with sheep.

## Materials and Methods

### Clinical history

All cases ( $n = 13$ ) were collected from the Pathology unit of the Large Animal Hospital, Faculty of Veterinary Science, Chulalongkorn University, Nakornpathom province, Thailand. The affected buffaloes were from two herds; herd A (case Nos. 1, 10, and 13) consisted of 10 animals, and herd B (case Nos. 2-9, 11, and 12), 26 animals. Herd A was confined and separated by about 50 meters from herd B. All animals belonged to the demonstration farm of the faculty and located close to the Large Animal Hospital. The farm accommodates various kinds of animals including pigs, chicken, cattle, buffaloes and sheep. The sheep herd (approximately 100 sheep) was housed separately from the other ruminants. The distance between the sheep and the buffalo pens was approximately 100 metres.

Case No. 1 occurred in May 1996. Case Nos. 2 - 10 occurred in 1998: case Nos. 2 - 6 in May; case Nos. 7 and

8 in June; case No. 9 in July and case No. 10 in August 1998. The remaining case No. 11 occurred in May 1999, case No. 12 in September 1999, and case No. 13 in August 2000. In mid April of 1998, before the serious outbreak occurred in herd B, four sheep were moved into the area where buffalo herd B was kept for other research purposes, and housed in a pen adjacent to the buffalo pens and under the same roof. The first buffalo died on May 16<sup>th</sup>, 1998, after 3 days of clinical illness. It is not included in these 13 reported-cases, because the clinical and pathological data are not available. The disease in herd A appeared sporadically, but it was epidemic in herd B from May to July 1998 with a morbidity rate of 34.62% (9/26), and a mortality rate of 88.89% (8/9). The buffaloes were clinically examined daily until death, and blood samples collected from case Nos. 3 - 6 for haematology. The buffaloes were given antibiotics, supportive treatment and non-steroidal anti-inflammatory drugs.

### Postmortem study

Necropsy was performed on 11 buffaloes excepting case No. 6, which completely recovered, and case No. 10 that was sent to slaughter house without necropsy. Various organs were submitted for routine histopathology, and Mallory's phosphotungstic acid haematoxylin method (PTAH) was used to demonstrate fibrin. Lung samples of four buffaloes were submitted for bacteriology.

### Polymerase chain reaction (PCR)

The formalin-fixed and paraffin-embedded tissues of kidney and lymph node of case No. 11 were examined by nested PCR using primer sets specific to OHV-2. The DNA extraction method and PCR conditions were as previously described (Banlunara et al., 2003). In brief, DNA was extracted using a phenal-chloroform extraction method. Three µg of DNA (approximately) were subjected to PCR. The primer sets used in this study were previously described (Li et al., 1995): primer set 556 (5'-AGTCTG GGGTATATGAATCCAGATGGCTCTC-3') and primer

set 775 (5'-AAGATAAGCACCAAGTTATGCATCTGA TAAA-3') in the first step, and primer sets 556 and 555 (5'-TTCTGGGGTAGTGGCGAGCGAAGGCTTC-3') in the second step (238 bp product). PCR was performed using a commercial kit (Takara EX Taq, Takara, Japan) on a thermal cycler (Takara). PCR conditions for the first step were 38 cycles of denaturing (94°C, 1 min), annealing (60°C, 1 min) and extension (72°C, 2 min) with a final extension (72°C, 10 min). The second amplification was performed under the same conditions using 10 µl of PCR product from the first step as the DNA template. PCR products were analyzed by 2% agarose gel electrophoresis with ethidium bromide staining.

## Results

### Clinical observations

The major initial symptoms observed in most of the animals were anorexia, severe depression, fever, and conjunctivitis with excessive lacrimation. The ocular discharge later became purulent (4 of 11 animals). Bilateral corneal opacity (7 of 11 cases, 63.6%) began at the peripheral limbus and continually spread into the centre of the cornea. Case Nos. 2 and 3 developed severe diphtheritic necrosis of the third eyelid. Some animals had hypersalivation and a serous nasal discharge, which later became purulent (8 of 10 cases), and some cases dried with an encrusted muzzle. Diarrhoea was observed only in case No. 2. The buffalo bull (case No. 4) was severely depressed and its penis was persistently relaxed throughout the illness with dry skin and hyperemia. Buffalo No. 6 completely recovered after a severe illness, but further information could not be retrieved.

Haematological findings (Table 1) revealed marked leucopenia, lymphopenia, and mild neutropenia in all the animals examined. Buffalo No. 6 showed consistent leucopenia from the 1<sup>st</sup> to the 6<sup>th</sup> day of illness (2.7 to 4.7 (10<sup>3</sup> cells/µl); but after its recovery, the level of leucocytes in circulation increased to a normal range (Fig. 1). The clinical data and gross lesions are

summarized in Table 2. The average age of affected buffaloes was 2.6 years (ranging from 1.5 to 5 years). The duration of illness ranged from 2 to 21 days (mean = 6.5 days). Bacteriology on the lung showed only non-specific bacteria.

### Pathological findings

A narrow ring of mild corneal opacity, 2 to 4 mm in width, was observed at corneal limbus of both eyes in 6 out of 9 (66.7%) animals (Fig. 2) and was associated with severe conjunctivitis. Erosions or ulcerations of the oral mucosa and the lingual epithelium were seen in most animals (Fig. 3). Multiple ecchymotic haemorrhages and severe congestion were often observed in the mucosa of the nasal sinus, epiglottis, pharynx, trachea and bronchi. Abundant frothy fluid in the tracheal lumen was consistently seen in all animals, except in case No. 11. Tracheal and/or pharyngeal mucosa in 7 out of 9 animals (77.8%) was covered with a yellowish diphtheritic membrane (Fig. 4). Lungs in 10 cases (No. 1-5, 7-9, 12-13) were markedly oedematous, and multifocal gray areas (0.5-1 cm) were occasionally observed in the diaphragmatic lobes. The tracheobronchial lymph nodes and other lymph nodes of some animals were enlarged. Various degrees of haemorrhage in the epicardium, myocardium, and endocardium were observed in all animals. Severe haemorrhage in the renal capsules and the parenchyma were demonstrated. Haemorrhagic cystitis, occasionally accompanied with ulceration (mild to moderate degree), was frequently seen. In case No. 11, firm nodules (variable in size: 1.5-5 cm) in the subcutaneous tissue of the abdominal wall, the prescapular area and both hindlimbs were observed.

Microscopically, severe necrotic vasculitis characterised by mononuclear cell infiltration in the tunicae adventitia and media of blood vessels was a hallmark of the histopathological features. The vascular lesions involved medium-sized arteries, arterioles and venules. These lesions were particularly noticeable in hearts, livers, kidneys, lungs, trachea, genital organs,

lymph nodes, brain and meninges. Vasculitis also appeared at the area of oral ulcers and abomasal ulcers. Fibrinoid degeneration of the blood vessels, confirmed by (PTAH), was noted in 6 animals. This lesion together with necrotizing vasculitis was seen in several organs, including the pampiniform plexuses, uterus, ovaries, lymph nodes, urinary bladders, kidneys, and submucosa of the trachea and the intestine.

Non-suppurative, mild to moderate meningo-encephalitis, accompanied by vasculitis and occasional fibrinoid degeneration, was noticed in most cases (7/11, 63.6%). A mild degree of gliosis was found in 3 out of 9 animals examined (33.3%). In the eyes, lympho-histiocytic infiltration with fibrinoid vasculitis was often observed in the ciliary bodies, sclera, and ocular muscle (Fig. 5). Corneal oedema of a mild degree was also demonstrated. Hyphema in the posterior chamber was seen in case No. 9. Vascular lesions and lymphocytic infiltration were observed in the tracheal submucosa in the area where diphtheritic necrosis of trachea was observed. In lung tissues, severe interlobular oedema accompanied by multifocal vasculitis and lymphocytic infiltration was frequently found. Striking lesions of non-suppurative myocarditis and interstitial nephritis accompanied by vasculitis (Figs. 6, 7) were frequently noted. Multifocal

necrosis of the bladder mucosa together with fibrinoid vasculitis and lymphocytic infiltration in the submucosa were frequently found. In male buffaloes, severe vasculitis of the pampiniform plexus (Figs. 8, 9) with occasional fibrinoid degeneration was seen in all the bulls examined. Venous thrombosis was sometimes seen. The infiltration of lymphocytes also appeared in ovaries, with a severe vasculitis of ovarian vessels. The uterus (case Nos. 9 and 13) had prominent vasculitis in the myometrium and the serosa. Infiltration of lymphocytes in the liver, mainly in the portal area, was obvious in all buffaloes examined. Vascular changes in the spleen usually occurred in the splenic trabeculae. In the lymph nodes, vasculitis was frequently found in the capsule and medulla, concurrent lymphoid necrosis or depletion was also noticed. The enlarged lymph nodes of case No. 11 had a striking vasculitis in the medulla consisting of severe hyperplasia of the tunica media with lymphoid infiltration in the adventitia and media. Similar lesions of chronic vasculitis were generalized in the visceral organs as well as in the nodular skin lesions of this buffalo. From this case (No. 11), the nested PCR of tissues from lymph nodes and kidney was successfully used to amplify the 238 bp DNA (the result not shown) as expected from the second primer set (555 and 556).

**Table 1** Haematological results obtained from buffaloes (herd B) in an outbreak of MCF in 1998.

Case No.	3	4	5	6 <sup>b</sup>	Reference range <sup>c</sup>
Day of blood collection <sup>a</sup>	2 <sup>nd</sup>	5 <sup>th</sup>	3 <sup>rd</sup>	1 <sup>st</sup>	
RBC (x10 <sup>12</sup> /l)	6.04	6.86	5.99	4.50	7.2-9.6
Haemoglobin (g/dl)	12.1	15.8	14.0	10.2	13.6-17.1
PCV (%)	36.6	48.7	44.2	29.4	0.35-0.45
Total WBC (x10 <sup>9</sup> /l)	3.8	2.7	4.5	2.7	8.8-14.7
Lymphocytes (x10 <sup>9</sup> /l)	2.05	1.8	1.03	1	5.3-11.2
Neutrophils (x10 <sup>9</sup> /l)	1.6	0.8	3.24	1	1.6-4.4
Eosinophils (x10 <sup>9</sup> /l)	0	0.05	0.06	0.65	0.0-0.34
Monocytes (x10 <sup>9</sup> /l)	0.1	0.08	0.1	0.05	0.0-0.3
Basophils (x10 <sup>9</sup> /l)	0	0	0	0	0.0-0.24

<sup>a</sup>days after the onset of clinical signs, <sup>b</sup>recovered animal, <sup>c</sup>Hill et al., 1992.

**Table 2** Clinical signs and gross lesions in buffaloes with MCF ( $n = 13$ ).

Case No.	1	2	3	4	5	6 <sup>a</sup>	7	8	9	10 <sup>b</sup>	11	12	13
Sex	m	f	m	m	f	f	m	f	f	f	f	f	f
Age (yrs)	2.5	1.5	1.5	4	1.5	2.5	na	4	1.5	2	na	2.5	5
Duration of illness (days)	2	3	4	7	6	8	3	na	21	3	7	7	7
<b>Clinical signs</b>													
Conjunctivitis	-	+ <sup>s</sup>	+ <sup>s</sup>	+ <sup>s</sup>	na	+	+ <sup>s</sup>	na	-	+	-	+ <sup>m</sup>	+ <sup>m</sup>
Corneal opacity	-	-	+	+	-	na	+	na	+ <sup>s</sup>	+	-	+ <sup>m</sup>	+
Ocular discharge	p	p	s	s	na	p	s	na	p	s	-	na	s
Nasal discharge	p	p	na	s	na	p	p	na	p	p	p	na	p
Anorexia	+ <sup>s</sup>	+ <sup>s</sup>	+ <sup>s</sup>	+ <sup>s</sup>	na	+ <sup>s</sup>	+ <sup>s</sup>	na	+ <sup>s</sup>	+ <sup>s</sup>	+ <sup>s</sup>	+ <sup>s</sup>	+ <sup>s</sup>
Fever	+	na	+	+	+	+	+	na	na	+	-	+	+
<b>Gross lesions</b>													
Corneal opacity	na	-	+ <sup>m</sup>	+	-		+	na	+ <sup>s</sup>		-	+ <sup>m</sup>	+
Ulcerative stomatitis	+	+	+	+	+		na	na	+		-	+	na
Ulcerative abomasitis	na	na	na	+	+		na	-	na		-	na	na
Ulcer / haemorrhage of urinary bladder	-	na	+ <sup>m</sup>	+ <sup>s</sup>	+ <sup>m</sup>		+ <sup>m</sup>	+	+ <sup>m</sup>		-	na	-
Lymphadenopathy	-	+	+	+ <sup>m</sup>	+		+ <sup>m</sup>	+	na		+	+	+
Diphtheritic pharyngitis / tracheitis	na	+ <sup>s</sup>	+ <sup>s</sup>	+ <sup>s</sup>	-		+ <sup>m</sup>	na	+ <sup>m</sup>		-	+ <sup>m</sup>	+ <sup>m</sup>
<b>Haemorrhage of</b>													
- epicardium	+	na	n	+ <sup>s</sup>	+		-	na	-		-	na	-
- endocardium	-	+ <sup>s</sup>	+ <sup>m</sup>	+ <sup>s</sup>	+ <sup>m</sup>		+ <sup>m</sup>	na	+ <sup>m</sup>		-	na	+
- myocardium	-	+	na	+ <sup>m</sup>	+		-	na	-		-	na	+
- intestine	+	na	na	+ <sup>m</sup>	+		na	na	-		-	na	na
- lymph node	na	+	+	+	+		+	na	na		-	na	+
- tracheal mucosa	+	+	+	+ <sup>s</sup>	+		na	na	+		-	+	na
- pharynx	+	-	+ <sup>s</sup>	+ <sup>s</sup>	+		na	na	+		-	+	na
- renal capsule	na	-	+ <sup>s</sup>	+ <sup>s</sup>	+ <sup>s</sup>		+	na	-		-	+	-

a: recovered, b: no necropsy, m: male, f: female, na: not available, s: serous, p: purulent

(+: mild lesion, (+<sup>m</sup>): moderate lesion, (+<sup>s</sup>): severe lesion, (-): no detectable lesion

**Table 3** Microscopic lesions in buffaloes with MCF ( $n = 11$ ).

Case No.	1	2	3	4	5	7	8	9	11	12	13
<b>Vasculitis</b>											
Meninges	-	+ <sup>s</sup>	+ <sup>m</sup>	+	-	+	na	+	na	-	+
Eye	na	+	+ <sup>s</sup>	na	na	+	na	+	na	na	na
Heart	+	-	-	+ <sup>s</sup>	+	na	-	+	+	na	-
Lung	+ <sup>m</sup>	+ <sup>m</sup>	+ <sup>m</sup>	na	+	+	+	+	+	-	+ <sup>s</sup>
Liver	+	+ <sup>s</sup>	+	+ <sup>s</sup>	na	+	-	+	+	na	+
Kidney	+	+ <sup>s</sup>	+ <sup>s</sup>	+ <sup>s</sup>	+ <sup>s</sup>	+ <sup>m</sup>	+	+	+	na	+ <sup>s</sup>
Oral mucosa	na	+	+ <sup>m</sup>	+	na	na	na	+	na	na	na
Lymph node	+	+	+	+ <sup>m</sup>	-	na	+	+	+	+ <sup>m</sup>	+
Trachea	+	+ <sup>s</sup>	na	+ <sup>s</sup>	na	na	na	-	na	na	na
Spleen	+	+	+	+	+	na	-	+	+	na	-
Urinary bladder	na	na	+ <sup>m</sup>	+ <sup>m</sup>	na	+	+	+	-	na	+
Pampiniform plexus	na	na	+ <sup>s</sup>	+ <sup>s</sup>	na	+ <sup>m</sup>	na	na	na	na	na
Uterus / Ovary	na	na	-	-	+ <sup>m</sup>	-	na	+	na	na	+
Gastro-intestinal tract	+	na	+	+	+	na	-	+	+	na	na
Non-suppurative encephalitis	+	+ <sup>m</sup>	+	+	-	+	na	+	na	-	+
Non-suppurative meningitis	+	+	+	+	-	+	na	-	na	-	+
Non-suppurative myocarditis	+	-	+ <sup>s</sup>	+ <sup>s</sup>	+	na	+ <sup>m</sup>	+	+	na	+
Interstitial nephritis	+	+ <sup>m</sup>	+ <sup>s</sup>	+ <sup>s</sup>	+ <sup>s</sup>	+ <sup>m</sup>	+ <sup>s</sup>	+	+	na	+
Lymphoid infiltration in portal triads	+	+ <sup>m</sup>	+ <sup>s</sup>	+ <sup>m</sup>	na	+	+ <sup>s</sup>	+	+	na	+
Lymphoid necrosis of lymph nodes / spleen	+	+ <sup>m</sup>	+ <sup>m</sup>	+	+	na	-	+	-	+ <sup>m</sup>	-

na: not available, (+): mild lesion, (+<sup>m</sup>): moderate lesion, (+<sup>s</sup>): severe lesion, (-): no detectable lesion

## Discussion

The major clinical signs observed in our cases were anorexia and severe conjunctivitis, with oculonasal discharge. These clinical signs and the duration of illness were almost similar to previous reports of MCF in buffaloes and cattle (Liggitt and DeMartini, 1980<sup>a,b</sup>; Hoffmann et al., 1984). The findings of severe leucopenia consistently observed in our cases is strongly indicative of a viral infection. Bovine viral diarrhoea, infectious bovine rhinotracheitis or infectious keratoconjunctivitis were also considered as differential diagnoses, but the ocular lesions in these affected buffaloes, including lymphocytic infiltration in ciliary's body and vasculitis,

were the pathognomonic lesions of MCF (Whiteley et al., 1985). In contrast to MCF in cattle, corneal opacity was mild in our cases and was not found in all buffaloes. It was also observed that corneal opacity was not always seen in the MCF-affected buffaloes (Hoffmann et al., 1984). Generalised vasculitis is the major histopathological finding of MCF in cattle and other ruminants. These vascular changes consist of necrosis of the tunica media and mononuclear cell infiltration in the tunica adventitia (Liggitt and DeMartini, 1980<sup>a,b</sup>). In the current study, vasculitis was found in various organs, but fibrinoid degeneration was not consistently presented. This finding is in agreement with previous studies in cattle (Liggitt

and DeMartini, 1980<sup>a,b</sup>). In MCF-affected cattle, different degrees of haemorrhage are usually observed in the tracheal mucosa (Barker et al., 1993). Diphtheritic tracheitis, clearly seen in this study, is a rather uncommon finding of MCF in cattle. This finding may indicate a new exposure of the animals to the MCF virus. Non-suppurative myocarditis with severe vasculitis was common in this study. This finding is similar to a previous report of MCF in buffaloes (Hoffmann et al., 1984). In MCF-affected animals, kidneys were the major affected organs (Barker et al., 1993; Crawford et al., 2002). In the present study, interstitial nephritis with vasculitis was observed in all animals. The nodular skin lesion of case No. 11, consisting of vasculitis in subcutaneous tissue, is uncommon in MCF; however, it was earlier described in several studies (Holliman et al., 1994; Crawford et al., 2002; David et al., 2005). MCF has been recognised as an acute, highly fatal disease. Nevertheless, the recovery of affected animals has been reported in several studies (Milne and Reid, 1990; O'Toole et al., 1997; Penny 1998; Schultheiss et al., 1998) as well as in this study, indicating that some affected animals can survive, and probably develop a chronic form of the disease.

The pathogenesis of MCF is still unclear; many authors proposed that the vascular lesions are the result of immune-mediated mechanisms, including type III antigen-antibody complex and cell-mediated immunity (Plowright, 1990; Schock and Reid, 1996). Many studies showed that CD8+ T lymphocytes are the predominant cell type infiltrating the vascular lesions of MCF (Nakajima et al., 1992; 1994; Lagourette et al., 1997). Simon et al. (2003) have also demonstrated that intralesional CD8+ T lymphocytes were infected with OHV-2. In our study, MCF was likely to occur in adult buffaloes (more than 1 year), and this age-related occurrence has also been observed in cattle (Vanselow, 1980; Müller-Doblies et al., 2001). MCF outbreaks in cattle in some countries appeared to be seasonal (Müller-Doblies et al., 2001), suggesting an association with the lambing season (Plowright, 1990). The number of animals in our study

was not enough to draw any conclusion about seasonal occurrence; however, MCF in our cases frequently occurred between March and May. The housing of sheep and buffaloes together before the serious outbreak in herd B strongly indicates that close contact between these animals could contribute to the occurrence of MCF. However, the dairy cattle, Holstein Friesian, housed in the same farm, were not affected by MCF. This finding may suggest that swamp buffaloes are more susceptible to MCF than *Bos Taurus* (Hoffman and Young, 1989).

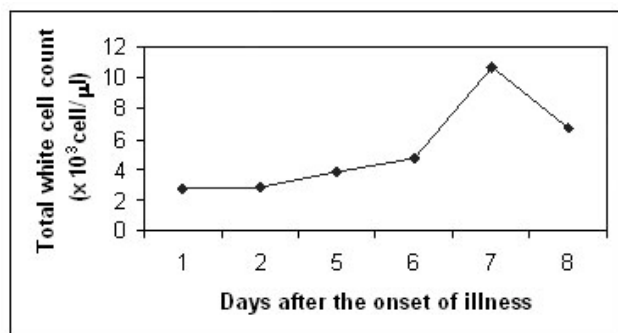
Diagnosis of MCF could be based on the pathognomonic lesion of generalised vasculitis as well as the ocular lesions. Various predilection organs, including the kidney, heart, lung, lymph nodes, brain, carotid rete, eye, intestine and vessels of the reproductive organs should be examined for the presence of vasculitis (Liggitt and DeMartini, 1980<sup>a,b</sup>; Barker et al., 1993). Additionally PCR, using primers specific to OHV-2, could also be carried out to confirm the aetiology, although it is not available in a routine laboratory. In this study, nested PCR performed on paraffin material from the lymph node and kidney of buffalo No. 11 revealed positive results, confirming the aetiology of OHV-2 in this case. Although PCR results of the remaining cases were not available, the similarity of histopathological findings should be enough to support the diagnosis of MCF in our cases.

In conclusion, MCF was a highly fatal disease of buffaloes in Thailand, characterised by lesions of generalised vasculitis. According to the clinical history of the buffaloes in this study, the outbreak of the disease may be associated with sheep. However, the carrier state of the sheep needs to be explored further.

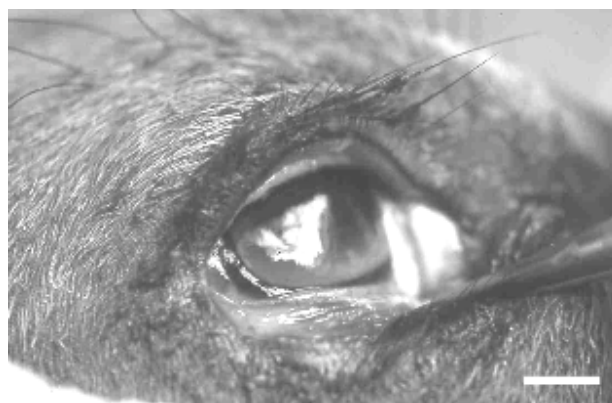### Acknowledgements

We are grateful to laboratory staff of the Large Animal Hospital, Chulalongkorn University, Nakhonpathom and Mr. Sopon Wuthara for his technical assistance. We thank also the staff of Pathology Department, Faculty of Veterinary Science, Chulalongkorn University for diagnostic assistance.

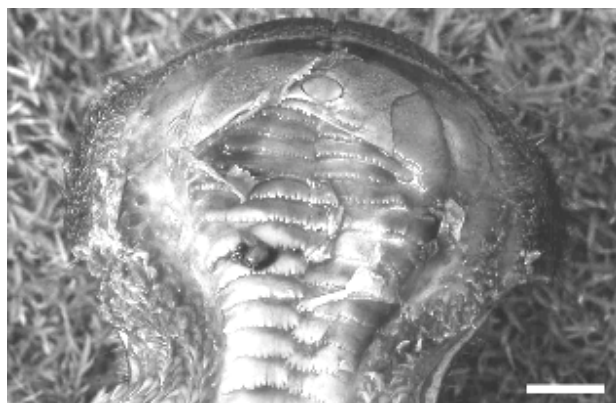



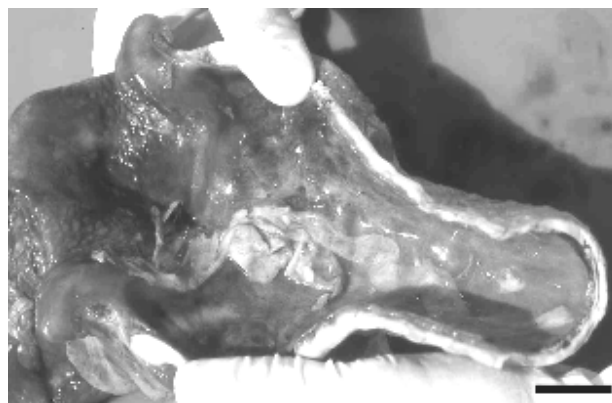
**Figure 1** Total white blood count of case No. 6. Blood samples were collected on days 1, 2, 5, 6, 7 and 8 after the onset of illness.



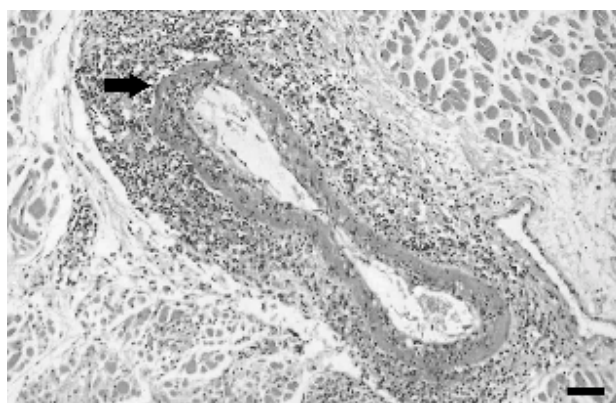
**Figure 2** Corneal opacity with severe conjunctivitis in buffalo case No. 3. Bar = 2 cm.



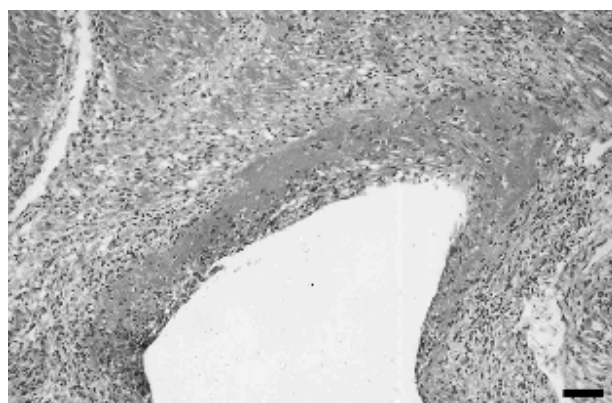
**Figure 3** Palate and dental pad. Erosion of the oral mucosa (case No. 3). Bar = 1.6 cm.



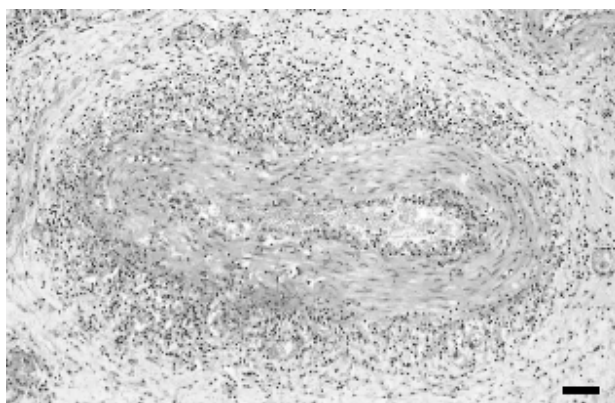
**Figure 4** Trachea. Diphtheritic membrane covered the tracheal mucosa (case No. 3). Bar = 3 cm.



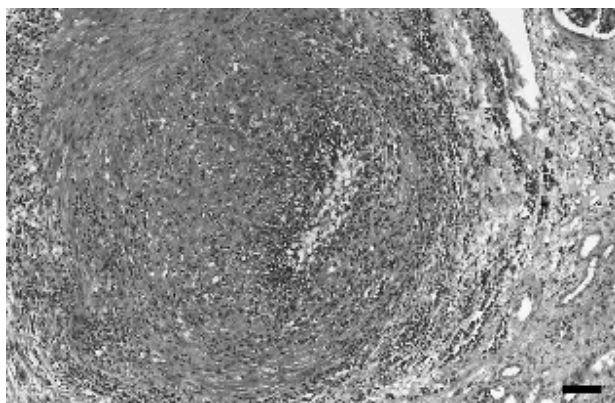
**Figure 5** Arteritis of the ocular muscle (case No. 9). Infiltration of lymphocytes in the tunica media and adventitia, with fibrinoid degeneration (arrow). HE stain. Bar = 100 μm.



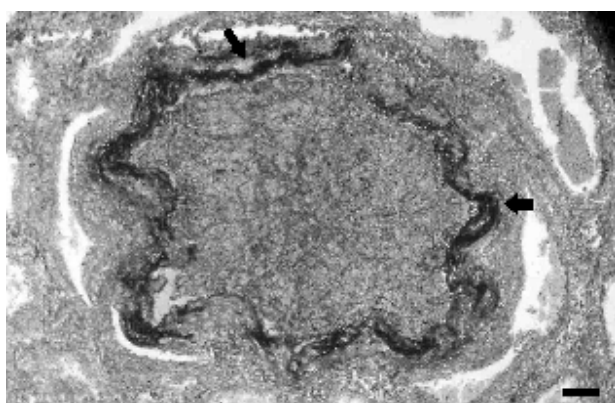
**Figure 6** Heart. Vasculitis with fibrinoid degeneration of a branch of the coronary artery (case No. 9). HE stain. Bar = 100 μm.



**Figure 7** Kidney. Severe chronic arteritis in the renal medulla, consisting of tunica media hyperplasia and lymphocytic infiltration in the adventitia and the media (case No. 11). HE stain. Bar = 100  $\mu$ m.



**Figure 8** Perivasculitis of the pampiniform plexus (case No. 7). Marked infiltration of lymphocytes in the tunica adventitia. HE stain. Bar = 100  $\mu$ m.



**Figure 9** Vasculitis with fibrinoid degeneration of the pampiniform plexus (case No. 7). Deep-blue colour represents the positive staining of PTAH in the subintimal layer (arrow). PTAH stain. Bar = 150  $\mu$ m.

## References

- Banlunara W., Tantilertcharoen, R. and Teankum, K. 2003. Sheep-associated malignant catarrhal fever virus induced obliterative arteriopathy in a Thai swamp buffalo. Proceedings of the 11<sup>th</sup> International Symposium of the World Association of Veterinary Laboratory Diagnosticians. Bangkok, Thailand, November 9-13: 74-75.
- Barker, I.K., Van Dreumel, A.A. and Palmer, N. 1993. Malignant catarrhal fever In: Pathology of Domestic Animal. 4<sup>th</sup> ed. K.V.F. Jubb, P.C. Kennedy and N. Palmer (eds.) New York: Academic Press. 163-173.
- Crawford, T.B., Li, H., Rosenberg, S.R., Norhausen, R.W. and Garner M.M. 2002. Mural folliculitis and alopecia caused by infection with goat-associated malignant catarrhal fever virus in two sika deer. J. Am. Vet. Med. Assoc. 221(6): 843-847.
- David, D., Dagoni, I., Garazi, S., Perl, S. and Brenner, J. 2005. Two cases of the cutaneous form of sheep-associated malignant catarrhal fever in cattle. Vet. Rec. 156 (4): 118-120.
- Hill, F.I., Arthur, D.G. and Thompson, J. 1993. Malignant catarrhal fever in a swamp buffalo (*Bubalus bubalis*) calf in New Zealand. N. Z. Vet. J. 41(1): 35-38.
- Hill, F.I., Death, A.F., Wyeth, Budding T.K. and Vautier, J. 1992. Haematology and biochemistry reference values for clinically normal swamp buffalo (*Bubalus bubalis*). Buffalo J. 1: 57-63.
- Hoffmann, D., Soeripto, S., Sobironingsih, S., Campbell, R.S.F. and Clarke, B.C. 1984. The clinico-pathology of a malignant catarrhal fever syndrome in the Indonesian swamp buffalo (*Bubalus bubalis*). Aust. Vet. J. 61(4): 108-112.
- Hoffmann, D. and Young, M.P. 1989. Malignant catarrhal fever. Aust. Vet. J. 66 (12): 405-406.
- Holliman, A., Urquhart, S.R. and Munro, R. 1994. An unusual manifestation of malignant catarrhal fever in a yearling bull. Vet. Rec. 135 (1): 13-14.

- Lagourette, P., Delverdier, M., Bourges, A.N., Amardeilh, M.F., Schelcher, F., Cabanie, P. and Espinasse, J. 1997. Immunohistochemical study of lymphoid cell reactions in four cattle affected with malignant catarrhal fever. *Eur. J. Vet. Pathol.* 3 (2): 73-78.
- Li, H., Keller, J., Knowles, D.P. and Crawford, T.B. 2001. Recognition of another member of the malignant catarrhal fever virus group: an endemic gamma-herpesvirus in domestic goats. *J. Gen. Virol.* 82 (1): 227-232.
- Li, H., Shen, D.T., O'Toole, D., Knowles, D.P., Gorham, J.R. and Crawford, T.B. 1995. Investigation of sheep-associated malignant catarrhal fever virus infection in ruminants by PCR and competitive inhibition enzyme-linked immunosorbent assay. *J. Clin. Microbiol.* 33 (8): 2048-2053.
- Liggitt, H.D. and DeMartini, J.C. 1980<sup>a</sup>. The pathomorphology of malignant catarrhal fever. I. Generalized lymphoid vasculitis. *Vet. Pathol.* 17 (1): 58-72.
- Liggitt, H.D. and DeMartini, J.C. 1980<sup>b</sup>. The pathomorphology of Malignant catarrhal fever. II. Multisystemic epithelial lesions. *Vet. Pathol.* 17 (1): 73-83.
- Milne, E.M. and Reid, H.W. 1990. Recovery of cow from malignant catarrhal fever. *Vet. Rec.* 126 (26): 640-641.
- Müller-Doblies, U.U., Egli, J., Li, H., Braun, U. and Ackermann, M. 2001. Malignant catarrhal fever in Switzerland. 1. Epidemiology. *Schweiz. Arch. Tierheilkd. (German)* 143 (4): 173-183.
- Nakajima, Y., Momotani, E., Ishikawa, Y., Muratami, T., Shimura, N. and Onuma, M. 1992. Phenotyping of lymphocytes subsets in the vascular and epithelial lesions of a cow with malignant catarrhal fever. *Vet. Immunol. Immunopathol.* 33 (3): 279-284.
- Nakajima, Y., Ishikawa, Y., Kadota, K., Kodama, M. and Honma, Y. 1994. Surface marker analysis of the vascular and epithelial lesions in cattle with sheep-associated malignant catarrhal fever. *J. Vet. Med. Sci.* 56 (6): 1065-1068.
- O'Toole, D., Li, H., Miller, D., Williams, W.R. and Crawford, T.B. 1997. Chronic and recovered cases of sheep-associated malignant catarrhal fever in cattle. *Vet. Rec.* 140 (20): 519-524.
- Penny, C. 1998. Recovery of cattle from malignant catarrhal fever. *Vet. Rec.* 142(9): 227.
- Pierson, R.E., Thake, D., McChesney, A.E. and Storz, J. 1973. An epizootic of malignant catarrhal fever in feedlot cattle. *J. Am. Vet. Med. Assoc.* 163 (4): 349-350.
- Plowright, W. 1990. Malignant catarrhal fever virus. In : Virus infections of ruminants. Z. Dinter and B. Morein. (ed) New York: Elsevier Science Publishers BV. 123-150.
- Schock, A. and Reid, H.W. 1996. Characterisation of the lymphoproliferation in rabbits experimentally affected with malignant catarrhal fever. *Vet. Microbiol.* 53 (1-2): 111-119.
- Schultheiss, P.C., Collins, J.K., Austgen, L.E. and DeMartini, J.C. 1998. Malignant catarrhal fever in bison, acute and chronic cases. *J. Vet. Diagn. Invest.* 10 (3): 255-262.
- Schultheiss, P.C., Collins, J.K., Spraker, T.R. and DeMartini, J.C. 2000. Epizootic malignant catarrhal fever in three bison herds: differences from cattle and association with ovine herpesvirus-2. *J. Vet. Diagn. Invest.* 12 (6): 497-502.
- Selman, I.E., Wiseman, A., Murray, M. and Wright, N.G. 1974. A clinico-pathological study of bovine malignant catarrhal fever in Great Britain. *Vet. Rec.* 94 (21): 483-490.
- Simon, S., Li, H., O'Toole, D., Crawford, T.B. and Oaks, J.L. 2003. The vascular lesions of a cow and bison with sheep-associated malignant catarrhal fever contain ovine herpesvirus 2-infected CD8+ lymphocytes. *J. Gen. Virol.* 84 (8): 2009-2013.
- Singh, G. and Gill, B.S. 1995. An outbreak of malignant catarrhal fever in buffaloes and cattle in India. *Buffalo J.* 1: 57-59.

- Tham, K.M. 1997. Molecular and clinicopathological diagnosis of malignant catarrhal fever in cattle, deer and buffalo in New Zealand. *Vet. Rec.* 141 (12): 303-306.
- Vanselow, B.A. 1980. An epizootic of bovine malignant catarrh in Malaysia. *Vet. Rec.* 107 (1): 15-18.
- Whiteley, H.E., Young, S., Liggitt, H.D. and DeMartini, J.C. 1985. Ocular lesions of bovine malignant catarrhal fever. *Vet. Pathol.* 22 (3): 219-225.
- Wiyono, A., Baxter, S.I., Saepulloh, M., Damayanti, R., Daniels, P. and Reid, H.W. 1994. PCR detection of ovine herpesvirus-2 DNA in Indonesian ruminants-normal sheep and clinical cases of malignant catarrhal fever. *Vet. Microbiol.* 42 (1): 45-52.