

## **Hemangiosarcoma of the Nictitating Membrane as Seen in Two Great Danes (a Case Report)**

**Atichat Brahmasa<sup>1\*</sup> Naline Tuntivanich<sup>1</sup>**

**Pranee Tuntivanich<sup>1</sup> Anudep Rungsipipat<sup>2</sup>**

### **Abstract**

**Hemangiosarcoma of the nictitating membrane of two Great Dane dogs is reported. Treatment was successfully carried out by amputation of the nictitan. No recurrence of the mass or pulmonary metastasis was evident within a period of twelve months after the treatment.**

**Keywords :** Hemangiosarcoma, endothelial vascular tumor, nictitating membrane, dog.

<sup>1</sup> Department of Surgery, <sup>2</sup> Department of Pathology, Faculty of Veterinary Science, Chulalongkorn University, Bangkok 10330, Thailand.

\*Corresponding author



## บทคัดย่อ

# เนื้องอกชนิดฮีแมงจิโอซาร์โคมาของหนังตาที่สามในสุนัขพันธุ์เกรทเดน 2 ตัว : รายงานสัตว์ป่วย

อดิชาติ พรหมสา<sup>1\*</sup> นลินี ตันตวนิช<sup>1</sup> ปราณิ ตันตวนิช<sup>1</sup> อนุเทพ รังสีพิพัฒน์<sup>2</sup>

รายงานการรักษาเนื้องอกชนิดฮีแมงจิโอซาร์โคมาของหนังตาที่สามในสุนัขพันธุ์เกรทเดน 2 ราย โดยการตัดหนังตา ที่สามส่วนที่เป็นโรครอก ไม่พบการกระจายของโรค และจากการติดตามผลภายหลังการรักษาเป็นเวลา 12 เดือน ไม่พบการ เกิดขึ้นมาใหม่อีก

**คำสำคัญ:** ฮีแมงจิโอซาร์โคมา, เนื้องอกผนังหลอดเลือด, หนังตาที่สาม, สุนัข

<sup>1</sup> ภาควิชาสัตวศาสตร์ <sup>2</sup> ภาควิชาพยาธิวิทยา คณะสัตวแพทยศาสตร์ จุฬาลงกรณ์มหาวิทยาลัย ปทุมวัน กรุงเทพฯ 10330

\* ผู้รับผิดชอบบทความ

## Introduction

Hemangiosarcoma, a malignant neoplasm of vascular origin, accounts for approximately 2% of cutaneous tumors in dogs and cats (Dubielzig, 2002). Hemangiosarcoma is prevalent in male German Shepherd dogs (Kleine *et al.*, 1970), especially those greater than five years of age (NG and Mills, 1985). Conjunctival and nictitan tumors of vascular, endothelial origin have been reported in dogs (Peiffer *et al.*, 1978), cats (Multari *et al.*, 2002), and horses (Vestre *et al.*, 1982). The morphology of the tumors varied from an extremely well differentiated cavernous dilatation of the blood vessel to a highly cellular and anaplastic microocular tumor, with local invasion.

This is the first case report of hemangiosarcoma of the nictitating membrane in a Great Dane.

## History

### Case 1

A 5-year old, male, Great Dane was referred, with a history of prior treatment, to the Ophthalmology Clinic, Small Animal Teaching Hospital, Faculty of Veterinary Science, Chulalongkorn University. The

dog was presented with a proliferative, bright red mass (0.4 cm x 0.8 cm x 0.4 cm), which had been present-for three months, with occasional bleeding at the palpebral conjunctiva of the left eye nictitan. Treatment with systemic and topical antibiotics in combination with corticosteroids had no effect, and the lesion became enlarged. Thoracic radiographs revealed no evidence of any tumor metastasis to the lung. A hemogram showed only mild anemia and a left shift in the neutrophil count. (Table 1).

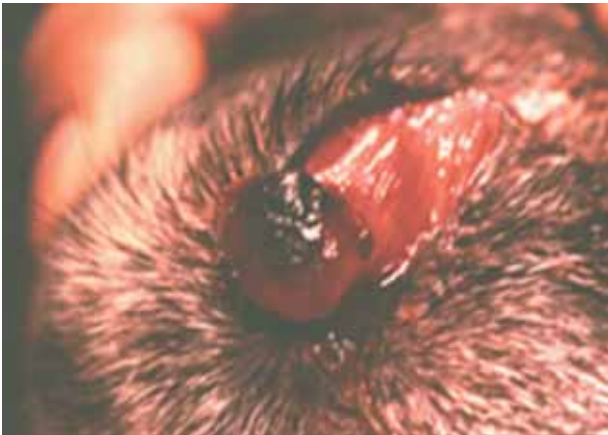### Case 2

A 7-year old male Great Dane was referred to the Ophthalmology Clinic, Small Animal Teaching Hospital, Faculty of Veterinary Science, Chulalongkorn University. The dog was presented with a dark red mass, 0.7 cm in diameter, which appeared six months previously, at the palpebral conjunctiva of the left eye nictitan (Fig. 1). The dog was treated with topical and systemic antibiotics combined with a corticosteroid with no response. No evidence of metastasis was noted from the thoracic radiographs. Hematological findings were similar to those of case 1 (Table 1).

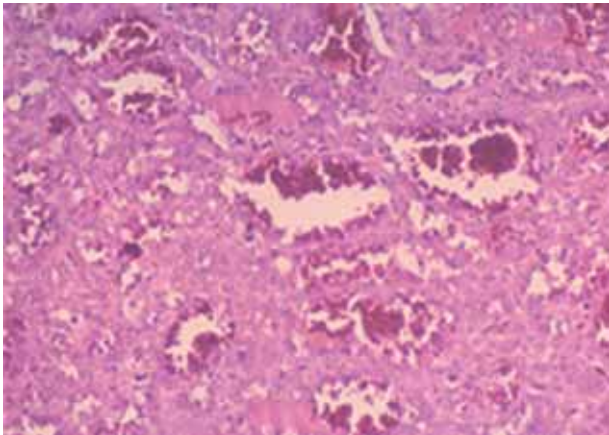
**Table 1** Hematological values from a complete blood count and the blood biochemistry profiles of two Great Dane dogs.

Title	Dog 1	Dog 2	Normal ranges*
WBC (cell/mm <sup>3</sup> )	12.05 x 10 <sup>3</sup>	12.5x10 <sup>3</sup>	6-15x10 <sup>3</sup>
Segmented neutrophil (cell/mm <sup>3</sup> )	7.47 x 10 <sup>3</sup>	7.5x10 <sup>3</sup>	3-11.5x10 <sup>3</sup>
Band cell (cell/mm <sup>3</sup> )	1.33 x 10 <sup>3</sup>	1.38x10 <sup>3</sup>	0-0.3x10 <sup>3</sup>
Eosinophil (cell/mm <sup>3</sup> )	0.72 x 10 <sup>3</sup>	0.62x10 <sup>3</sup>	0.1-1.25x10 <sup>3</sup>
Monocyte (cell/mm <sup>3</sup> )	0.36 x 10 <sup>3</sup>	0.50x10 <sup>3</sup>	0.15-1.35x10 <sup>3</sup>
Lymphocyte (cell/mm <sup>3</sup> )	2.17 x 10 <sup>3</sup>	0.25x10 <sup>3</sup>	1-4.8x10 <sup>3</sup>
RBC (cell/mm <sup>3</sup> )	4.61 x 10 <sup>6</sup>	4.52x10 <sup>6</sup>	5.5-8.5x10 <sup>6</sup>
Hematocrit (%)	27	26	37-55
Hemoglobin (g/dl)	8.5	7.5	12-18
BUN (mg/dl)	11	12	8.8-25.9
AST (IU)	21.12	20	8.9-48.5
ALT (IU)	10.5	10.2	8.2-57.3

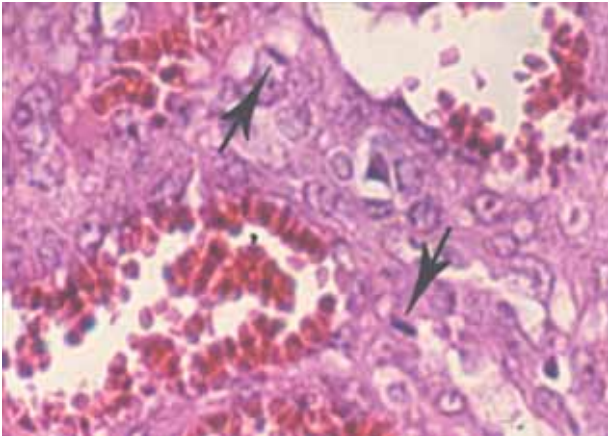
\*Jain, 1993.



**Figure 1** Hemangiosarcoma of the nictitating membrane. A solid, proliferative, dark red mass was located at the palpebral conjunctiva of the left nictitan in a 7 year-old Great Dane.



**Figure 2** Histopathology of hemangiosarcoma at low magnification. Tumor consists of proliferated angioblasts arranged in tumor cell sheaths with irregular arrangement of blood filled spaces. (H&E, x 100).



**Figure 3** Histopathology of hemangiosarcoma at high magnification. Mitotic figures (arrows) are shown aligning vascular spaces and are surrounded with pleomorphic cells. (H&E, x200).



### **Treatment**

The tumors in both cases were surgically removed, under general anesthesia. Topical antibiotics and a corticosteroid were administered twice daily for five days, postoperatively. Three to four months after surgery a 0.5 cm. diameter mass was found in both cases, however, no evidence of pulmonary metastasis was observed radiographically. An amputation of the affected nictitan was therefore performed.

### **Histopathology**

The mass was excised, fixed in 10% neutral buffered formalin, embedded in paraffin, sectioned to 5 µm thickness, and stained with Hematoxylin & Eosin (H&E). The tumor originated from the conjunctiva in the subconjunctival epithelial space. Part of conjunctival epithelium was necrotic and hemorrhagic. Conjunctival stroma was scant in thickness. The mass consisted of irregularly arranged proliferated angioblasts and blood-filled spaces (Fig. 2). Narrow sheets of the proliferated tumor cells were noticed in some areas. Pleomorphic neoplastic cells were seen, plum to spindle in shape, with both oval and round nuclei, indicating that vascular tissue was the origin of the tumor. Mitotic figures were numerous, aligning the vascular spaces and indicating malignancy (Fig. 3).

### **Results and Discussion**

Primary neoplasms of the nictitating membrane are rare in dogs. Hemangiomas are more commonly involved in the conjunctiva rather than in the nictitating membrane (Severin, 1995). Tumors found at the nictitan are frequently located at the margin rather than at the limbus (Peiffer et al., 1999). Amputation of the nictitan is the recommended primary treatment. In this report, histopathological characteristics of a solid conjunctival mass were similar to fibrosarcoma, cavernous hemangioma,

poorly differentiated sarcoma, and chronic granulation tissue. Special stains, such as Masson Trichrome and phosphotungstic acid hematoxylin, should be considered for the differential diagnosis of fibrosarcoma, leiomyosarcoma, and osteosarcoma. A positive immunoreactivity test for factor VIII should be used to diagnose hemangiosarcoma, some lymphangiomas, and lymphangiosarcoma (Goldschmidt and Hendrick, 2002).

Recurrent masses developed within a few months in both cases following the initial operation, demonstrating the aggressive behavior of this highly malignant tumor of the vascular endothelial cells. However, recurrence and other ocular abnormalities were not found in both cases during a follow-up period of twelve months after the second operation, and there was no evidence of metastasis to the lungs on the thoracic radiographs, and the dogs remained healthy throughout the 12-month follow-up period. Cutaneous hemangiosarcoma is less aggressive and animals have longer survival times than when affected with visceral hemangiosarcoma. Rapid metastasis of a hemangiosarcoma usually occurs in the visceral organs, particularly the liver, lung and spleen (Brown et al., 1985; Srebernik and Appleby, 1991; Goldschmidt and Hendrick, 2002), leading to a poor prognosis. Most affected dogs did not survive longer than eight months after diagnosis (Brown et al., 1985; Goldschmidt and Hendrick, 2002). Canine cutaneous hemangiosarcoma is commonly associated with several hemostatic abnormalities such as uncontrollable hemorrhage, thrombocytopenia, and disseminated intravascular coagulopathy (Goldschmidt and Hendrick, 2002). Complete hemograms and coagulation disorders, in affected dogs, should be investigated for a prognosis and for possible treatment options (Randal and Fox, 2002). Though the cause of hemangiosarcoma in these two Great Danes was not known, cumulative exposure to ultraviolet light is believed to be one

of the risk factors associated with vascular tumors (Peiffer et al., 1999; Dubielzig, 2002). Feline hemangiosarcoma of the nictitans has been successfully treated with a combination of surgery and cryotherapy (Multari et al., 2002). To our knowledge, this is the first report of hemangiosarcoma of the nictitating membrane in Great Danes. Early detection, diagnosis and amputation of the affected nictitating membrane led to successful treatment in these two dogs.

### Acknowledgment

We gratefully thank Dr. Boonmee Sunyasootcharee for his histopathological interpretation, and Dr. Duangnarumon Prachankhadee and Michelle Curcio for their proof reading.

### References

- Brown, N.O., Patnaik, A.K. and MacEwen, E.G. 1985. Canine hemangiosarcoma Retrospective analysis of 104 cases. *J. Am. Vet. Med. Assoc.* 186 (1): 56-58.
- Dubielzig, R.R. 2002. Tumors of the eye. In: *Tumors in Domestic Animals*. 4<sup>th</sup> ed. D.J. Meuten (ed.). Ames: Iowa State Univ. Press. 99-101.
- Goldschmidt, M.H. and Hendrick, M.J. 2002. Tumors of the skin and soft tissues. In: *Tumors in Domestic Animals*. 4<sup>th</sup> ed. D.J. Meuten (ed.). Ames: Iowa State Univ. Press. 743.
- Jain, N.C. 1993. *Essentials of Veterinary Hematology*. Philadelphia: Lea & Febiger. 417 pp.
- Kleine, L.J., Zook, B.C. and Munson, T.O. 1970. Primary cardiac hemangiosarcomas in dogs. *J. Am. Vet. Med. Assoc.* 157: 333-337.
- Multari, D., Vascellari, M. and Mutinelli, F. 2002. *Vet. Ophthalmol.* 5 (4): 273-276.
- NG, C.Y. and Mills, J.N. 1985. Clinical and haematological features of haemangiosarcoma in dogs. *Aus. Vet. J.* 62 (1) : 1-4.
- Peiffer, R.L. Jr, Dencan, J. and Terrell, T. 1978. Hemangioma of the nictitating membrane in a dog. *J. Am. Vet. Med. Assoc.* 172: 832-833.
- Peiffer, R.L., Wilcock, B.P. and Debielzig, R.R. 1999. Fundamentals of pathology. In: *Veterinary Ophthalmology*. 3<sup>rd</sup> ed. K.N. Gelatt (ed). Philadelphia: Lippincott Williams & Wilkins Co. 355-425.
- Randal, C.T. and Fox, L.E. 2002. Tumors of the Skin and Subcutis. In: *Cancer in Dogs and Cats: Medical and Surgical Management*. 2<sup>nd</sup> ed. W.B. Morrison (ed). Jackson: Teton New Media. 481-482.
- Severin, G. 1995. *Severin's Veterinary Ophthalmology Notes*, 3<sup>rd</sup> ed. Fort Collins: Colorado State Univ. Press. 218, 271.
- Srebernik, N. and Appleby, E.C. 1991. Breed prevalence and sites of haemangioma and haemangiosarcoma in dogs. *Vet. Rec.* 129: 408-409.
- Vestre, W.A., Turner, T.A. and Carlton, W.W. 1982. Conjunctival hemangioma in a horse. *J. Am. Vet. Med. Assoc.* 180: 1481-1482.



54

