

The Use of Porcine Small Intestinal Submucosa in Ten Cases of Canine Corneal Staphyloma

Nalinee Tuntivanich* Kumpanart Soontornwipart Pranee Tuntivanich

Abstract

Porcine small intestinal submucosa biomaterial was used to repair corneal staphyloma in 10 dogs. There was no evidence of leakage of aqueous humor and graft rejection following PSIS grafting. Anterior synechia was presented in 25-50% of the corneal area. Granulation tissue vanished within 50 days of the operation. Even though scar formation and anterior synechia were observed at the end of the study, all dogs had vision.

Keywords : Porcine small intestinal submucosa, staphyloma, cornea, canine.

Department of Surgery, Faculty of Veterinary Science, Chulalongkorn University, Bangkok, Thailand.

*Corresponding author.

บทคัดย่อ

การรักษาโรคม่านตาดำปื้นที่กระจกตาสุนัข 10 ตัว โดยใช้วัสดุที่ทำจากชั้นเยื่อบุลำไส้สุกร

นลินี ตันตวนิช* กัมปนาท สุนทรวิภาต ปราณี ตันตวนิช

รายงานการใช้วัสดุที่ทำจากเยื่อเมือกลำไส้เล็กสุกรเย็บปิดแผลที่กระจกตาที่มีการปื้นของม่านตาดำในสุนัขจำนวน 10 ตัว ผลของการรักษาไม่พบรอยรั่วของน้ำจากช่องหน้าม่านตาและไม่พบการลอกหลุดของแผ่นวัสดุ มีการยึดของม่านตาดำติดกับกระจกตาร้อยละ 25-50 ของพื้นที่กระจกตา การก่อให้เกิดจันใหม่ที่กระจกตาทายไปภายใน 50 วันหลังผ่าตัด ถึงแม้ว่าผลเป็นจะปรากฏบนกระจกตาและยังมีการยึดของม่านตาดำติดกับกระจกตา สุนัขทุกตัวสามารถมองเห็นได้เมื่อสิ้นสุดการศึกษา

คำสำคัญ: เยื่อเมือกลำไส้สุกร ม่านตาดำปื้น กระจกตา สุนัข

ภาควิชาสัตยศาสตร์ คณะสัตวแพทยศาสตร์ จุฬาลงกรณ์มหาวิทยาลัย
*ผู้รับผิดชอบบทความ

Introduction

Canine deep corneal ulceration can cause corneal perforation and possibly corneal staphyloma leading to impaired vision, if treatment is inappropriately chosen. Surgical treatment is strongly recommended to repair a perforated cornea (Severin, 1995). However, there are a variety of surgical techniques from which to choose based on several factors such as the physiological characteristics of the corneal lesion (size, depth, location and duration), practical skill, availability of instruments and materials and financial consideration.

Corneal grafts using alternative grafting materials are more commonly used than autografts because autografts have a high rate of rejection. There is also a limitation of donor tissues once autograft is considered. Porcine small intestinal submucosa (PSIS) is a degradable, collagen-based biomaterial derived from the submucosal layer of porcine small intestine. Its non-immunogenic and regenerative biological

characteristics provide a bio-scaffold for site-specific tissue remodeling in many types of tissue (Badylak et al., 1989; Kropp et al., 1995; Matheny et al., 2000; Badylak et al., 2002). PSIS biomaterial has been used for grafting a full thickness corneoscleral defect in a dog (Lewin, 1999), deep corneal ulcers in cats (Featherstone and Sansom, 2000) and corneal stromal abscess in horses (Vygantas and Whitley, 2003), all of which had no graft rejection.

The purpose of this study was to determine the clinical results of corneal grafting performed on canine corneal staphyloma using a porcine small intestinal submucosa biomaterial.

Materials and Methods

Animals: Ten dogs of various breeds were presented at the veterinary ophthalmology clinic, small animal teaching hospital, Chulalongkorn University, Bangkok, Thailand. They were diagnosed with corneal

staphyloma (Fig. 1). The duration of the lesion varied from 1 to 120 days. Some dogs had received previous medical treatment.

Anesthesia: Dogs were premedicated with acepromazine maleate combined with atropine sulfate followed by an induction with thiopental sodium. Anesthesia was performed using fluothane delivered in oxygen and nitrous oxide.

Corneal wound preparation: Non-viable tissue mostly iris protruding from the corneal wound edge was removed (Fig. 2). Where necessary, protruding iris was cut with a cautery. Afterwards the iris was gently and carefully pushed back into the anterior chamber and the wound edge was debrided and prepared as a recipient bed for the PSIS biomaterial.

Grafting: PSIS biomaterial (Vet BioSist™, Cook Veterinary Products, Australia) (Fig. 3) was rehydrated in Lactated Ringer's solution for 3 minutes prior to placement on the corneal lesion (Fig. 4), and then sutured to the corneal surface with 8-0 polyglactin 910

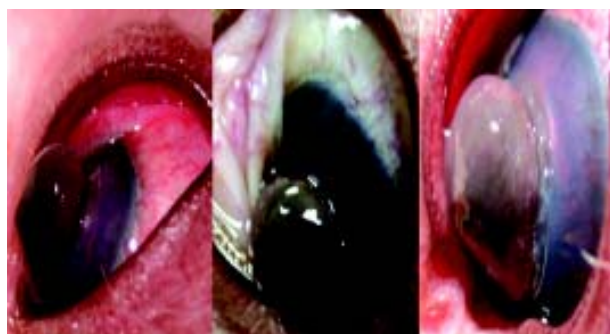

Figure 1 Canine Corneal Staphyloma. Corneal perforation with iridal prolapse shown with varying degrees of severity in conjunction with other ophthalmoscopic signs; conjunctivitis (1a), chemosis (1b), and a complete anterior synechia (1c).

(Vicryl , Ethicon) using an interrupted suture pattern (Fig. 5). The cornea and the PSIS biomaterial were kept moist at all times during grafting with 1:10,000 adrenaline solution. A small amount of air was injected into the anterior chamber to maintain its shape and to prevent the iris from re-attaching to the cornea. A third eyelid flap was created by suturing the nictitating membrane to the bulbar conjunctiva and it was left for 14 days to protect the grafted area (Fig. 6).

Post operating treatment: 16% gentamicin and 1% atropine (Isopto Atropine , Alcon) were topically administered daily, in conjunction with an intramuscular administration of antibiotics and corticosteroids for the first 7 days. Artificial tears were then topically administered the day after. After the third eyelid flap had been removed, a combination of neomycin, polymyxin and dexamethasone (Maxitrol , Alcon) was additionally administered. Topical 0.1% fluorometholone acetate (Flarex , Alcon) was given after the dark red color on the grafted area had disappeared.

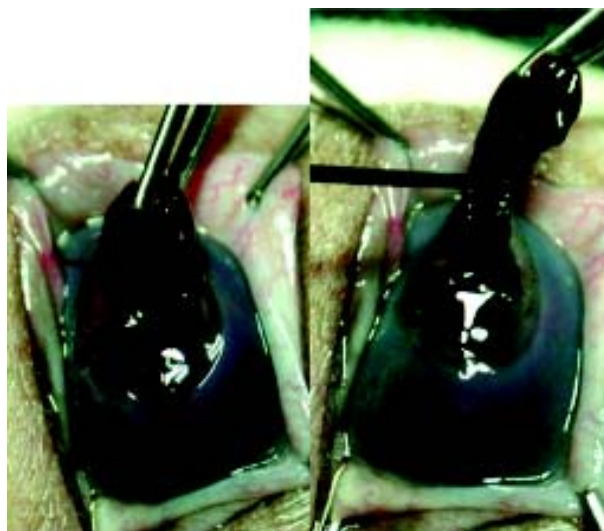


Figure 2 Corneal Wound Preparation. Tension at the wound edge was released (2a) followed by removal of the exposed non-viable tissue along with a blood clot by cauterization (2b). Caution is required to prevent bleeding.




Figure 3 PSIS biomaterial. A bio-degradable, collagen-based material derived from the submucosal layer of porcine small intestine; Vet BioSist™, Cook Veterinary Product, Inc. (Australia).

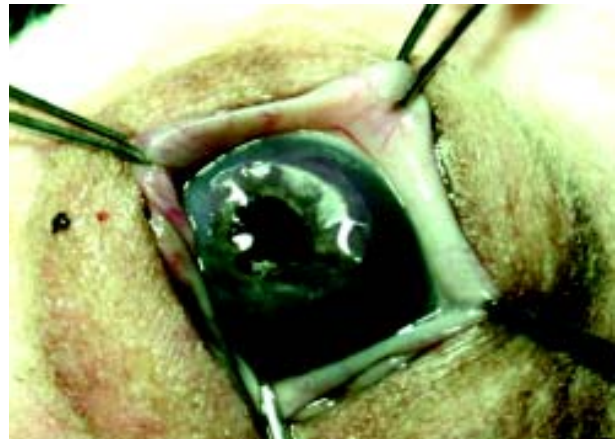


Figure 4 PSIS Grafting. PSIS biomaterial was rehydrated for 3 min. in LRS prior to a careful placement on the corneal lesion that was freshly debrided.

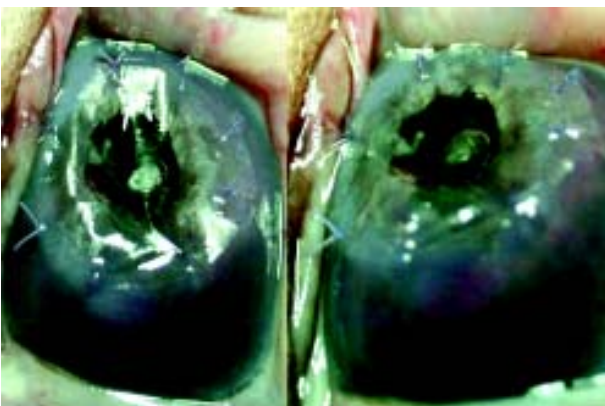


Figure 5 PSIS-Grafted Cornea. Front view (5a) and lateral view (5b). PSIS biomaterial was sutured to the cornea using 8-0 polyglactin 910 suture material (Vicryl, Ethicon). Graft and ocular surface were kept moist for duration of surgical procedure.

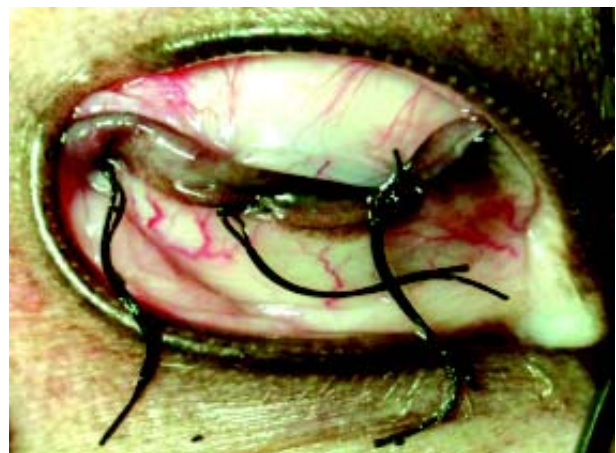

Figure 6 Protection of Corneal Graft. PSIS-corneal graft was protected for 14 days by suturing the nictitating membrane to the bulba conjunctiva.

Results

The history and ophthalmologic signs of all the dogs before and after PSIS biomaterial application are shown in Table 1. PSIS biomaterial was still noticeable in all the dogs after the nictitating membrane had been removed from bulbar conjunctiva. It was completely absorbed in most dogs at approximately 1 month postoperatively except for 1.5 month in dog 2. All dogs had a positive menace response after grafting. The menace response was positive at 1 month postoperatively in nearly all dogs and slightly delayed at 2 months in dog 2, 3 and 9. The degrees of ocular discomfort(photophobia, lacrimation) declined over the post operative period.

Removal of the third eyelid flap at 14 days postoperatively revealed granulation tissue(dark red appearance) on the grafted area (Fig. 7) in all dogs. Marked granulation tissue was noted in dog 4 whereas it was minimal in dog 7. Corneal blood vessels were also revealed around the grafted area and at the corneal limbus (Fig. 8). Corneal vascularization gradually decreased over time. Subsequent to the disappearance of corneal blood vessels around the grafted area, corneal blood vessels at the corneal limbus could still be noticed at the end of the study in most dogs. Scar formation was seen in all the dogs (Fig. 9) after the granulation tissue had vanished. However scars became smaller in size and faded in color towards the last re-evaluation. Hyphema noted preoperatively in dog 2, 5 and 8 was not noticed in any of these dogs after PSIS grafting.

Discussion

This study reports the success of using PSIS biomaterial to repair canine corneal staphyloma with a diameter of corneal lesion up to 2 cm. The disappearance of PSIS biomaterial is unlikely to be due to graft rejection but due to graft absorption. Graft absorption can be explained by the ability of the PSIS biomaterial to incorporate itself into host tissue and

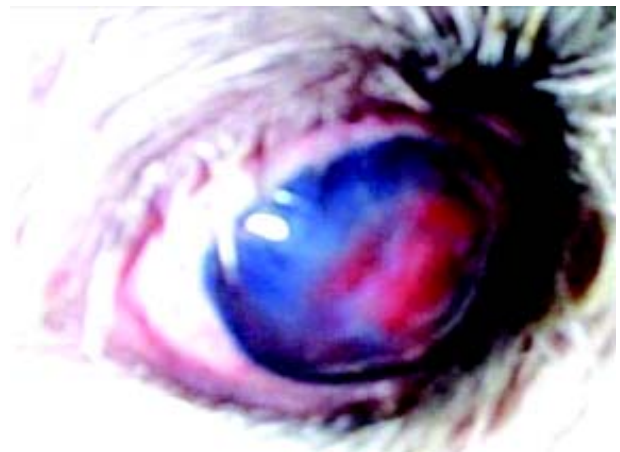


Figure 7 PSIS-Grafted Cornea at 2 Weeks Post-Op. Granulation tissue, corneal edema, and corneal vascularization were observed, after the nictitan was released.

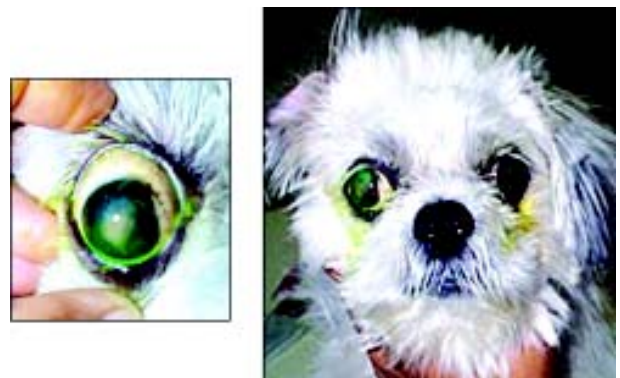

Figure 8 PSIS-Grafted Cornea at 3 Weeks Post-Op. Granulation tissue had disappeared leaving a corneal scar (8a). Dog demonstrated mild degree of ocular discomfort. Fluoresceine staining revealed a superficial corneal ulcer (8b).

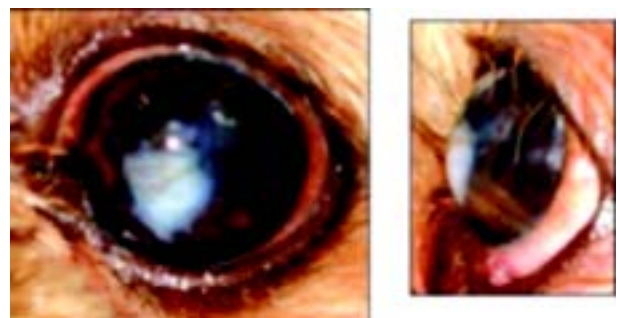


Figure 9 PSIS-Grafted Cornea at 3 Months Post-Op. Corneal scar is present with a mild degree of corneal pigmentation (9a; front view). Anterior synechia is noted (9b; lateral view).

Dog No	Breed	Age	Sex	Eye	Diameter of lesion (cm)	Duration of lesion (day)	Pre-operation			Post-operation			
							MN Res	Ant Sync	O.Disc	MN Res	Ant Sync	O.Disc	Gr.Dis (day)
1	Shih Tzu	4 yrs.	M	OD	1	3	-	+	+	+	-	35	20
2	Shih Tzu	2 yrs.	M	OD	1	2	-	++++	+	++	-	50	9
3	Shih Tzu	6 yrs.	M	OD	2	3	-	++++	+	++	-	45	10
4	Shih Tzu	7 mths.	M	OS	0.5	9	-	++++	+	+	-	42	12
5	Mixed	1 yrs.	F	OD	1	1	-	++	+	++	-	30	4
6	Shih Tzu	3 yrs.	M	OS	0.4	1	-	+	+	+	-	45	7
7	Poodle	8 yrs.	M	OD	0.2	120	+	-	-	-	-	21	4
8	Pug	5 yrs.	M	OD	0.8	3	-	+	+	-	-	30	16
9	Pug	2 yrs.	M	OS	1	7	-	++++	+	++	-	30	5
10	Shih Tzu	3 yrs.	F	OS	0.7	3	-	+	+	+	-	30	4

Table 1 Pre- and post-surgical information of ten canine corneal staphyloma cases treated with PSIS grafting. (Note: MN Res: Menace Response, (+) present, (-) absent; Ant Sync: Anterior Synerchia, iridal attachment present at 25% (+), 50% (++) , 75% (+++), and 100% (++++)) of corneal area observed from the front view, (-) absent; O. Disc: Ocular Discomfort, (+) present, (-) absent; Gr. Dis: Disappearance of granulation tissue; Follow up: Follow up period after Gr. Dis; OD: ocular dexter; OS: ocular sinister; M: male, F: female; yrs: years; mths: months).

recreate a structure that is histologically similar to the original tissue (Kropp et al., 1995). None of the dogs showed immune-mediated reactions to the grafted cornea because of the fact that PSIS is a non-immunogenic biomaterial, which consists of acellular collagen based material structurally conserved between species (Lewin, 1999).

Lewin (1999) and Featherstone and Sansom (2000) reported evidence of corneal blood vessels at the wound edge, which is similar to our findings. We hypothesize that this pattern of vascularization may be influenced by the reaction of host cornea specifically to the PSIS biomaterial because these blood vessels vanished shortly after PSIS biomaterial absorption. Marked corneal vascularization projecting from corneal limbus to the grafted cornea is an indication of inflammatory response mechanism in the host observed prior to the PSIS application and possibly a continuing process of corneal healing.

Dark red color appearing on the grafted cornea is granulation tissue filled with blood. This is part of the corneal healing process. The minimal granulation tissue in dog 7 is perhaps due to the small size of corneal staphyloma. The marked granulation tissue in dog 4 may be a result of the long duration of corneal lesion prior to treatment. It is possible that there is a discoloration from blood in addition to a development of granulation tissue. Blood could be derived from bleeding of the iris because the iris was cut and still possibly attached to corneal wound, based on the fact that PSIS biomaterial has porous structure. Even though cauterization was used to cut protruding iris, bleeding could perhaps still occur subsequently. The degree of bleeding however was too mild to introduce hyphema. Discoloration phenomenon was reported following the application of PSIS biomaterial to treat feline corneal sequestrum (Featherstone et al., 2001) when the graft turned brown.

Scar formation developed in all the dogs because the cornea had a full-thickness defect.

However the duration and degree of corneal scar rapidly lessened. This finding is presumably a result of the healing process that tends to be accelerated by the formation of a three-dimensional scaffold (Badylak et al., 1998) and some components of growth factor of the PSIS biomaterial. These properties of PSIS biomaterial allows for keratocyte migration and spatial organization of collagen fibers into perforating corneal defect.

Leakage of aqueous humor was undetectable. In our study, a double layer of PSIS biomaterial was applied to a full-thickness corneal defect with diameter larger than 0.7 cm. Application of multiple PSIS biomaterial sheets and/or a circumferential suture pattern is recommended to prevent the leakage of aqueous humor if the corneal defect is larger than 1 cm (Vygantas and Whitley, 2003). A third eyelid flap was created in all dogs as an additional protection to the corneal defect in our study. Other additional protections such as a bridge conjunctival flap or conjunctival pedical graft can also be considered (Bussieres et al., 2004). Although anterior synechia, a common complication encountered with corneal perforating defects, was still observed postoperatively in many dogs, its degree decreased in nearly all cases compared with prior to the operation. The delayed positive menace response observed in dog 2, 3 and 9 is presumably associated with size of corneal wound and severity of anterior synechia. All dogs however had vision up to the last re-evaluation.

Conclusion

PSIS biomaterial promotes corneal healing and minimizes inflammatory response and scar formation without the risk of graft rejection. PSIS grafting offers the advantages of being easy to perform and not requiring expensive instruments. This technique has therefore become one of the alternative surgical treatments to repair canine corneal staphyloma.

Acknowledgement

Cook Veterinary Product, Inc (Australia) for providing PSIS biomaterial and Dr Duangnarumon Prachankhadee for proof reading.

References

- Badylak, S., Kokini, K., Tullius, B., Simmons-Byrd, A. and Morff, R. 2002. Morphologic study of small intestinal submucosa as a body wall repair device. *J. Surg. Res.* 103(2): 190-202.
- Badylak, S.F., Record, R., Lindberg, K., Hodde, J. and Park, K. 1998. Small intestinal submucosa: a substrate for in vitro cell growth. *J. Biomater. Sci. Polym. Ed.* 9(8): 863-878.
- Badylak, S.F., Lantz, G.C., Coffey, A. and Geddes, L.A. 1989. Small intestinal submucosa as a large diameter vascular graft in the dog. *J. Surg. Res.* 47: 74-80.
- Bussieres, M., Krohne, S.G., Stiles, J. and Townsend, W.M. 2004. The use of porcine small intestinal submucosa for the repair of full-thickness corneal defects in dogs, cats and horses. *Vet. Ophthalmol.* 7(5): 352-359.
- Featherstone, H.J. and Sansom, J. 2000. Intestinal submucosa repair in two cases of feline ulcerative keratitis. *Vet. Rec.* 146: 136-138.
- Featherstone, H.J., Sanson, J. and Heirich C.L. 2001. The use of porcine small intestinal submucosa in ten cases of feline corneal discase. *Vet. Ophthalmol.* 4 (2): 147-153.
- Kropp, B.P., Eppley, B.L., Prevel, C.D., Rippy, M.K., Harruff, R.C., Badylak, S.F., Adams, M.C., Rink, R.C. and Keating, M.A. 1995. Experimental assessment of small intestinal submucosa as a bladder wall substitute. *Pediatric Uro.* 46(31): 396-400.
- Lewin, G.A. 1999. Repair of a full thickness corneo-scleral defect in a German shepherd dog using porcine small intestinal submucosa. *J. Small Anim. Pract.* 40: 340-342.
- Matheny, R.G., Hutchison, M.L., Dryden, P.E., Hiles, M.D. and Shaar, C.J. 2000. Porcine small intestine submucosa as a pulmonary valve leaflet substitute. *J. Heart Valve Dis.* 9(6): 769-774.
- Severin, G.A. 1995. Cornea. In: Severin's Veterinary Ophthalmology Notes. 3rd ed. Design Pointe Communication Inc., Colorado. p.337.
- Vygantas, K.R. and Whitley, R.D. 2003. Management of deep corneal ulcers. *Comp. Cont. Edu. Pract. Vet. North Am. Ed.* 25(3): 196-205.