

Phacofragmentation and Aspiration in Canine Mature Cataract: Surgical technique, Success rate and Complications

Pranee Tuntivanich* Naline Tuntivanich

Abstract

Phacofragmentation and aspiration technique without intraocular lens implantation was reported in 26 mature cataractous dogs. Dogs included in this study were 13 Poodles, 6 crossbred dogs, 4 Cocker spaniels, 1 Shih-tzu, 1 West Highland white terrier and 1 Miniature pinscher. All dogs were clinically blinded from bilateral mature cataracts with positive dazzle reflex prior to the surgery. 24 dogs (92.31%) regained vision after the surgery which remained until the end of the study. Vitreous degeneration was found pre-operatively in one dog. Hyphema, displacement of lens into vitreous chamber, rupture of the posterior lens capsule and miosis were found intra-operatively in 1, 1, 2 and 2 dogs, respectively. Corneal edema, corneal ulcer, glaucoma, uveitis, posterior capsule opacification, posterior synechia and fibrin formation were evident post-operatively in 2, 1, 1, 26, 13, 9 and 7 dogs, respectively.

Keywords : phacofragmentation and aspiration, mature cataract, surgical technique, success rate, complication, canine

Ophthalmology clinic, Department of Surgery, Faculty of Veterinary Sciences, Chulalongkorn University, Bangkok 10330, Thailand.

*Corresponding author

บทคัดย่อ

ศัลยกรรมสลายต้อกระจกชนิดสุกเต็มที่ในสุนัขด้วยคลื่นอัลตราซาวด์: เทคนิคทางศัลยกรรม อัตราความสำเร็จ และโรคแทรกซ้อน

ปราณี ตันตวนิช* นลินี ตันตวนิช

รายงานวิธีการทำศัลยกรรมสลายต้อกระจกชนิดสุกเต็มที่ด้วยการใช้เครื่องอัลตราซาวด์ในสุนัข 26 ตัว ประกอบด้วย พันธุ์ พูเดิ้ล 13 ตัว พันธุ์ผสม 6 ตัว พันธุ์คอกเกอร์ สเปเนียล 4 ตัว พันธุ์ชิลี พันธุ์เวสไฮแลนด์ไวท์เทอร์เรีย และพันธุ์มินิเอเจอร์ ฟินช์เชอร์ อย่างละ 1 ตัว สุนัขทุกตัวมองไม่เห็นก่อนการทำศัลยกรรมอันเนื่องมาจากเป็นโรคต้อกระจกชนิดสุกเต็มที่ของตาทั้งสองข้าง แต่ยังคงมีการตอบสนองแดสเซลด์ สุนัข 24 ตัว (92.31%) สามารถมองเห็นได้ภายหลังทำศัลยกรรม และยังคงมองเห็นได้เมื่อสิ้นสุดการศึกษา ภาวะแทรกซ้อนที่พบก่อนทำศัลยกรรมได้แก่เนื้องอกตาเสื่อมจำนวน 1 ตัว ภาวะแทรกซ้อนที่พบขณะทำศัลยกรรม ได้แก่ เลือดออกในช่องหน้าม่านตา แก้วตาดตกลงไปในช่องเนื้องอกตา ปอดกุ่มแก้วตาทางด้านหลังลูกตา และ ม่านตาหดตัว จำนวน 1, 1, 2 และ 2 ตัว ตามลำดับ ภาวะแทรกซ้อนที่พบภายหลัง ทำศัลยกรรม ได้แก่ กระจกตาบวม น้ำ แผลหลุมที่กระจกตา ต้อหิน ม่านตาอักเสบ ปอดกุ่มแก้วตาทางด้านหลังม่านตา ม่านตายึดติดกับปอดกุ่มแก้วตา และไฟบรินในช่องหน้าม่านตา จำนวน 2, 1, 1, 26, 13, 9 และ 7 ตัว ตามลำดับ

คำสำคัญ: สลายต้อกระจกด้วยคลื่นอัลตราซาวด์ ต้อกระจกชนิดสุกเต็มที่ เทคนิคทางศัลยกรรม อัตราความสำเร็จ โรคแทรกซ้อน สุนัข

หน่วยจักษุคลินิก ภาควิชาสัตวศาสตร์ คณะสัตวแพทยศาสตร์ จุฬาลงกรณ์มหาวิทยาลัย กรุงเทพฯ 10330

*ผู้รับผิดชอบบทความ

Introduction

Lens is a clear structure located behind the pupil. It works in conjunction with other parts of the eye to focus light on the retina resulting in an image. Lens predominantly consists of protein. A cataract is a disease, at which the lens has become opaque because of a biochemical change of the lens protein. Change of lens protein is a continuing process, leading to protein precipitation. It can occur at any part of the lens at various extents (Petersen-Jones, 2002).

Cataract is mainly categorized into 4 stages based on the degree of lens opacification; incipient, immature, mature and hypermature. Incipient cataract is the earliest lens opacity which does not impair clinical vision. Visible opacity of the lens is seen in immature cataract, which leads to some visual impairment. Mature cataract involves the opacity of an entire lens. Clinical vision is completely impaired. With hypermature cataract, lens reduces in size and undergoes resorption. Although resorption of hypermature lens may improve vision (Rubin and Gelatt, 1968), uveitis is concerned for sight-threatening.

Medical treatment of cataract has been widely studied. Efficacy of dietary antioxidants was reported to

delay cataractogenesis in older animals and humans (William and Munday, 2006). However, cataract is not successfully cured with medicine. Nowadays, surgery appears to be the choice of treatment for cataract. Several surgical techniques are well described for cataract treatment; intracapsular cataract extraction (ICCE), extracapsular cataract extraction (ECCE) and phacofragmentation and aspiration (PFA) (Gelatt and Gelatt, 2001). ICCE is recommended when lens is luxated because an entire lens and its capsule are extracted. Prognosis is the best if the lens is removed prior to the onset of secondary glaucoma (Nasisse, 2001). With ECCE and PFA, a central part of anterior lens capsule, lens cortex and lens nucleus are removed. The posterior and equatorial lens capsules are left intact for a possibility of intraocular lens (IOL) implantation. These two techniques are the most common for cataract surgery.

PFA has been recognized in veterinary practice for the past 20 years. It is a technique that lens cortex and nucleus were broken by a use of ultrasonic wave and then removed by aspiration leaving the posterior and equatorial lens capsules intact (Gilger, 2003). Due to small corneal incision, shorten operating time, sensible degree of traumatic distress to the eye and shorten recovery

period, there is a decrease in postoperative complications compared to other techniques (Riaz et al., 2006). As a result, PFA technique yields markedly high success rate for canine cataract extraction (Miller et al., 1987; Dziezyc, 1990). However, this technique is more difficult than other traditional technique and requires considerably expensive instrument. Besides, ultrasonic wave can contradictorily cause severe ocular inflammation (Dziezyc, 1990; Gilger, 2003) if lack of personal skill.

As there has been an increase in number of canine cataract requiring surgery at the ophthalmology clinic, small animal teaching hospital, Faculty of Veterinary Sciences, Chulalongkorn University, Bangkok, Thailand, and PFA technique has recently been introduced into the Thai veterinary practice, the purpose of this study was to describe a detailed procedure of phacofragmentation and aspiration surgery in canine mature cataractous eyes without intraocular lens implantation and to assess visual outcome and surgical complications.

Materials and Methods

Animals

Twenty six mature cataractous dogs underwent for PFA surgery at the ophthalmology clinic, small animal teaching hospital, Faculty of Veterinary Sciences, Chulalongkorn University. There were 12 females and 14 males with the median age of 8 years. Breed of dogs included Poodle (13), crossbred dog (6), Cocker spaniels (4), Shih-tzu (1), West Highland white terrier (1) and Miniature pinscher (1). Criteria for selecting good surgical candidates were as followed; bilateral mature cataract, negative menace response, positive dazzle reflex, positive direct and consensual pupillary light reflexes (PLRs), failed maze test in dark and light room conditions, normal intraocular pressure (IOP), no evidence of retinal detachment shown on ultrasonogram, normal tear level, no pre-existing ocular abnormalities or systemic disorders, well-mannered (controllable) dog and the owner's cooperation. All owners were informed of the principles of the surgery and postoperative care. All dogs underwent complete blood count and chemistry profile prior to the surgery.

Procedures

(1) Pre-surgery

Sialexin (Ibilex, Siam pharmaceutical Co., Ltd) 25 mg/kg and prednisolone acetate (Prednisolone®, New Life Pharma Co., Ltd.) 1 mg/kg were orally given twice daily for a consecutive three days prior to the surgery. 1% atropine sulphate (Isopto atropine®, Alcon Laboratories) and 0.3% tobramycin (Tobrex®, Alcon Laboratories) were given topically four times a day for a consecutive three days prior to the surgery. On the operating day, 1% tropicamide (Mydracyl®, Alcon Laboratories) and 0.5% ketorolac tromethamine (Acular®, Allergan, Inc) were given topically every 15 minutes for 2 hours until the time of the surgery.

(2) Anesthesia and preparation

Dogs were premedicated with atropine sulphate 0.04 mg/kg, acepromazine maleate 0.01-0.05 mg/kg combined with morphine 0.3-0.5 mg/kg intramuscularly. Induction was performed using 1% propofol (Fresofol®, Fresenius Kabi Austria GmbH) 4 mg/kg followed by a maintenance with isoflurane delivered in oxygen. Atracurium (Tracrium™, Glaxo Smith Kline) 0.3-0.5 mg/kg was administered intramuscularly to eliminate the tone of the extraocular muscles and to reduce tension on the posterior lens capsule. Chlorphenilamine maleate 2-8 mg/kg was intramuscularly administered 30 minutes prior to the surgery to reduce fibrin formation during surgery. Dogs were positioned in lateral recumbency with the eye planned for surgery being upward. Head was carefully stabilized on a fixation device. Unilateral cataract surgery was performed by one ophthalmologist using phacofragmentation and aspiration unit (Universal II, Alcon Laboratories), with aid of operating microscope (OMS-85, Topcon Europe B.V.).

Surgical site was prepared with asepsis technique. Conjunctival surface and sac were cleaned using sterile cotton swabs soaked with 0.5% povidone-iodine solution. The surgical area was draped carefully to expose only the palpebral fissure. Four fixation forceps were used to fix bulba conjunctiva at 6, 9, 12 and 3 o'clock positions to ensure primary gaze and globe exposure during surgery (Fig. 1). Lactated Ringer's solution (LRS) was prepared to moisten the cornea during surgery.

(3) Surgery

An incision was made at the corneal limbus with a 3-mm angled ophthalmic knife (Slit knife®, Alcon Laboratories) (Fig. 2). The anterior chamber volume was restored with viscoelastic material (Viscoat®, Alcon Laboratories) (Fig. 3). A modified curved 23-gauged needle was used to cut into the anterior lens capsule (Fig. 4A), followed by an anterior continuous curvilinear capsulorhexis using Utrata lens capsule forceps (Fig. 4B). Part of anterior lens capsule, approximately 6-8 mm in diameter, was carefully torn and removed (Fig. 4C). Hydrorhexis was performed afterward, using pressure from LRS to release an attachment between the remaining lens capsule and lens cortex (Fig. 5). A phacofragmentation tip was introduced through the corneal incision through the anterior lens capsule opening to sculpt the cataractous lens (Fig. 6). Irrigation and aspiration were used towards the end of the surgery to remove the remaining lens materials from the equatorial and posterior lens capsules. Once PFA was completed (Fig. 7), corneal incision was apposed with two interrupted nylon 10/0 sutures (Ethilon®, Alcon Laboratories). The anterior chamber was restored with balance salt solution (BSS®, Alcon Laboratories). A combination of gentamicin 0.1 ml and dexamethasone 0.1 ml was injected subconjunctivally.

(4) Post-surgery

Several topical administrations were applied for the first 7 days as followed; 0.3% tobramycin every hours then tapered to 4-6 times daily for 2 weeks, 0.1% fluorometholone acetate (Flarex®, Alcon Laboratories) 4 times daily started at day 3 postoperatively and then tapered to 2-3 times daily for 1 month, artificial tear (Celluvisc®, Allergan, Inc) every 2 hours then tapered to 4 times daily for 1 month and 1% atropine sulphate twice daily continued for 2 weeks then tapered to once daily for another 2 weeks. Several systemic administrations were given for the first 5 days as followed; Ceftriaxone disodium (Cef3®, Siam Pharmaceutical Co., Ltd.) 25 mg/kg intramuscularly then continued with Sialixin orally for 5 days, dexamethasone 0.5 mg/kg, chlorpheniramine maleate 2-8 mg/kg and vitamin A 5,000 IU then continued orally for 10 days. Carprofen (Rimadyl®, Pfizer Co., Ltd) 2 mg/kg was orally given once

dexamethasone had stopped for a consecutive 10 days. Medications and dose were subjected to change based on intraocular complications. All dogs were required to wear Elizabethan collar at all times during the first 2 months to prevent self trauma. Excitements or any compelling factors to dogs were limited to minimize postoperative complications.

Data analysis

Eyes were examined postoperatively every day for the first 7 days, then twice a week for 2 weeks, weekly for 3 weeks and then monthly until at least 4 months after the surgery. To evaluate an outcome (visual restoration), dogs were examined for menace response, dazzle reflex and ability to perform maze test in dark and light room conditions. Direct and indirect ophthalmoscopy, slit-lamp biomicroscopy and tonometry were performed to assess postoperative complications.

Results

Twenty four out of 26 dogs (92.31%) regained vision within a median of 3 day postoperatively. Menace response had become positive while dazzle reflex still remained. These dogs passed all patterns of maze test in dark and light room conditions. Their vision remained until the last day of evaluation (Table 1).

Surgical complications were categorized into 3 phases; pre-operative, intra-operative (Fig. 8) and post-operative (Fig. 9). Vitreous degeneration was the only complication found pre-operatively. It was noticed in one dog (dog 26) from an ultrasonographic image prior to the surgery. Vitreous degeneration was ultrasonographically seen as a large, irregular hyper-echoic structure in the vitreous chamber. This lesion was intra-operatively seen as a cluster of liquefied substance in the vitreous chamber, after lens had been extracted.

Several intra-operative complications occurred at different time points during the surgery. Pupil constriction (miosis) occurred in 2 dogs immediately after cornea was incised and for the second time after the lens had been partly sculpted. Blood in anterior chamber (hyphema) was observed in one of the two dogs of which pupil had become constricted during lens fragmentation procedure. Rupture of posterior lens capsule caused

vitreous prolapse in 2 dogs. It occurred while the phacofragmentation tip was being applied at the posterior lens capsule for an attempt to remove the remaining lens materials. In addition, it was found in one dog during the same course of action that lens was displaced into the vitreous chamber.

Uveitis is the major post-operative complication in all 26 dogs. Excessive fibrin was observed in the anterior chamber since day 1 postoperatively in 7 dogs. It had been present as fibrinous clot for a period of time but at lesser degree. The second most post-operative complication found in 13 dogs in this study was posterior capsular opacification. Opacification of the posterior lens capsule became noticeable approximately at post-operative day 7 onward (Fig. 10). It initially appeared at the center of the capsule then progressed towards the periphery. Adhesion of iris to the posterior lens capsule (posterior synechia) (Fig. 10) was observed in 9 dogs, all of which developed posterior capsular opacification. Local corneal edema occurred temporarily near corneal incision. It shortly vanished after day 7 postoperatively. One dog developed a large corneal ulcer at postoperative week 3 confirmed by fluorescein staining.

Two out of 26 dogs did not regain vision after the surgery. One dog had had severe uveitis and excessive fibrin formation since post-operative day 1. Uveitis and fibrin formation did not respond well to medications. Another dog regained vision at day 1 post-operatively. Unfortunately ocular hypertension developed (averaged IOP = 21 mmHg) at post-operative day 2. The IOP was uncontrollable by any hypertensive medications. Its IOP was 30 mmHg at post-operative day 4, which led to secondary glaucoma. The dog became blind and did not regain vision afterward.

Discussion

Cataract is generally found in various breed of dogs, however, the incidence was significantly high in several breeds such as Cocker spaniel, Miniature schnauzer, Toy breed, Boston terrier, Miniature poodle and Bichon frise (Adkin and Hendrix, 2005). Miniature poodle and crossbred dog are the primarily (13/26) and secondarily (6/26) predominant breeds, respectively, with cataract that underwent PFA surgery in this study.

To optimize visual outcome, it is recommended that cataractous lens should be surgically removed while it is still immature and vision still remained (Renwick, 1997). PFA technique become difficult when mature or hypermature cataract surgery is performed due to loss of thickness and elasticity of the anterior lens capsule (Ozgencil, 2005) and significant increase mean effective phacofragmentation time compared to other types of cataract (Ermiss et al., 2003). Moreover, there is an increased risk of surgical complications (van der Woerd et al., 1992), all of which result in a lower success rate of the surgery. In our study, the surgery was intentionally performed in blind dogs affected with mature cataract because post-operative visual restoration can be easily determined as positive or negative. Since IOL was not implanted, assessment of visual outcome in immature cataractous dog would be problematic because vision remains preoperatively. In spite of improving vision in immature cataractous dog, phacofragmentation surgery without IOL implantation may contradictorily result in lesser visual acuity and even more impaired vision.

PFA surgery can be performed unilaterally or bilaterally. Simultaneous bilateral cataract surgery has been commonly performed (Nielsen and Allerod, 1998; Jacobi et al., 1999) for the reason that visual rehabilitation of the patient is more rapidly in addition to a reduction of cost for transportation and postoperative care. In contrast, animals are faced with risk of bilateral surgical complications (Tyagi and McDonnell, 1998), bilateral visual loss (Johansson and Lundh, 2003) and higher possibility of self trauma. Because PFA is a new technique in our country, unilateral removal of cataract was therefore considered in our study.

Criteria for patient selection were created in this study since several factors can affect optimal success of the PFA surgery (Gelatt and Gelatt, 2001). Our owners were well-informed about the surgery, time and effort for post-operative treatment as well as potential complications. The owner's cooperation is as important as the effectiveness of the surgery and the medications. General behavior of dogs also plays an important role. Excitement and aggressiveness were required to be limited post-operatively. Dogs difficult to control were excluded from this surgery because they were likely

to develop post-operative complications. Dog 11 developed a large deep corneal ulcer at postoperative week 3 because the owner removed Elizabethan collar for easy feeding purpose. Corneal ulcer was immediately treated with medications in conjunction with corneal amniotic membrane grafting. Fortunately, vision in this dog still remained after the corneal wound was healed.

All dogs were also examined for any pre-existing ocular disorders that may lessen visual outcome such as low tear level prone to keratoconjunctivitis sicca, ocular hypertension leading to glaucoma or lens-induced uveitis. In addition, the retina should be intact and function well prior to the surgery. Ocular ultrasonography was performed in our study to ensure an intact of the retina at the posterior wall as recommended by van der Woerd et al. (1993). Unfortunately retinal function was unable to determine due to a lack of electroretinographic machine in Thai veterinary practice. Dazzle reflex was however tested to indirectly assess retinal function via subcortical connection (Gelatt, 1997).

To assess visual outcome, several examinations were performed pre- and post-surgery. The surgery is considered success if vision is restored post-operatively and maintained at the last evaluation. In order to determine regained vision, dogs were required to have positive menace response in addition to pass maze test at times of evaluation. Dazzle reflex was required to be positive pre- and post-surgery as an indication of optic nerve intact to the midbrain. Our success rate was 92.31% (24/26). Two out of 26 dogs, dog 9 and dog 18, were unable to regain vision after the surgery. Severe uveitis and excessive fibrin formation were observed in dog 9. Even though pathogenesis of uveitis resulting in sight-threatening condition is not well understood, it is believed to be related to antigen-specific immune response induced by inflammatory substances (Durrani et al., 2004). Increased age may possibly accelerate the mechanism of autoimmune hypersensitivity of the uveal tissue. Moreover undetectable pre-existing lens-induced uveitis may have already developed prior to the surgery, which worsened the autoimmune hypersensitivity reaction. Immunosuppressive medication should be given to reduce the degree of uveitis and fibrin formation (Williams et al., 2007).

Dog 18 regained vision at post-operative day 1 but lost sight afterwards due to secondary glaucoma. Ocular hypertension is primarily associated with a decrease in the outflow of the aqueous humor. The major factor contributing to an obstruction at the filtration angle is possibly due to a significant precipitation of inflammatory cells resulting from uveitis. Remaining viscoelastic material can also lead to an elevation of IOP as reported by Feyes et al. (2000). It is therefore necessary to postoperatively monitor the IOP. Even though transient ocular hypertension may sometimes be found after cataract surgery (Miller et al., 1997), it can be treated with hypotensive drugs to prevent damage to the retina and the optic nerve (Chahory et al., 2003). Secondary glaucoma following PFA surgery was also reported to develop at 6 (15.5%) and 12 (28.8%) months after the surgery (Biros et al., 2000), hence a long term monitoring of IOP should be considered.

Our study concentrated on PFA technique, which is considerably new in Thai veterinary practice. Some intra-operative complications were found to have an effect on success rate of the surgery. Rupture of the posterior capsule occurred when the phacofragmentation tip was inserted too far into the capsular bag. The tear of the posterior lens capsule can potentially lead to prolapsed vitreous humor, which occurred in one of the 2 dogs with posterior lens capsule rupture in this study. Moreover, if the tear is quite large, it may have insufficient strength to hold the lens resulting in lens dropping into the vitreous chamber. Care should therefore be taken to gently clean the capsule and the tip should be at the center of the chamber, “a safe zone”, to prevent rupture of the posterior lens capsule (Warren, 2004). For an attempt to completely get rid of the remaining lens materials at the posterior lens capsule, level of vacuum during aspiration procedure should be re-adjusted to avoid too much pressure on the capsule (Osher et al., 1990). Although posterior lens capsule rupture was found in 2 dogs in this study, this complication was still compatible with visual restoration as also reported by Eng-Yiat Yalo and Wee-Jin Heng (2004).

Pupil was noticeably constricted in 2 dogs as soon as phacofragmentation tip was introduced into the anterior chamber. As a consequence, miosis complicated lens fragmentation procedure leading to hyphema. To

resolve intra-operative miosis, 100 µg of adrenaline was recommended to install into the anterior chamber to quickly dilate the pupil (Petersen-Jones and Clutton, 1994). To prevent miosis during surgery, adrenaline or heparin sodium can be added into the irrigation solution. Not only heparin can reduce fibrinoid reaction, it can also prevent intra-operative pupil irregularity and post-operative inflammation (Bayramlar et al., 2004). Mild degree of hyphema found in 1 dog during surgery disappeared within the first post-operative 3 days.

Lens-induced uveitis, phacolytic uveitis, is the most common complication that occurs following PFA surgery. Severe degree of uveitis is not only sight-threatening but also a causative factor for posterior synechia (Gelatt and Gelatt, 2001). All dogs in this study showed signs of uveitis. To reduce the degree of phacolytic uveitis, the surgery should be performed prior to the onset of uveitis, which was always found in an association with hypermature cataracts or occasionally mature cataract (van der Woerd, 2000). Topical and systemic treatment by steroidal and non-steroidal anti-inflammatory drugs can control uveitis pre- and post-operatively. Ketorolac tromethamine showed low efficacy reducing inflammation but less likely to induce ocular hypertension after phacofragmentation and aspiration surgery compared to fluorometholone acetate (Trinavarat et al., 2003). In our study, ketorolac tromethamine was therefore selected for pre-operative treatment while fluorometholone acetate was selected postoperatively.

The second most common post-operative complication was posterior capsular opacification or secondary cataract (Clark, 2000; Kelly and Mark, 2006). Posterior capsular opacification was also our second most common post-operative complication found in 50% of the total number of dogs. It could develop within 2-5 years (Siddiqui, 2001) causing visual loss following cataract surgery with and without IOL implantation (Gwon et al, 1993). Even though age, gender and intraocular inflammation have no influence on the development of posterior capsular opacification, small and medium-sized breeds significantly develop posterior capsular opacification earlier than larger breeds (Bras et al, 2006). Following PFA surgery, part of anterior lens capsule remains in the eye. Surgical mechanism

stimulates viable lens epithelium to replicate and secrete lens materials for a regeneration of new cortex at posterior lens capsule (Nasisse, 2001). A thick structure on the posterior lens capsule resulted from a proliferation of lens epithelium, Soemmering's ring, can be clinically diagnosed using ultrasound biomicroscopy (Kobayashi et al., 2000).

Apple et al. (2001) suggested two major principles that may be applied to prevent posterior capsular opacification. A primary line of defense is to minimize the number of unwanted lens epithelial cells remaining at lens equator and cortex in order to avoid significant Soemmering's ring formation. Although Wilhelmus et al. (1980) reported that capsular polishing did not prevent posterior capsular opacification, a removal of excessive lens epithelium on the posterior lens capsule at the time of the surgery was necessary to decrease an occurrence of posterior capsular opacification (Glover and Constantinescu, 1997; Davidson et al., 2000). A secondary line of defense can also be created by the use of a barrier to block cell growth from the equatorial region, at which Soemmering's ring initially develops. A study in rabbit using intracapsular ring releasing 5-fluorouracil to block lens epithelial cell migration revealed a decrease of posterior capsular opacification at the center region of the capsule (Pandey et al., 2002). A careful and copious hydropexis additionally performed in our study not only facilitated the ease and shorten surgical time consuming but also promoted a thorough lens epithelium removal (Peng et al., 2000). Neodymium: yttrium-aluminium-garnet (Nd:YAG) laser posterior capsulotomy is a safe technique that can be used to rapidly decrease posterior capsular opacification with improved visual acuity (Landa et al., 2006). However a patient undergone Nd:YAG posterior capsulotomy should be carefully monitored for transient acute ocular hypertension subsequent (Tranos et al., 2004) to a removal of posterior lens opacification.

Fibrin in the anterior chamber is undesirable. Severe fibrin deposition is a causative factor for posterior synechia (Shinoda et al., 2001), in addition to uveitis and secondary glaucoma. To reasonably prevent fibrin formation, heparin 1-2 units/ml was recommended to add in LRS or BSS (Gelatt and Gelatt, 2001). Antihistamine

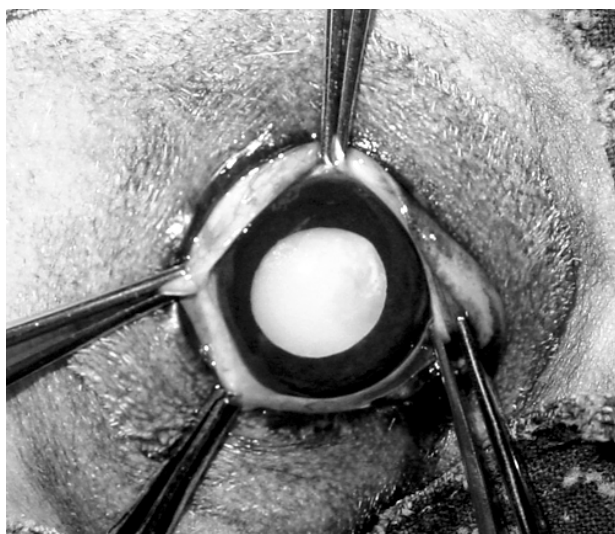


Figure 1 Positioning of the eye for the surgery. Four fixation forceps were used to stabilize and rotate an eyeball upward for the surgery. Note that bulbar conjunctiva was fixed with fixation forceps at 3, 6, 9 and 12 o'clock positions.

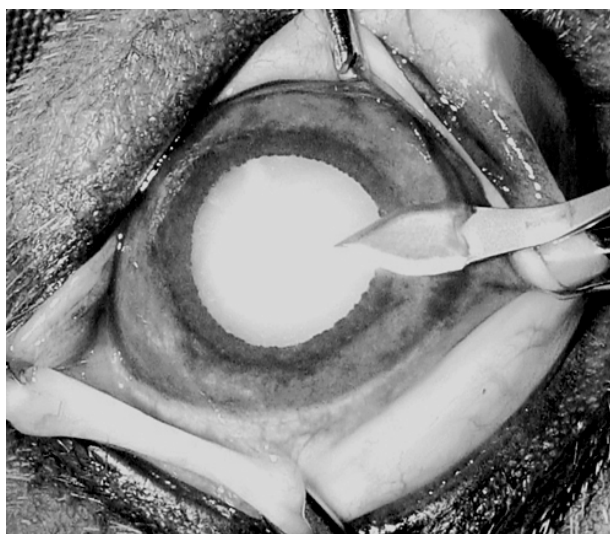


Figure 2 Corneal incision. An incision was made at corneal limbus using a 3mm-angled ophthalmic knife (Slit knife®, Alcon Laboratories). Note that care should be taken to avoid iris.

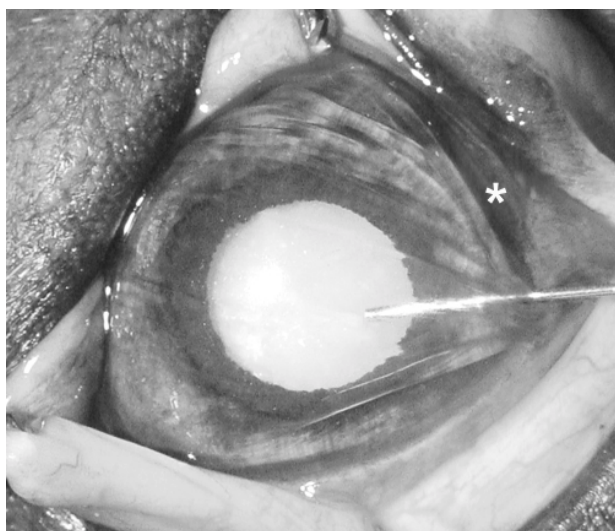


Figure 3 Application of viscoelastic material in the anterior chamber. The anterior chamber was filled with viscoelastic material (Viscoat®, Alcon Laboratories), which was transparent, to maintain its volume and shape during surgery. Note small amount of blood surrounding corneal incision site (asterisk) was from conjunctival bleeding during corneal incision.

was used in our study for this purpose with a successful result. It was also suggested that fibrin formation can be prevented by an administration of antihistamine 30 minutes prior to the surgery (Severin, 1995). To eliminate large fibrin clot, infusion of tissue plasminogen activator (Georgiadis et al., 2003) or recombinant tissue plasminogen activator (Ozveren and Eltutar, 2004) into the anterior chamber was recommended.

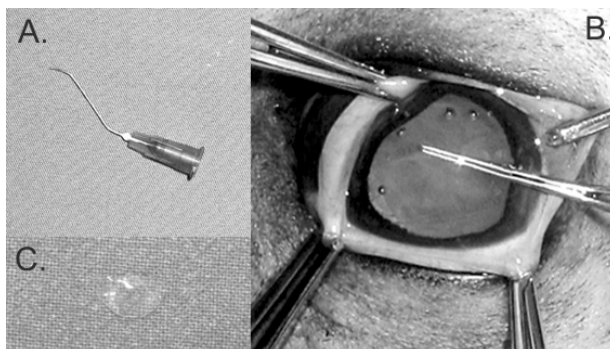


Figure 4 Capsulorhexis. 4A. A modified 23-gauged needle was curved to incise the anterior lens capsule. 4B. Utrata lens capsule forceps were used for a continuous curvilinear capsulorhexis. 4C. Approximately 6-8 mm in diameter of the anterior lens capsule resulted from capsulorhexis.

Corneal edema as one of the post-operative complications was minimal in this study. It was observed at corneal incision site in 2 dogs, which indicates local dysfunction of corneal epithelium and endothelium due to mechanical trauma. Corneal edema however shortly subsided and vanished within 10 days after the surgery.

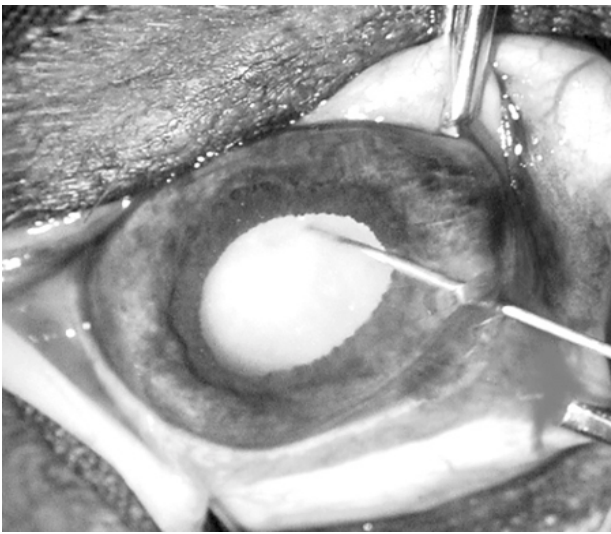


Figure 5 Hydrorhexis. A 21-gauged intravenous catheter connected to a 1ml syringe filled with lactate ringer solution was inserted underneath the remaining capsule in order to free it from the lens cortex.

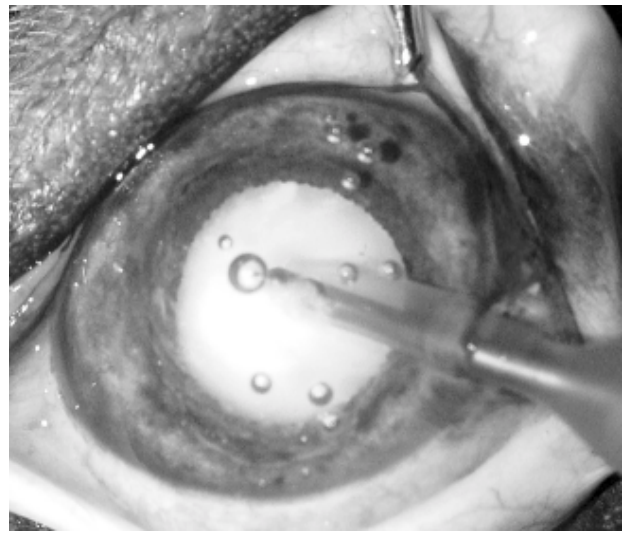


Figure 6 Phacofragmentation and aspiration procedure. Phacofragmentation and aspiration tip was introduced through the corneal incision through the anterior capsulorhexis into the anterior lens cortex. Note that bubbles in the anterior chamber were normally created from the ultrasonic wave during phacofragmentation and aspiration procedure.

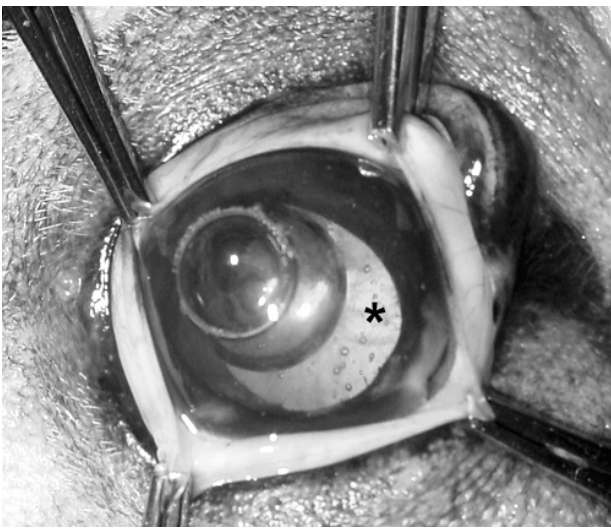


Figure 7 Aphakic eye. After lens materials were removed, a reflection from the fundus (asterisk) was apparent through the pupil. Note that large and small bubbles were removed prior to an apposition of corneal incision.

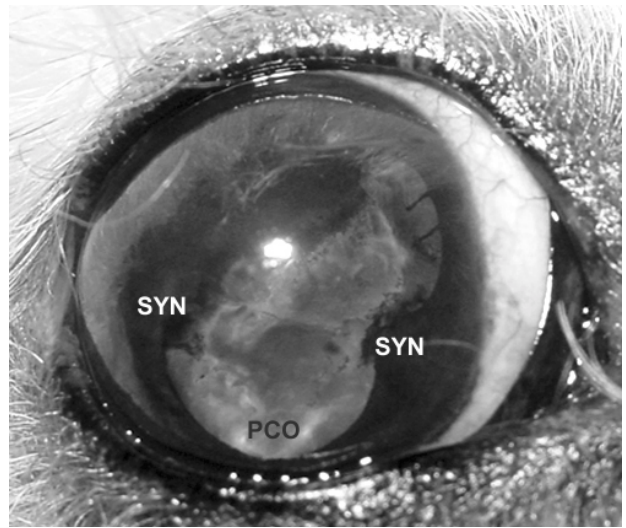


Figure 10 Postoperative complications (dog 8). Posterior capsular opacification (PCO) was obviously apparent at year 2 postoperatively. Posterior synechia (SYN) was noticed.

Conclusion

The phacofragmentation and aspiration technique is highly recommended for canine mature cataract treatment. This is a fairly new technique in the Thai veterinary practice that requires several factors including

the owner's cooperation, animal's behavior, surgical skill, medications and intense post-operative care. Minimal surgical complications at pre-, intra- and post-surgery are required for visual restoration.

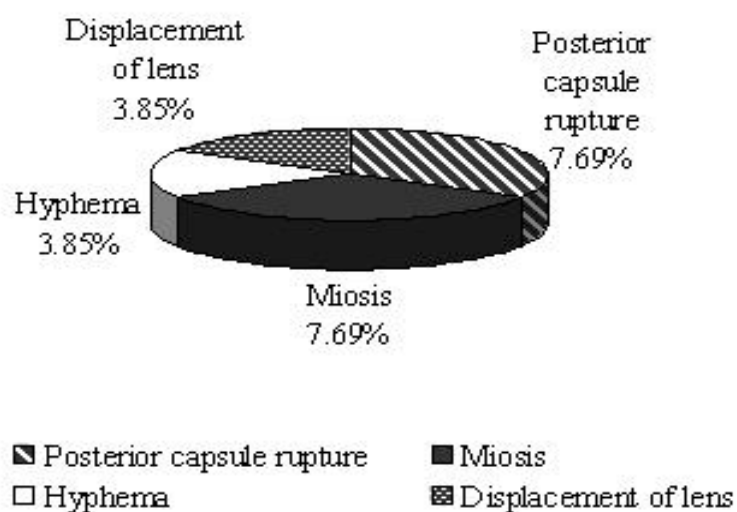


Figure 8 Graph illustrating prevalence of intra-operative complications (in percentage) that occurred during phacofragmentation and aspiration surgery.

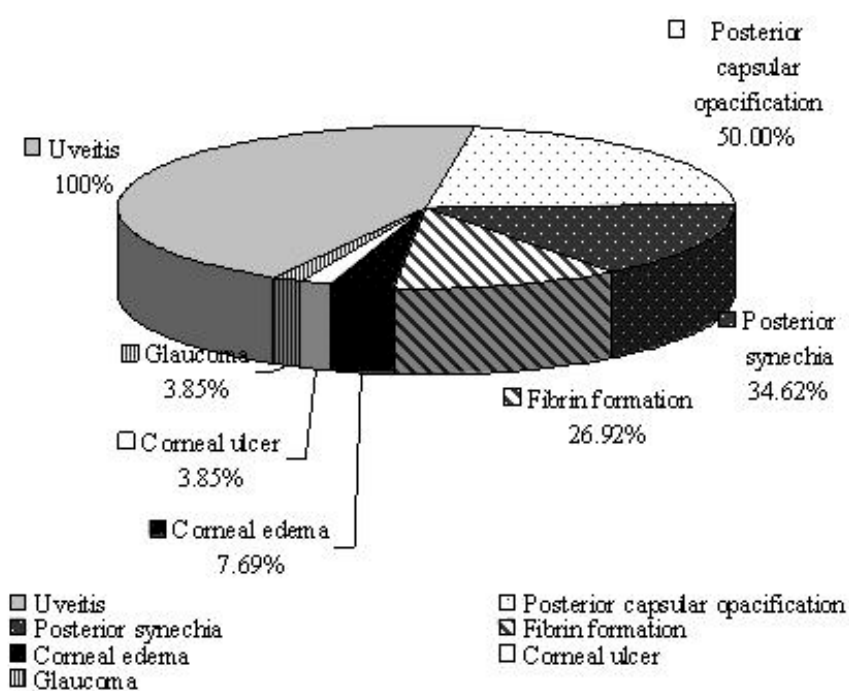


Figure 9 Graph illustrating prevalence of post-operative complications (in percentage) that occurred following phacofragmentation and aspiration surgery.

| Dog number | Breed | Age (year) | Gender | Eye (side) | Complications | | Vision regained (day) | Last Evaluation (month) | Vision at last evaluation |
|------------|-------------|------------|--------|------------|---------------|----------------|-----------------------|-------------------------|---------------------------|
| | | | | | Intra | Post | | | |
| 1 | Poodle | 9 | M | R | none | U | 4 | 4 | + |
| 2 | Poodle | 6 | M | L | none | U, PCO | 3 | 6 | + |
| 3 | Poodle | 8 | M | L | PCR | U, PCO, SYN | 13 | 7 | + |
| 4 | Poodle | 8 | M | R | none | U | 3 | 4 | + |
| 5 | Poodle | 9 | M | L | none | U | 3 | 17 | + |
| 6 | Poodle | 4 | F | R | none | U | 1 | 4 | + |
| 7 | Poodle | 4 | F | R | none | U, PCO, SYN | 1 | 8 | + |
| 8 | Poodle | 4 | F | L | none | U, PCO, SYN | 1 | 5 | + |
| 9 | Poodle | 13 | F | L | none | U, F | - | 5 | - |
| 10 | Poodle | 6 | M | R | none | U, PCO, SYN | 1 | 24 | + |
| 11 | Poodle | 4 | F | R | H, M | U, F, CE, CU | 3 | 4 | + |
| 12 | Poodle | 8 | M | R | none | U, F, PCO | 3 | 11 | + |
| 13 | Poodle | 8 | F | L | M | U, F, PCO | 1 | 4 | + |
| 14 | Crossbred | 7 | M | L | none | U | 4 | 10 | + |
| 15 | Crossbred | 8 | M | R | none | U, F, PCO, SYN | 1 | 9 | + |
| 16 | Crossbred | 3 | F | R | PCR | U | 1 | 6 | + |
| 17 | Crossbred | 10 | M | R | none | U | 8 | 5 | + |
| 18 | Crossbred | 6 | F | R | none | U, G | 1 | 4 | - |
| 19 | Crossbred | 10 | F | R | none | U, PCO, SYN | 3 | 6 | + |
| 20 | Cocker | 10 | M | L | none | U, PCO | 2 | 4 | + |
| 21 | Cocker | 9 | F | R | none | U, F, PCO, SYN | 5 | 4 | + |
| 22 | Cocker | 8 | F | R | none | U, PCO, SYN | 3 | 11 | + |
| 23 | Cocker | 7 | M | L | none | U, PCO, SYN | 3 | 11 | + |
| 24 | M. Pinscher | 4 | M | R | none | U | 10 | 10 | + |
| 25 | Shih-tzu | 9 | F | R | DL | U | 3 | 11 | + |
| 26 | WHT | 6 | M | L | none | U, F, CE | 3 | 4 | + |

Table 1 Information of dogs, in which phacofragmentation and aspiration surgery was performed, intra- and post-operative complications and visual restoration. Note: M. Pinscher = Miniature pinscher, WHT = West Highland white terrier, M = male, F = female, R = right, L = left, PCR = posterior lens capsule rupture, H = hyphema, M = miosis, DL = displacement of lens into vitreous chamber, U = uveitis, PCO = posterior capsular opacification, SYN = posterior synechia, F = fibrin formation, CE = corneal edema, CU = corneal ulcer, G = glaucoma.

References

- Adkins, E.A. and Hendrix, D.V. 2005. Outcomes of dogs presented for cataract evaluation: a retrospective study. *J. Am. Anim. Hosp. Assoc.* 41(4): 235-240.
- Apple, D.J., Peng, Q., Visessook, N., Werner, L.W., Pandey, S.K., Escobar-Gomez, M., Ram, J. and Auffarth, G.U. 2001. Eradiation of posterior capsular opacification. *Ophthalmol.* 108(3): 505-518.
- Bayramlar, H., Tolan, Y. and Borazan, M. 2004. Heparin in the intraocular irrigating solution in pediatric cataract surgery. *J. Cataract Refract. Surg.* 30(10): 2163-2169.
- Biros, D.J., Gelatt, K.N., Brooks, D.E., Kubilis, P.S., Andrew, M.E., Strubbe, D.T. and Whigham, H.M. 2000. Development of glaucoma after cataract surgery in dogs: 220 cases (1987-1998). *J. Am. Vet. Med. Assoc.* 216(11): 1780-1786.
- Bras, I.D., Colitz, C.M.H., Saville, W.J.A., Gemensky-Metzler, A.J. and Wilkie, D.A. 2006. Posterior capsule opacification in diabetic and nondiabetic canine patients following cataract surgery. *Vet. Ophthalmol.* 9(5): 317-327.
- Chahory, S., Clerc, B., Guez, J. and Sanaa, M. 2003. Intraocular pressure development after cataract surgery: a prospective study in 50 dogs (1998-2000). *Vet. Ophthalmol.* 6(2): 105-112.
- Clark, D.S. 2000. Posterior capsule opacification. *Curr. Opin. Ophthalmol.* 11(1): 56-64.
- Davidson, M.G., Morgan, D.K. and McGahan, M.C. 2000. Effect of surgical technique on in vitro posterior capsule opacification. *J. Cataract Refract. Surg.* 26(10): 1550-1554.
- Durrani, O.M., Mead, C.A. and Murray, P.I. 2004. Uveitis: a potentially blinding disease. *Ophthalmologica.* 218: 223-236.
- Dziezyc, J. 1990. Cataract surgery. *Vet. Clin. North Am. Small Anim. Pract.* 20(3): 737-754.
- Eng-Yiat Yab and Wee-Jin Heng. 2004. Visual outcome and complications after posterior capsule rupture during phacoemulsification surgery. *Int. Ophthalmol.* 23(1): 57-60.
- Ermiss, S.S., Ozturk, F. and Inan, U.U. 2003. Comparing the efficacy and safety of phacoemulsification in white mature and other types of senile cataracts. *Br. J. Ophthalmol.* 87(11): 1356-1359.
- Feyes, J., Fajnkuchen, F. and Salvanet-Bouccara, A. 2000. Factors influencing early post surgical ocular hypertension after phacoemulsification. *J. Fr. Ophthalmol.* 23(9): 884-887.
- Gelatt, K.N. 1997. Visual disturbance: where do I look? *J. Small Anim. Pract.* 38(8): 328-335.
- Gelatt, K.N. and Gelatt, J.P. 2001. Surgical procedures of the lens and cataracts. In: *Small Animal Ophthalmic Surgery*. Massachusette: Reed Educational and Professional Publishing Ltd. 286-335.
- Georgiadis, N., Boboridis, K., Halvatzis, N., Ziakas, N. and Moschou, V. 2003. Low-dose tissue plasminogen activator in the management of anterior chamber fibrin formation. *J. Cataract Refract. Surg.* 29(4): 729-732.
- Gilger, B.C. 2003. Lens. In: *Textbook of Small Animal Surgery*. 3rd ed. D. Slatter (ed.). Philadelphia: W.B. Saunders. 1402-1418.
- Glover, T.D. and Constantinescu, G.M. 1997. Surgery for cataracts. *Vet. Clin. North Am. Small anim. Pract.* 27: 1143-1173.
- Gwon, A.E., Gruber, L.J., Mantras, C. and Cunanan, C. 1993. Lens regeneration in New Zealand albino rabbit after endocapsular cataract extraction. *Invest. Ophthalmol. Vis. Sci.* 34: 2124-2129.
- Jacobi, F.K., Kammann, J., Jacobi, K.W., GroBkopf, U. and Walden, K. 1999. Bilateral implantation of asymmetrical diffractive multifocal intraocular lens. *Arch. Ophthalmol.* 117(1): 17-23.
- Johansson, B.A. and Lundh, B.L. 2003. Bilateral same day phacoemulsification: 220 cases retrospective reviewed. *Br. J. Ophthalmol.* 87: 285-290.
- Kelly, J.S. and Mark, P.N. 2006. Long term complications after phacoemulsification for cataract removal in dogs: 172 cases (1995-2002). *J. Am. Vet. Med. Assoc.* 228(1): 74-79.
- Kobayashi, H., Hirose, M. and Kobayashi, K. 2000. Ultrasound biomicroscopy analysis of pseudophakic pupillary block glaucoma induced by Soemmering's ring. *Br. J. Ophthalmol.* 84(10): 1142-1146.
- Landa, G., Hoffman, P., Pollack, A., Bukulman, A., Leiba, H. and Marcovich, A. 2006. Outcome of posterior capsulotomy in late capsular block syndrome with posterior capsular opacification. *Clin. Exp. Ophthalmol.* 34(99): 866-869.
- Miller, P.E., Stanz, K.M., Dubielziq, R.R. and Murphy, C.J. 1997. Mechanisms of acute intraocular pressure increases after phacoemulsification lens extraction in dogs. *Am. J. Vet. Res.* 58(10): 1159-1165.
- Miller, T.R., Whitley, R.D., Meek, L.A., Garcia, G.A., Wilson, M.C. and Rawls, B.H. 1987. Phacofragmentation and aspiration for cataract extraction in dogs: 56 cases (1980-1984). *J. Am. Vet. Med. Assoc.* 190: 1577-1579.

- Nasisse, M.P. 2001. Diseases of the lens and cataract surgery. 25th Annual Waltham/OSU Symposium: Small Animal Ophthalmology. Proceeding annual meeting of the American College of Vet. Ophthalmol. 9(5):292-298.
- Nielsen, P.J. and Allerod, C.W. 1998. Evaluation of local anesthetic techniques for small incision cataract surgery. *J. Cataract Refract. Surg.* 24: 1136-1144.
- Osher, R.H., Yu, B.C. and Koch, D.D. 1990. Posterior polar cataracts: a predisposition to intraoperative posterior capsular rupture. *J. Cataract Refract. Surg.* 16(2): 157-162.
- Ozgencil, F.E. 2005. The results of phacofragmentation and aspiration surgery for cataract extraction in dogs. *Turk J. Vet. Anim. Sci.* 29(1): 165-174.
- Ozveren, F. and Eltutar, K. 2004. Therapeutic application of tissue plasminogen activator for fibrin reaction after cataract surgery. *J. Cataract Refract. Surg.* 30(8): 1727-1731.
- Pandey, S.K., Cochener, B., Apple, D.J., Collin, J, Werner, L., Bougaran, R., Trivedi, R.H., Macky, T.A. and Izak, A.M. 2002. Intracapsular ring sustained 5-fluorouracil delivery system for the prevention of posterior capsule opacification in rabbits: a histological study. *J. Cataract Refract. Surg.* 28(1): 139-148.
- Peng, Q., Apple, D.J., Visessook, N., Warner, L., Pandey, S.K., Escobar-Gomez, M., Schoderbek, R. and Guindi, A. 2000. Surgical prevention of posterior capsule opacification: Part 2: Enhancement of cortical cleanup by focusing on hydrodissection. *J. Cataract Refract. Surg.* 26: 118-197.
- Petersen-Jones, S.M. 2002. The Lens. In: BSAVA Manual of Small Animal Ophthalmology. S.M. Petersen-Jones and S. Crispin (eds.). 2nd ed. British Small Animal Veterinary Association. England. Woodrow House. 204-218.
- Petersen-Jones, S.M. and Clutton, R.E. 1994. Use of intraocular adrenaline during cataract extraction in dogs. *Vet. Rec.* 135(1313): 306.
- Renwick, P. 1997. Timing of cataract surgery in dogs. *Vet. Rec.* 140(25): 663.
- Riaz, Y., Meht, J.S., Wormald, R., Evan, J.R., Foster, A., Ravilla, T. and Snellin, T. 2006. Surgical interventions for age-related cataract. *Cochrane Database Syst. Rev.* 18(4): CD001323.
- Rubin, L. and Gelatt, K. 1968. Spontaneous resorption of the cataractous lens in dogs. *J. Am. Vet. Med. Assoc.* 152: 139-153.
- Severin, G.A. 1995. Severin's Veterinary Ophthalmology Notes. 3rd ed. Colorado. Design Pointe Communications Inc. 97, 397.
- Shinoda, K., O'hira, A., Ishida, S., Hoshide, M., Ogawa, L.S., Ozawa, Y., Nagasaki, K., Inoue, M. and Katsura, H. 2001. Posterior synechia of the iris after combined pars plana vitrectomy, phacoemulsification and intraocular lens implantation. *Jpn. J. Ophthalmol.* 45(3): 276-280.
- Siddiqui, N. 2001. Ophthalmic Pearls/Cataract: How to performed Nd:Yag capsulotomy. *EyeNet Magazine.* August 1-4. edited by S. Fekrat and I.U.Scott. American Academy of Ophthalmology.
- Tranos, P, Bhar, G. and Little, B. 2004. Review: Postoperative intraocular pressure spikes: the need to treat. *Eye.* 18: 673-679.
- Trinavarat, A., Atchaneeyasakul, L.O., Surachat-kumtonekul, T. and Kosrirukvongs, P. 2003. Comparison of topical prednisolone acetate, ketorolac tromethamine and fluorometholone acetate in reducing inflammation after phacoemulsification. *J. Med. Assoc. Thai.* 86(2): 143-150.
- Tyagi, A.K. and McDonnell, P.J. 1998. Visual impairment due to bilateral corneal endothelial failure following simultaneous bilateral cataract surgery. *Br. J. Ophthalmol.* 82(11): 1341-1342.
- van der Woerd, A. 2000. Lens-induced uveitis. *Vet. Ophthalmol.* 3(4): 227-234.
- van der Woerd, A., Nasisse M.P. and Davidson, M.G. 1992. Lens-induced uveitis in dogs: 151 cases 1985-1990. *J. Am. Vet. Med. Assoc.* 201(6): 921-926.
- van der Woerd, A., Wilkie, D.A. and Myer, C.W. 1993. Ultrasonographic abnormalities in the eyes of dogs with cataracts: 147 cases (1986-1992). *J. Am. Vet. Med. Assoc.* 203: 838.
- Warren, C. 2004. Phaco chop technique for cataract surgery in the dog. *Vet. Ophthalmol.* 7(5): 348-351.
- Wilhelmus, K.R. and Emery, J.M. 1980. Posterior capsule opacification following phacoemulsification. *Ophthalmic Surg. Las.* 11: 264-267.
- William, D.L. and Munday, P. 2006. The effect of a topical antioxidant formulation including N-acetyl carnosine on canine cataract: a preliminary study. *Vet. Ophthalmol.* 9(5): 317-327.
- Williams, G.L., Brannan, S., Forrester, J.V., Gaviv, M.P., Paterson-Brown, S.P., Purdie, A.T., Viridi, M. and Olson, J.A. 2007. The prevalence of sight-threatening uveitis in Scotland. *Br. J. Ophthalmol.* 91: 33-36.