

Ultrasound Diagnosis

Phiwipha Kamonrat

History

A five-year-old, female, intact, Golden Retriever dog was presented at the Chulalongkorn University, Small Animal, Veterinary Teaching Hospital with a history of hematuria for three days duration. The dog also had clinical signs of depression, anorexia and urine incontinence. A physical examination revealed slightly pale mucous membranes and a moderate urinary bladder distention. No palpable abdominal abnormalities were detected. Haematological and biochemical profiles were within normal limits. Urinalysis performed was unremarkable. Survey abdominal radiographs demonstrated moderate urine retention with no evidence of any radiopaque calculi. On the pneumocystogram, the bladder wall was focally thickened and irregular at the cranioventral aspect but no distinct mass was identified. An abdominal ultrasonography was performed to obtain a more specific information.

Ultrasonographic Findings

Trans-abdominal ultrasonography was performed, using a real-time scanner with an 9-4 MHz broadband, convex, phased array transducer. The urinary bladder contained a moderate amount of anechoic urine, with some sediments. The urinary bladder wall was smooth, echoic, and 2.7 mm thick, with a pedunculated mucosal mass projecting into the lumen (Figure 1 and 2). This mass originated from a 1-cm base of attachment to the 4-mm-thickened left cranial bladder wall. It was smooth, homogeneous, isoechoic to bladder wall and measured approximately 1 by 2 cm². It had a well-defined margin. The extent of bladder wall involvement could not be determined. Based on color doppler examination, there was no detectable blood flow within the mass. The remainder of the abdominal organs, including the medial iliac lymph nodes, appeared normal.

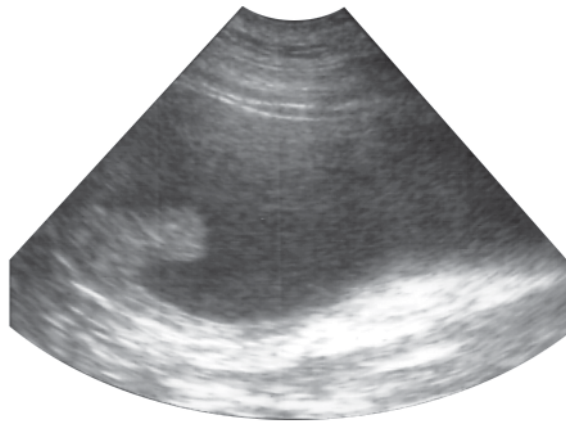


Figure 1 A sagittal ultrasonogram of the cranial portion of the urinary bladder in a 5-year-old, female, Golden Retriever dog in dorsal recumbency. The urinary bladder contained a moderate amount of anechoic urine, with some sediments. A pedunculated, homogeneously isoechoic, intraluminal mass was located in the left cranial aspect of the urinary bladder wall.

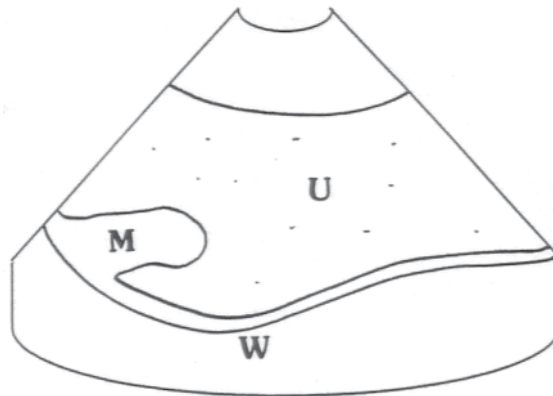


Figure 2 Schematics of the relative positions of the structures scanned in figure 1. U-anechoic urine with some sediments; W-smooth, echoic, urinary bladder wall; M-isoechoic, pedunculated, intraluminal mass.

Diagnosis

Ultrasonographic diagnosis—A polypoid cystitis.

Comments

Polypoid cystitis is characterized by urinary bladder wall thickening accompanied by a variable number of small masses that protrude from the mucosa into its lumen. In general, ultrasonographic images of polypoid cystitis are well correlated with contrast

radiographic studies and gross morphological appearances. Normal urinary bladder wall thickness in a fully distended bladder is approximately 1 to 2 mm. It varies with the degree of bladder distention and increases with body weight (Geisse et al., 1997). Masses can easily be overlooked in a collapsed bladder.

Ultrasound is a non-invasive, very useful diagnostic tool for detecting bladder polyps, but histopathology is required for definitive diagnosis.

Blood clots and tumors may mimic the ultrasonographic appearance of polypoid cystitis in dogs. The ultrasonographic appearance of polypoid cystitis in dogs is mucosal projections of single or multiple polypoid to pedunculated masses of variable size and shape as well as a variably thickened bladder wall (Takiguchi and Inaba, 2005). A mucosal projection without an obvious luminal mass cannot rule out polypoid cystitis. The echogenicity of the mass is commonly isoechoic compare to the bladder wall. Compared with neoplasia, polyps may have pedunculated base of attachment and locate in the cranial portion of bladder wall, while neoplasia is more likely sessile and has a predilection for

the bladder neck or trigone region. The iliac lymph nodes and adjacent structures should be ultrasonographically examined for possible metastasis when neoplasia is suspected.

References

- Geisse A.L., Lowry J.E., Schaeffer D.J. and Smith C.W. 1997. Sonographic evaluation of urinary bladder wall thickness in normal dogs. *Vet. Radiol. Ultrasound*. 38:132-137.
- Takiguchi M. and Inaba M. 2005. Diagnostic ultrasound of polypoid cystitis in dogs. *J. Vet. Med. Sci.* 67(1): 57-61.