

What is Your Diagnosis

Pranee Tuntivanich Suwicha Chuthatep

Signalment

A 6-year-old male Poodle.

History

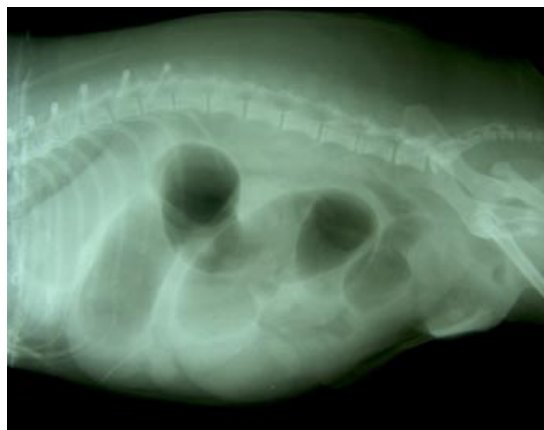The dog had been showing an inguinal hernia for a month. The owner noticed that a dog had had a rapid increase in the hernial size during the past week and a persistent vomiting during the last 2 days before he was presented at the small animal hospital.

Clinical Examination

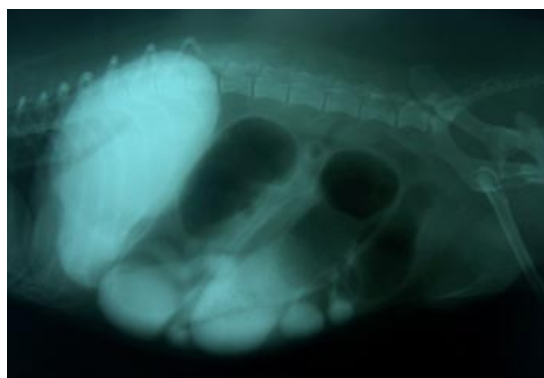There was an obvious abdominal expansion. The dog showed pain on palpation of the caudal abdomen. Hematologically, liver and renal profiles were normal, only mild hypoalbuminemia could be detected.

Radiographic Examination

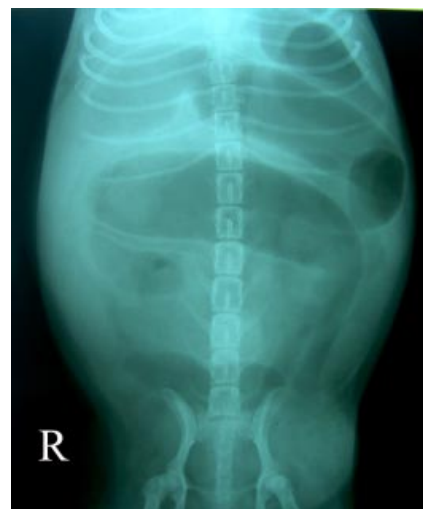In addition to plain abdominal radiographs, 60 minutes after positive contrast medium (omnipaque) administration radiographs of the right lateral and ventrodorsal views were taken to evaluate gastrointestinal tract abnormalities.



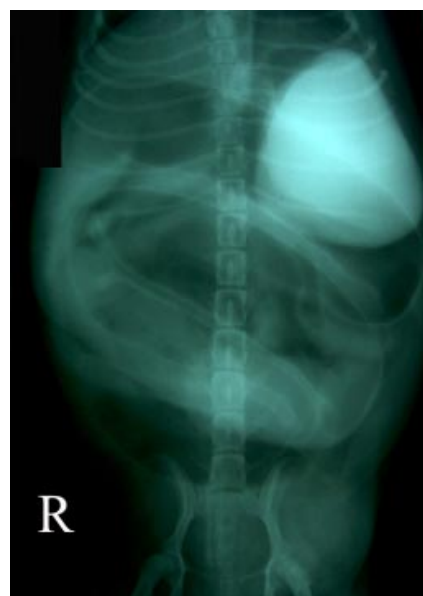(1A)



(2A)



(1B)



(2B)

Figure 1. A, B. Right lateral and ventrodorsal abdominal radiographs.

Figure 2. A, B. Right lateral and ventrodorsal abdominal radiographs taken at time 60 minutes after positive contrast administration.

Give your diagnosis and turn to the next page.

Radiographic findings

Plain radiographs (Fig. 1A, B) revealed a generalized extensive air-distended small bowel loops, approximately 4 times normal diameter (white arrows). There was a large soft tissue swelling on the left inguinal area on the ventrodorsal abdominal radiograph (Fig. 1B). The Right lateral and ventrodorsal abdominal radiographs at time 60 minutes after positive contrast administration

(Fig. 2A, B) presented an accumulation of a large amount of positive contrast medium in both fundus and body of the stomach with delayed small bowel transit time. The positive contrast medium was not apparent in the colon. There was no evidence of mucosal irregularities, wall thickenings or filling defects in the stomach and small intestine.

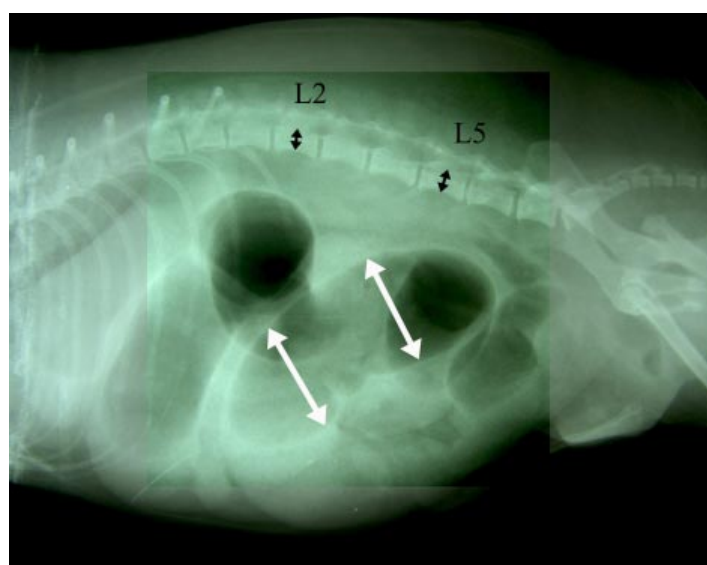


Figure 3. The small bowel dilatation can be easily evaluated by comparing with the height of the central part of the body of L2 or L5 which is normally seen in the plain lateral abdominal radiograph.

Radiographic diagnosis

Mechanical obstruction of the small intestine due to inguinal herniation

Discussion

In general, the maximal normal diameter of small bowel in dog can be measured following one of three guidelines: (1) not exceeding twice the width of a rib, (2) not exceeding the height of the central part of the body of L2 and (3) a ratio of the maximal small intestinal diameter to the height of the body of L5 at its narrowest point that is less than 1.6. The abnormal dilatation of the small intestine is caused by various reasons for example foreign body, intussusception, bowel wall neoplasia, bowel stricture, postsurgical adhesion, herniation and paralysis.

Barium sulphate suspension (5-7 ml/kg in medium to large breed dogs and 8-10 ml/kg and cats and small dogs) and water solution iodine contrast medium (2-3 ml/kg) can be used as positive contrast media to evaluate upper gastrointestinal tract (esophagus, stomach and small intestine).

References

- Bradley K. 2005. Practical contrast radiography 2. Gastrointestinal studies. In Practice. 27(9): 412-417.
- Thrall D.E. 2002. The Small Bowel. In: Textbook of Veterinary Diagnostic Radiology. 4thed. W.B Saunder company. Pennsylvania. 639- 660.