

Treatment of Infected Open Wounds on Two Dogs Using a Film Dressing of Polysaccharide Extracted from the Hulls of Durian (*Durio zibethinus* Murr.): case report

Piyarat Chansiripornchai^{1*} Sunanta Pongsamart²

Abstract

There have been many reports on the efficacy of the polysaccharide peptidoglycan (PG) isolated from durian hulls in assisting wound healing in pig, dog, and cat skin. In this report, a two - year - old and a three - year - old female mongrel dogs with infected open wounds and skin necrosis were treated with PG film dressing. Complete wound healing in both dogs occurred within 14 weeks of treatment. PG film dressing may effectively promotes wound healing. The results show the benefit of using PG film dressings in pharmaceutical and veterinary applications.

Keywords : dog, durian hulls, wound healing

¹Department of Veterinary Pharmacology, Faculty of Veterinary Science

²Department of Biochemistry, Faculty of Pharmaceutical Sciences, Chulalongkorn University, Bangkok 10330

*Corresponding author

บทคัดย่อ

การรักษาแผลเปิดที่มีการติดเชื้อในสุนัข 2 ตัว ด้วยฟิล์มปิดแผลโพลีแซ็กคาไรด์สกัดจากเปลือกผลทุเรียน: รายงานสัตว์ป่วย

ปิยะรัตน์ จันทศิริพรชัย^{1*} สุนันท์ พงษ์สามารถ²

มีรายงานว่าสารโพลีแซ็กคาไรด์ (พีจี) ที่สกัดได้จากเปลือกผลทุเรียนมีประสิทธิภาพช่วยในการหายของแผลบนผิวหนังสุนัข และแมว ในรายงานนี้ได้ใช้พีจีรักษาแผลเปิดที่มีเนื้อตายในสุนัขไทยพันธุ์ผสมจำนวน 2 ตัว พบว่าพีจีช่วยในการหายของแผลอย่างสมบูรณ์ภายใน 14 สัปดาห์ของการรักษา ผลการศึกษาครั้งนี้แสดงให้เห็นถึงประโยชน์ของพีจีในทางเภสัชวิทยา และการนำมาประยุกต์ใช้ในทางสัตวแพทย์

คำสำคัญ: สุนัข เปลือกทุเรียน การหายของแผล

¹ภาควิชาเภสัชวิทยา คณะสัตวแพทยศาสตร์

²ภาควิชาชีวเคมี คณะเภสัชศาสตร์ จุฬาลงกรณ์มหาวิทยาลัย กรุงเทพฯ 10330

*ผู้รับผิดชอบบทความ

Introduction

Durian (*Durio zibethinus* Murr.) is one of the most popular fruits in Thailand and its hull is a major waste problem. Recently, the polysaccharide peptidoglycan (PG) was isolated from durian hulls (Pongsamart and Panmaung, 1998). PG is a water-soluble heteropoly-saccharide containing acidic and neutral chains of rhamnogalacturonan with neutral sugars branched regions (Hokputsa et al., 2004). PG reportedly produced satisfactory results when used as an excipient in pharmaceutical and food preparation (Lertchaiporn et al., 2002). Toxicity studies indicate that PG is non-toxic in mice and rats subjected to acute and subchronic toxicity tests (Pongsamart et al., 2001; Pongsamart et al., 2002). Girddit et al. (2001) found that PG can be used as a good film-forming agent and can be made into satisfactory dressing patches in both film and fiber forms (Fig. 1). The antibacterial activity of PG has also been studied and the results indicate that PG is effective against *Staphylococcus aureus* and *S. epidermidis*, which are normally involved in wound infections (Pongsamart et al., 2005). Recently, there have been many reports of the application of PG film dressings in treating full-thickness excisional wounds in the skin of pigs

(Chansiripornchai et al., 2005) and in surgical wounds in dog and cat skin (Chansiripornchai et al., 2004). Moreover, the treatment of infected open wounds in a dog using PG film dressing has also been reported (Chansiripornchai et al., 2005). These reports confirm the high-level efficacy of PG for wound healing. In the present report, a PG film dressing was used to treat infected open wounds in two dogs.

Case history

Case 1 was a two-year-old female mongrel dog with infected open wounds caused by accidental exposure to hot water. The wounds had been treated at another animal hospital by wound dressing for 12 days and by oral enrofloxacin, transamin and carprofen.

Case 2 was a three-year-old female mongrel dog with an infected open wound caused by a car accident. The wound had been treated at another animal hospital by wound dressing for 10 days and by oral cephalixin and metronidazole.

Diagnosis and treatment

On physical examination, case 1 appeared in good general health. Clinical examination revealed open

wounds with necrotic tissue caused by exposure to hot water along the left part of the dog's body (Fig. 2a). In case 2, the dog also appeared to be in good general health. Clinical examination revealed open wounds with purulent discharge and necrotic tissue caused by car impact on the right inguinal area (Fig. 3a) and on the neck (Fig. 4a).

Blood samples for haematological and biochemical analyses were taken from the cephalic vein of both dogs. Blood smears were stained with Giemsa- Romanowski stain and evaluated. Serum biochemical analyses of alanine aminotransferase (ALT) and creatinine were conducted using the Fuji Dri-Chem 3500i automated clinical chemistry analyzer (Fujifilm, Tokyo, Japan). Hematological and biochemical results were within the normal range for these dogs.

On day 0 after cleaning with diluted hydrogen peroxide solution and then 0.9% normal saline and trimming the necrotic tissue, the wounds of both dogs were covered with PG film dressing and then bandaged. Instead of using oral enrofloxacin as prescribed by the previous animal hospital for 12 days, we intramuscularly injected amoxicillin LA (Duphamox LA, Fort Dodge Animal Health, The Netherlands) at 10 mg/kg every 48 hours three times, in case 1. In case 2, cephalexin (Lakflex, Qualimed Co. Ltd., Thailand) was given orally at 22 mg/kg every 12 hr for 2 weeks. For topical treatment in both dogs, the wounds were cleaned and covered with PG film dressing, as on day 0, and then at 1- to 3-day intervals. Thereafter, the wounds were examined for healing characteristics and recorded using a Powershot S50 digital camera (Cannon, Chichibu, Japan) at the time of topical treatments.

Results and Discussion

Skin generally needs to be covered with a dressing immediately after it is damaged (Lu et al., 2008). At present, there are 3 categories of wound dressing: biologic, synthetic and biologic-synthetic. These 3 categories of wound dressing are all used frequently in the clinical setting, but none is without disadvantages (Lu et al., 2008).




Figure 1 PG dressing. a: PG film; b: PG fibre.

In general, open wounds heal by means of inflammation and cellular response, leading to granulation tissue formation, re-epithelialization, and wound contraction (Bauer and Aiken, 1989; Clark and Denver, 1985). It has been shown experimentally that wounds re-epithelialize more rapidly under moist condition than dry condition (Suzuki et al., 1998) and the rate of dermal repair has been found to increase under moist conditions (Dyson et al., 1991). Therefore, several dressings that can maintain moist wound conditions, such as hydrogel, are currently used in managing partial or full-thickness wounds. However, using commercial dressings, such as hydrogel for the long-term treatment of wounds is expensive in Thailand, since the materials must be imported. Therefore, we have attempted to find a new material for wound healing support with properties similar to those of hydrogel.

In this report, a dramatic response was observed in both dogs after one week of treatment using the PG film dressing and the wound width decreased week by week in both cases (Figs. 2, 3, and 4). In particular, the wound width in both dogs decreased very rapidly in weeks 1-4 of treatment. The case 1 and case 2 dogs were returned home when the wound became satisfactory small in weeks 9

and 12 of treatment, respectively. Subsequently, the wounds were treated by the dogs' owners using the same methods as used in the animal hospital. Through telephone contact with the owner of case 1, complete wound healing occurred within 14 weeks of initial treatment. In case 2, the wounds in the right inguinal area and the neck healed completely within 14 and 5 weeks of initial treatment, respectively.

PG film dressing is a new material and is beneficial for wound healing. Since PG is a polymer from a plant, like the starch copolymer in hydrogel, it can be used to support wound healing. In the present report, we examine

the efficacy of PG film dressing for wound healing in burnt and infected open wounds that caused a large area of skin loss in the two studied dogs. After using the PG film dressing for a week, the wounds on both dogs shrank rapidly and the necrotic tissue disappeared. Granulation tissues grew and new skin was revealed within 2 weeks and complete wound healing was observed within 14 weeks. From the authors' experience, wound healing rate for this type of infected open wound needs several months for complete wound closure and it takes high cost of treatment. Furthermore, many factors such as severity

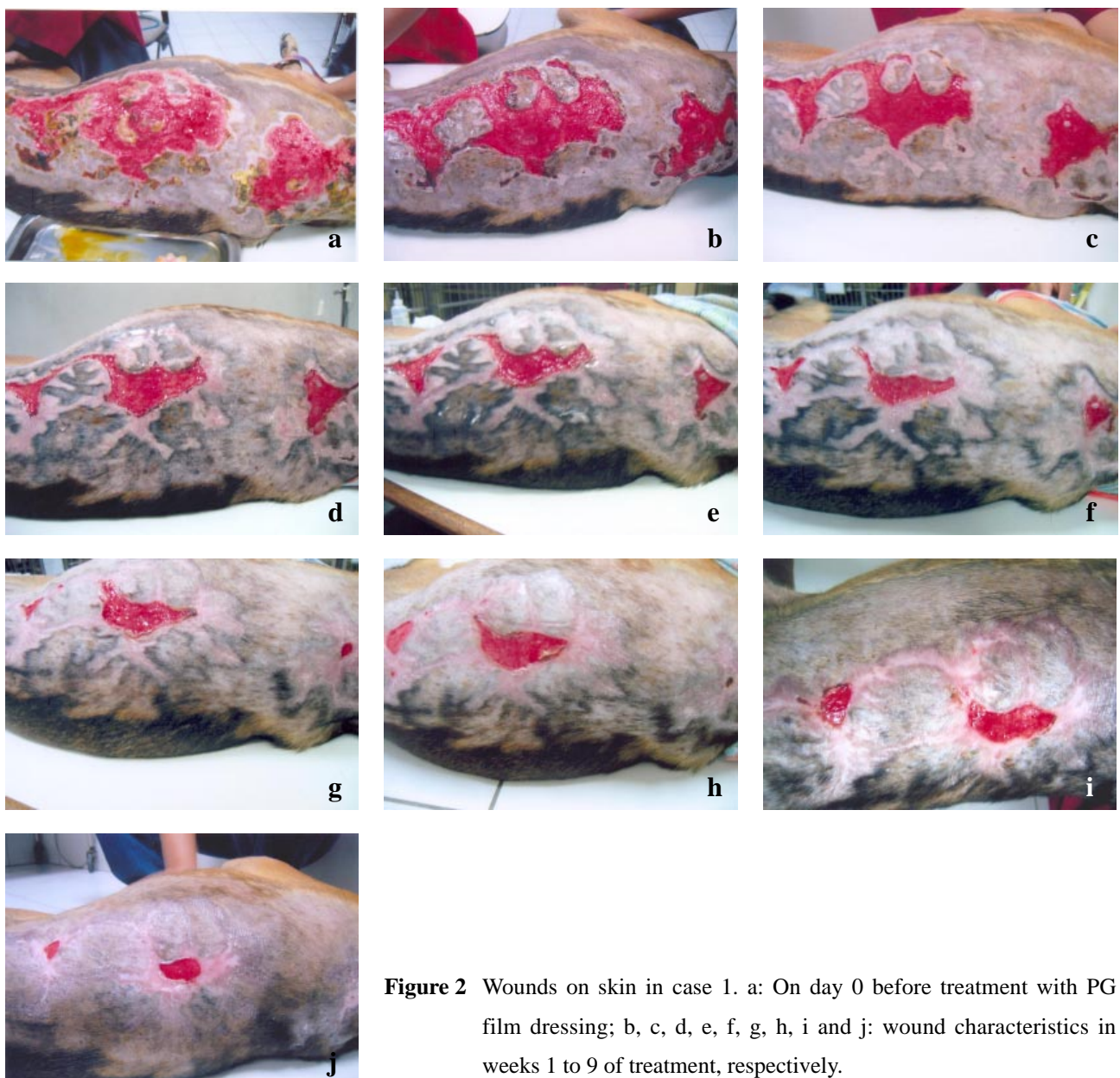


Figure 2 Wounds on skin in case 1. a: On day 0 before treatment with PG film dressing; b, c, d, e, f, g, h, i and j: wound characteristics in weeks 1 to 9 of treatment, respectively.

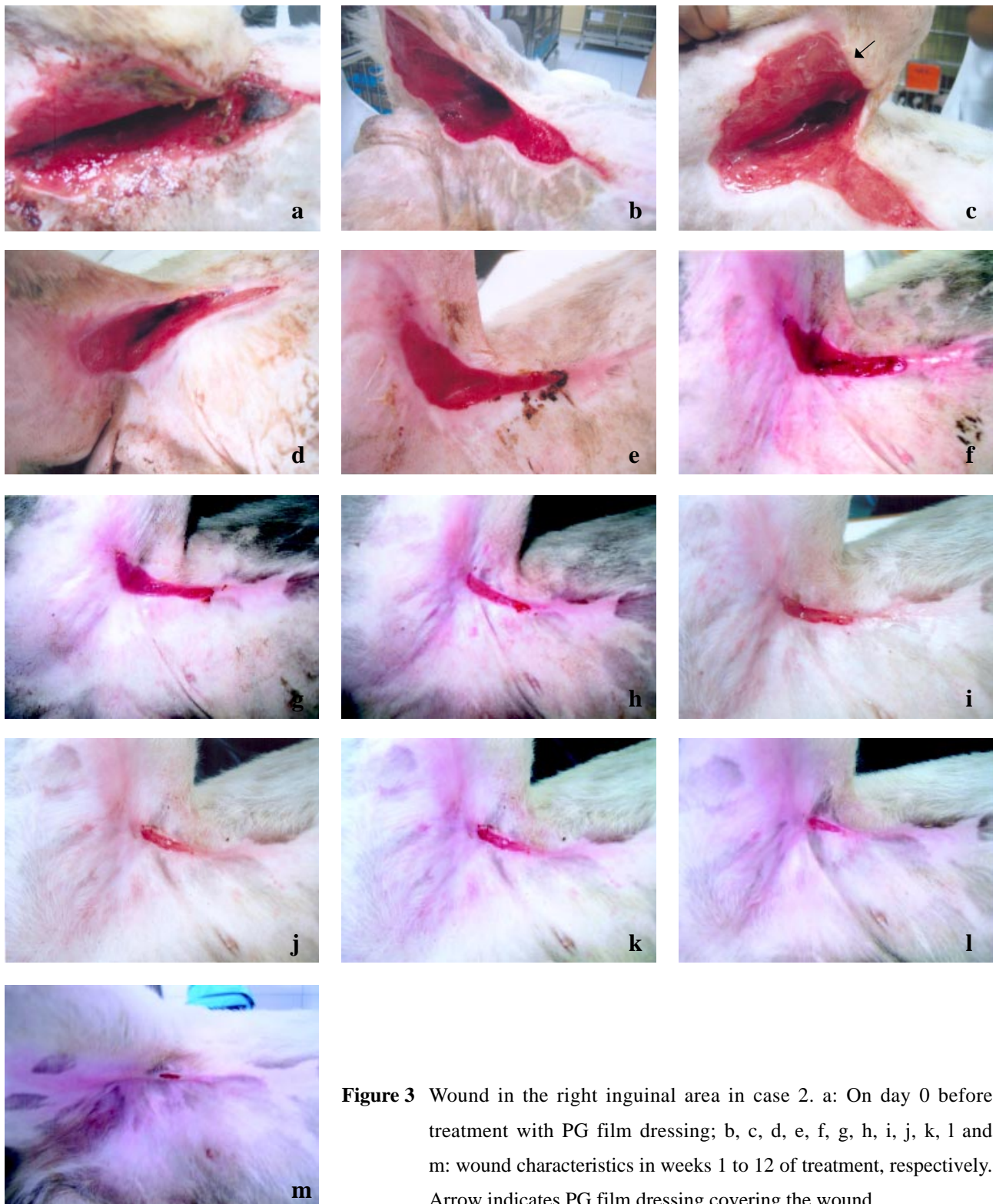


Figure 3 Wound in the right inguinal area in case 2. a: On day 0 before treatment with PG film dressing; b, c, d, e, f, g, h, i, j, k, l and m: wound characteristics in weeks 1 to 12 of treatment, respectively. Arrow indicates PG film dressing covering the wound.

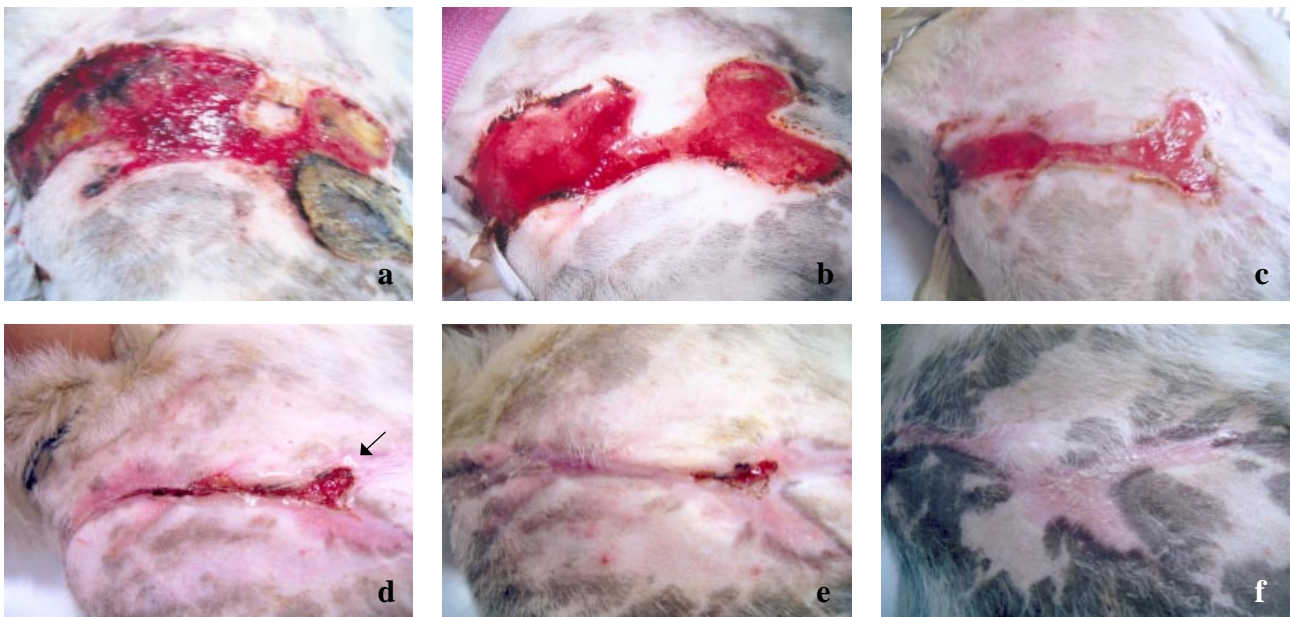


Figure 4 Wound in the neck in case 2. a: On day 0 before treatment with PG film dressing; b, c, d, e and f : wound characteristics in weeks 1 to 5 of treatment, respectively. Arrow indicates PG film dressing covering the wound.

of inflammation and infection of the wound are considered to be the contributors to wound healing (Mahmood et al., 2005). The reasons that support the use of PG film dressing for wound healing are: (1) its moisture adsorption properties that promote healing and epidermal regeneration; (2) it is a water-soluble film that can be removed by washing with water but does not destroy newly formed epithelium; (3) it inhibits the growth of *S. aureus* and *S. epidermidis*, which are found on skin and can cause wound infections; and (4) it is extracted from a natural product proven to be non-toxic to tissue (Chansiripornchai et al., 2005).

This case report indicates an alternative use of the PG extracted from durian hulls, as a film dressing to promote wound healing. The results show the benefits of using PG film dressing in pharmaceutical and veterinary applications.

Acknowledgments

The authors would like to thank the dogs' owners for their kind co-operation. Dr. Pitcha Pornmingmas, Dr. Bongkot Suparp and Dr. Supattra Yongsiri

from Suvarnachad Animal Hospital are gratefully acknowledged for their assistance.

References

- Bauer, M.S. and Aiken, S. 1989. The healing of open wounds. *Sem. Vet. Med. Surg.* 4: 268-273.
- Chansiripornchai, P., Chansiripornchai, N. and Pongsamart, S. 2004. Evaluation of polysaccharide, extracted from the fruit-hulls of durian (*Durio zibethinus* L.) on surgical wound healing in dogs and cats. In: *Proceedings of the 13th FAVA Congress*: 25-27 Oct. 2004: Seoul, Korea, p. 285.
- Chansiripornchai, P., Panichkriangkrai, W., Rungsipipat, A., Pramatinai, C., Birksawan, P., Komin, K., Chuthatep, S. and Pongsamart, S. Case report: The treatment of open wounds in a dog using a polysaccharide-extracted from the fruit-hull of durian (*Durio zibethinus* L.) and used as a film dressing. In: *Proceedings of the 11th VPAT Conference*: 25-27 May 2005: Bangkok, Thailand, p. 323-329.

- Chansiripornchai, P., Pramatinwai, C., Rungsipipat, A., Pongsamart, S. and Nakchat, O. 2005. The efficiency of polysaccharide gel extracted from fruit-hulls of durian (*Durio zibethinus L.*) for wound healing in pig skin. *Acta Hort.* 679: 37-43.
- Clark, R.A.F. and Denver, M.D. 1985. Cutaneous tissue repair: basic biologic considerations. *J. Am. Acad. Dermatol.* 13: 701-725.
- Dyson, M., Young, S.R., Pendle, L., Webster, D.F. and Lang, S. 1991. Comparison of the effects of moist and dry conditions on dermal repair. *J. Inve. Dermatol.* 91: 434-439.
- Girdit, W., Tipayakul, C., Lertchaiporn, J., Sutanthavibul, N. and Pongsamart, S. 2001. Characterization and properties of polysaccharide gel from durian fruit-hulls. *Thai J. Pharm. Sci.* 25 (suppl.): 6.
- Hokputsa, S., Girdit, W., Pongsamart, S., Inngjerdigen, K., Heinze, T., Koschella, A., Harding, SE. and Paulsen, BS. 2004. Water-soluble polysaccharides with pharmaceutical importance from durian rinds (*Durio zibethinus Murr.*): isolation, fractionation, characterization and bioactivity. *Carbohydrate Polymers.* 56: 471-481.
- Lertchaiporn, J., Vayamhasuwan, P. and Pongsamart, S. 2002. Acidic polysaccharide gel from durian fruit-hulls as a surfactant for the preparation of vitamin E gel and lotion. *Thai J. Pharm. Sci.* 26: 159.
- Lu, S., Gao, W. and Gu, H.Y. 2008. Construction, application and biosafety of silver nanocrystalline chitosan wound dressing. *Burns* 34: 623-628.
- Mahmood, A. A., Sidik, K. and Salmah, I. 2005. Wound healing activity of *Carica papaya L.* aqueous leaf extract in rats. *Int. J. Mol. Med. Adv. Sci.* 4: 398-401.
- Pongsamart, S., Nanatawanit, N., Lertchaipon, J. and Lipipun, V. 2005. Novel water soluble antibacterial dressing of durian polysaccharide gel. *Acta Hort.* 678: 65-73.
- Pongsamart S. and Panmaung, T. 1998. Isolation of polysaccharides from fruit-hulls of durian (*Durio zibethinus L.*). *Songklanakarin J. Sci. Technol.* 20: 323-332.
- Pongsamart, S., Sukrong, S. and Tawatsin, A. 2001. The determination of toxic effects at a high oral dose of polysaccharide gel extracts from fruit-hulls of durian (*Durio zibethinus L.*) in mice and rats. *Songklanakarin J. Sci. Technol.* 23: 55-62.
- Pongsamart, S., Tawatsin, A. and Sukrong S. 2002. Long-term consumption of polysaccharide gel from durian fruit-hulls in mice. *Songklanakarin J. Sci. Technol.* 24: 555-567.
- Suzuki, Y., Nishimura, Y., Tanihara, M., Suzuki, K., Nakamura, T., Shimizu, Y., Yamawaki, Y. and Kakimaru, Y. 1998. Evaluation of a novel alginate gel dressing: cytotoxicity to fibroblasts *in vitro* and foreign-body reaction in pig skin *in vivo*. *J. Biomed. Mater. Res.* 39: 317-322.