

Ultrasound Diagnosis

Phiwipha Kamonrat

History

A nine-month-old, spayed female, domestic short-hair cat was presented at the Chulalongkorn University, Small Animal, Veterinary Teaching Hospital for evaluation of a several-week duration of progressive abdominal distension. The cat had undergone an ovariohysterectomy two months ago. There was no history or evidence of trauma. The cat was in good body condition, had a normal appetite and showed no clinical signs. Water intake and urination were normal. A physical examination revealed slightly pale mucous membranes and a tense abdomen. A firm mass, about 4 x 6 cm in diameter was palpated in the region of the right kidney. Results of a complete blood count and serum biochemical analyses were within normal limits. Blood morphology showed anisocytosis. A urine specimen could not be obtained. Plain radiographs of the abdomen demonstrated right renomegaly, of soft tissue opacity and a round to oval shape with smooth margins. The gastrointestinal tract was normal in appearance. Ultrasonography of the kidneys and the entire abdomen were performed.

Ultrasonographic Findings

Real-time, ultrasonography was performed using an 8 MHz microconvex, phased array transducer with the cat in dorsal recumbency. A moderate volume of anechoic fluid accumulated in the peritoneal cavity. Echogenicity of the renal cortex is slightly greater than that of hepatic parenchyma and slightly less than that of splenic parenchyma, compared at approximately the same depth. A hyperechoic band was observed at the corticomedullary junction of each kidney. The renal contour was smooth. Linear measurements of right and left kidneys were 3.1 x 3.7 and 2 x 3.3 cm, respectively. The right kidney was surrounded by a moderate amount of anechoic fluid containing echogenic strands (Figure 1 and 2). The entire right kidney, including the surrounding subcapsular fluid, measured 4.2 x 5 cm in diameter. The urinary bladder was moderately distended with urine containing some sediments. The urinary bladder wall was smooth and 1.1 mm thick. Other abdominal organs appeared normal in echotexture.

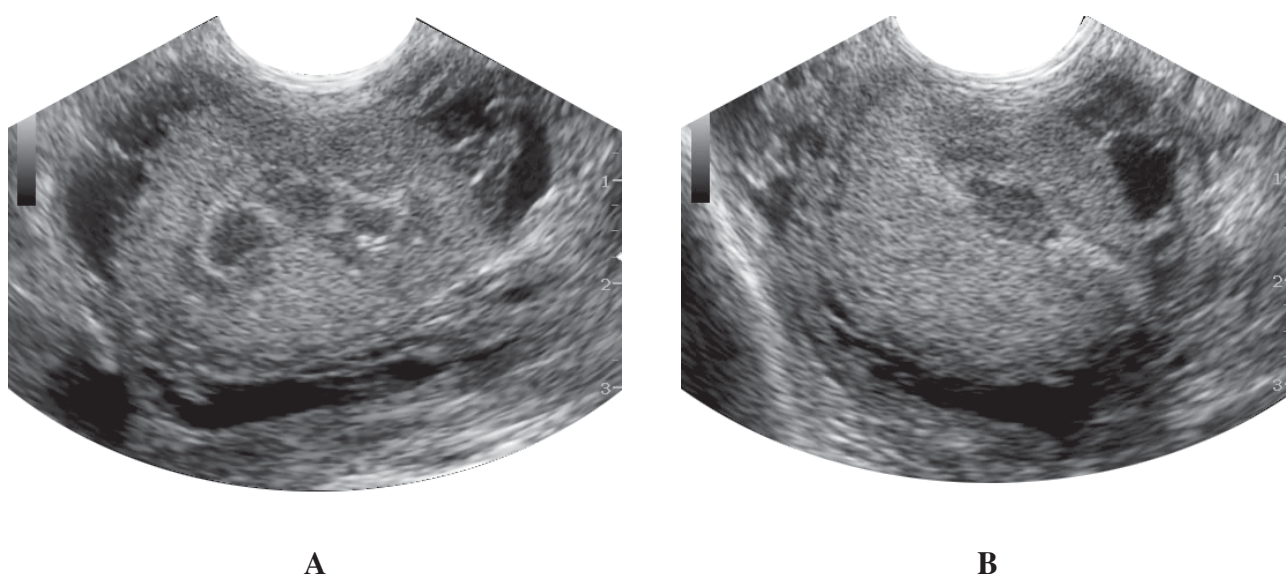


Figure 1 Sagittal (A) and transverse (B) ultrasonographic images through the right kidney, of nine-month-old, domestic short-hair cat, in dorsal recumbency. A moderate volume of anechoic fluid accumulation with strands in it, surrounds the renal parenchyma in this cat with a perinephric pseudocyst. A hyperechoic band has also been observed at the corticomedullary junction.

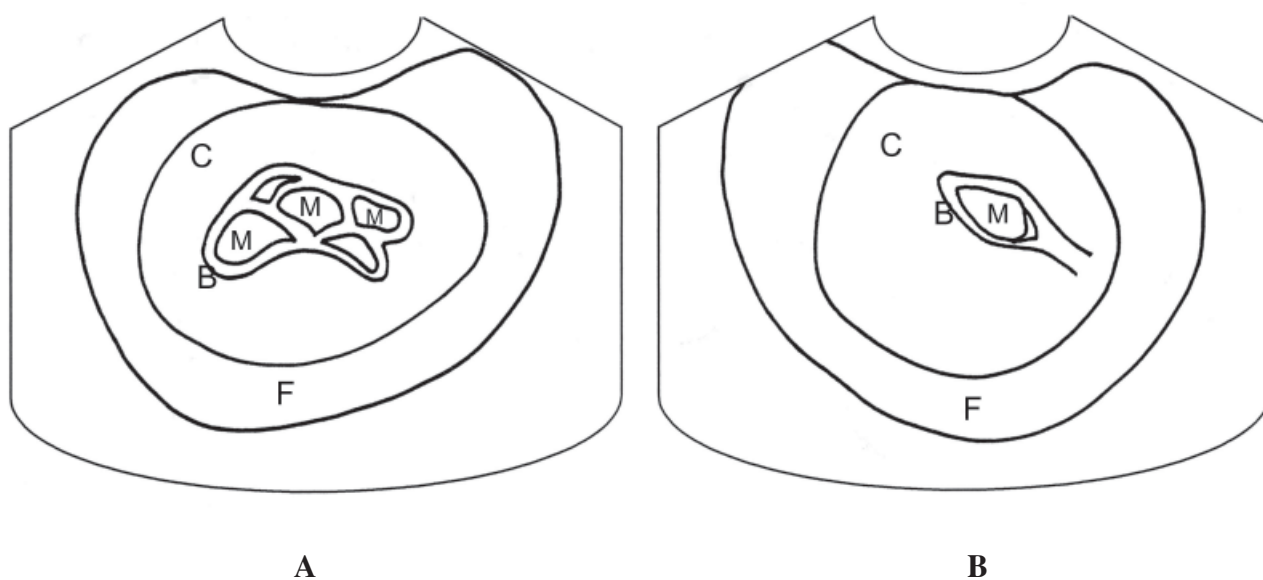


Figure 2 Schematics of the relative positions of the structures scanned in figure 1. F-anechoic fluid; C-renal cortex; M -renal medulla; B-a hyperechoic band that parallels the corticomedullary junction.

Diagnosis

Ultrasonographic diagnosis — Unilateral perinephric pseudocysts.

Comments

Perinephric pseudocysts are formed in cats by accumulation of large amounts of cystic fluid between the capsule and parenchyma of one or both kidneys. This disorder is also known as capsular hydronephrosis, capsular cyst, capsulogenic renal cyst, pararenal pseudocyst and perirenal pseudocyst. The cyst is termed pseudocyst because it is a fluid-filled fibrous sac that is not lined by an epithelium. Perinephric pseudocysts are usually seen in older male cats and are infrequently seen in dogs. There is no sex or breed predilection. The cause of pseudocyst formation is usually unknown. It is commonly associated with chronic renal failure and urinary tract infection (Ochoa et al., 1999). It is unclear if underlying renal disease causes perinephric pseudocyst or the pseudocyst causes renal failure. Differential diagnosis of perinephric pseudocysts can be made by multiple imaging modalities (Essman et al., 2000). However, ultrasound examination is a less-invasive technique used to define perinephric pseudocysts. An ultrasound-guided, fine-needle, aspiration further helps in classifying the pseudocyst fluid of mixed echogenicity. Ultrasonographic findings that are consistent in appearance with perinephric pseudocyst include the presence of a large amount of encapsulated, anechoic fluid surrounds the kidney, between the renal parenchyma and renal capsule, and may extend into the caudal retroperitoneal space.

In the cat, the increase in renal cortical echogenicity, relative to liver and spleen, and the presence of a hyperechoic band at the corticomedullary junction

during ultrasonography may be normal or abnormal. Fat vacuoles in the cortical tubular epithelium may increase renal cortical echogenicity of normal cats (Yeager and Anderson, 1989). The hyperechoic band observed at the corticomedullary junction is associated with mineral deposits in the medullary tubular lumen (Barr et al., 1989).

Pseudocyst formation can occur at variable degrees of renal dysfunction on presentation. The prognosis for cat with pseudocyst formation is related to the degree of renal dysfunction at time of diagnosis. Analysis of the pseudocyst fluid is usually consistent with a transudate. In this cat, *Staphylococcus coagulase* was found in the serosanguineous fluid aspirated from the pseudocyst surrounding the right kidney, following percutaneous fine-needle drainage one month later.

References

- Barr, F.J., Patteson, M.W., Lucke, V.M. and Gibbs, C. 1989. Hypercalcemic nephropathy in three dogs: Sonographic appearance. *Vet. Radiol.* 30: 169-173.
- Essman, S.C., Drost, W.T., Hoover, J.P., Lemire, T.D. and Chalman, J.A. 2000. Imaging of a cat with perirenal pseudocysts. *Vet. Radiol. Ultrasound.* 41: 329-334.
- Ochoa, V.B., DiBartola, S.P., Chew, D.J., Westropp, J., Carothers, M. and Biller, D. 1999. Perinephric pseudocysts in the cat: A retrospective study and review of the literature. *J. Vet. Intern. Med.* 13: 47-55.
- Yeager, A.E. and Anderson, W.I. 1989. Study of association between histologic features and echogenicity of architecturally normal cat kidneys. *Am. J. Vet. Res.* 50: 860-863.