

What is Your Diagnosis

Pranee Tuntivanich Suwicha Chuthatep

Signalment:

A 6-year-old male Golden retriever.

History:

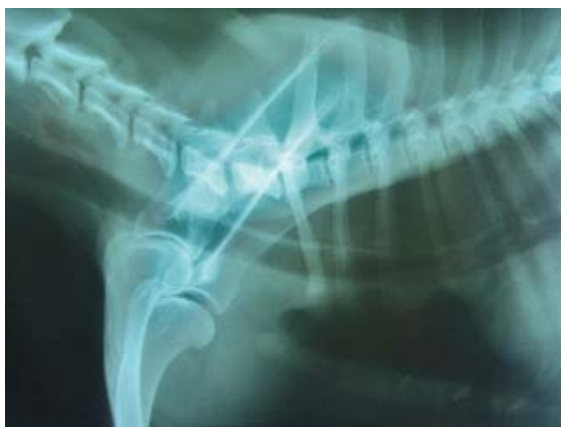The dog had had megaesophagus for a year and had continuing medical treatment. Severe regurgitation and vomiting had been presented for the past 5 days before the dog was presented at the hospital.

Clinical Examination:

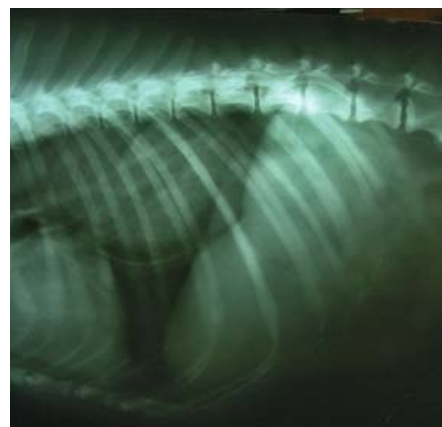
The dog showed mild abdominal pain. There was no evidence of abnormal mass via abdominal palpation. Hematologically, anemia and mild increase of liver profile could be detected. Blood electrolyte profile showed alkalosis.

Radiographic Examination:

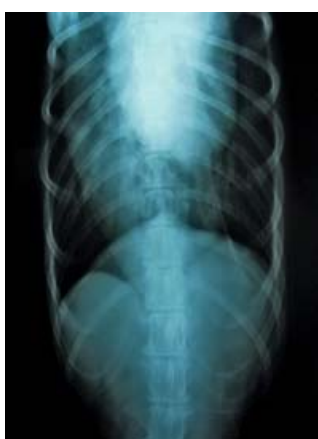In addition to plain thoracic radiographs, positive contrast esophagography (barium sulfate swallow) were performed to evaluate esophageal abnormalities.



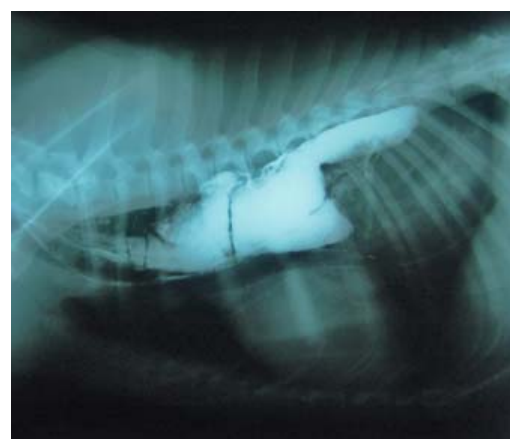(1A)



(1B)



(1C)



(2)

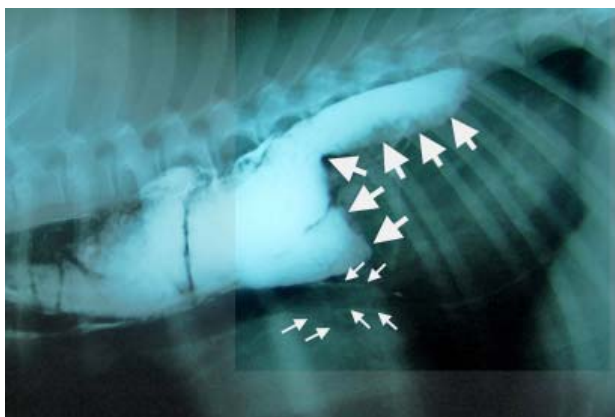
Figure 1. Right lateral (A, B) and ventrodorsal (C) thoracic plain radiographs.

Figure 2. Right lateral thoracic radiograph taken immediately after barium sulfate swallow.

Give your diagnosis and turn to the next page.

Radiographic findings

Plain lateral radiograph of the cranial thoracic portion (Figure 1A) revealed dilation of an esophagus resulting ventral displacement of the thoracic trachea and cranial heart base. A large soft tissue-like mass in the mid-caudodorsal thoracic cavity was presented in the plain lateral and ventrodorsal views of the caudal thoracic radiographs (Figures 1B and 1C). Absence of barium



sulfate in the stomach in the contrast esophagogram (Figure 2) indicate an obstruction in the caudal esophagus. Small amount of barium sulfate could however be detected in the proximal part of caudal bronchi (Figures 2 and 3).

Radiographic diagnosis

Gastroesophageal intussusception (GEI)

Figure 3. Majority of barium sulfate was accumulated in front of caudal esophagus caused by GEI (large arrows) The radiopaque lines (small arrows) presented in the proximal portion of the bronchial walls was from barium sulfate aspiration during esophagography.

Discussion

Gastroesophageal intussusceptions (GEI) is a retrograde invagination of the stomach into the caudal part of the esophagus that was often reported in young German Shepherd dogs. Dogs with acute clinical signs are usually presented with severe respiratory compromise, resulting from compression of caudal lung lobes, while those with chronic signs presented with chronic regurgitation and vomiting.

GEI can be diagnosed on plain radiographs which reveal an enlargement of esophagus seen as a large oval-shaped filling defect in thoracic radiographs together with a cranial displacement of the stomach in abdominal

radiographs. Contrast esophagography is a useful diagnostic technique but contrast aspiration can easily occur due to swallowing difficulty. Esophagoscopy can also be used to differentiate GEI from esophageal foreign body and soft tissue mass in caudal esophagus.

References

- Applewhite, A.A., Cornell, K.K. and Selcer, B.A. 2002. Diagnosis and treatment of intussusceptions in dogs. *Comp. Cont. Edu. Pract. Vet.* 24(2): 110-127.
- Farrow, C.S. 2003. Stomach disorders. In: *Veterinary Diagnosis Imaging the Dog and Cat*. 1st ed. C.S. Farrow (ed.). St. Louis, Missouri: Mosby. 594-613.