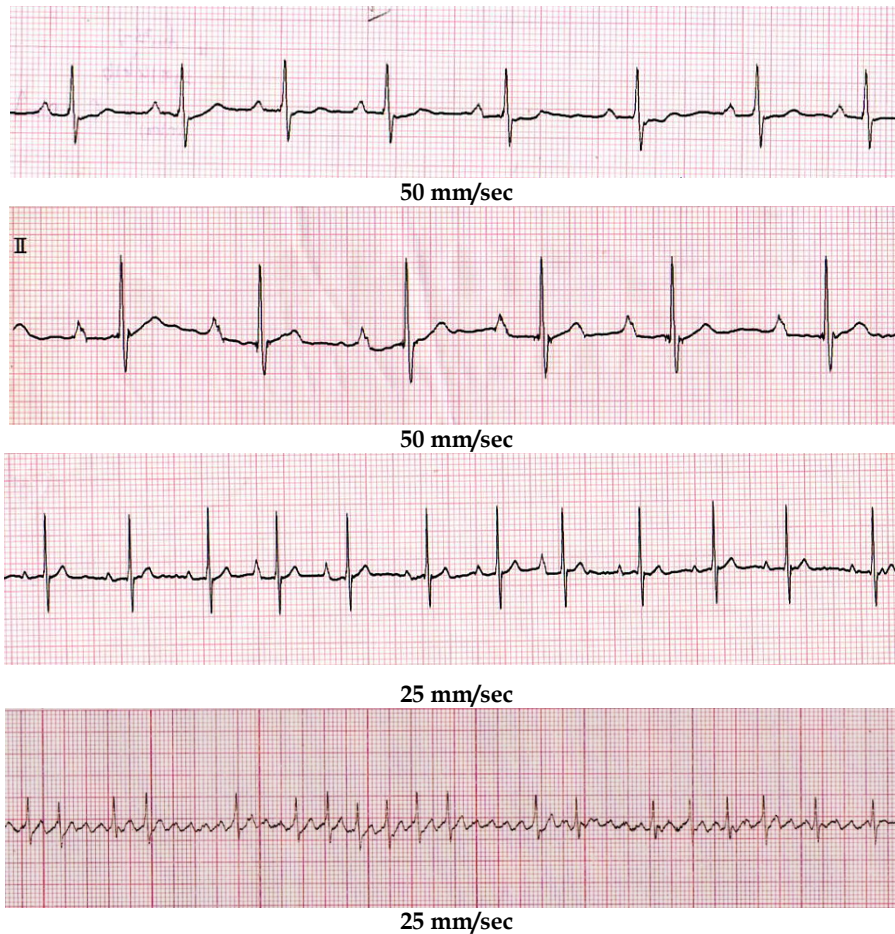


ECG Quiz

Chollada Buranakarl^{1*} Winai Chansaisakorn²



History

A 34 kg, thirteen year-old, male, castrated Dalmatian dog was presented at the Small Animal Hospital, Faculty of Veterinary Science, Chulalongkorn University with a history of exercise intolerance, coughing and 4-minute syncope. Physical examination showed normal hydration status and pink mucus membrane. Subcutaneous edema at the submandibular and cervical areas was presented. The electrocardiography was performed as in tracing I. Thoracic radiograph showed right heart enlargement, distended pulmonary arteries and mild pleural effusion of both thorax with interstitial lung pattern. Echocardiogram revealed right heart enlargement with tricuspid regurgitation. The leukocytosis with white cell count of 25,200 and an albumin of 3.0 gm/dl were found with normal liver and kidney functions. Digoxin (0.25 mg/day), enalapril, furosemide and antibiotic were prescribed. Three weeks later, the dog had ascites and subcutaneous edema on both hindlimbs. The amiloride and

hydrochlorothiazide were added and dose of digoxin was increased by double (0.5 mg/day). Clinical signs were improved with less fluid accumulation inside the abdomen. The medications were continued for 9 months and then the ECG was repeated (tracing II). Blood collection was performed; plasma digoxin level was 3.32 ng/ml. The dose of digoxin was reduced to 0.375 mg/day. Digoxin level was re-evaluated to be 2.4 ng/ml while ECG was also repeated (tracing III). The dose of digoxin was reduced to 0.25 mg/kg while subcutaneous edema and ascites were still remained. Digoxin was replaced by pimobendan although the dog's clinical signs were unstable. Thoracic radiograph showed pleural effusion and ascites. The echocardiography showed an enlargement of both right atrium and ventricle with a small left ventricular chamber. Since pleural effusion was later observed, thoracocentesis was performed on both sides while the dog had stayed in the ICU. The ECG was repeated and shown in tracing IV at one hour before death.

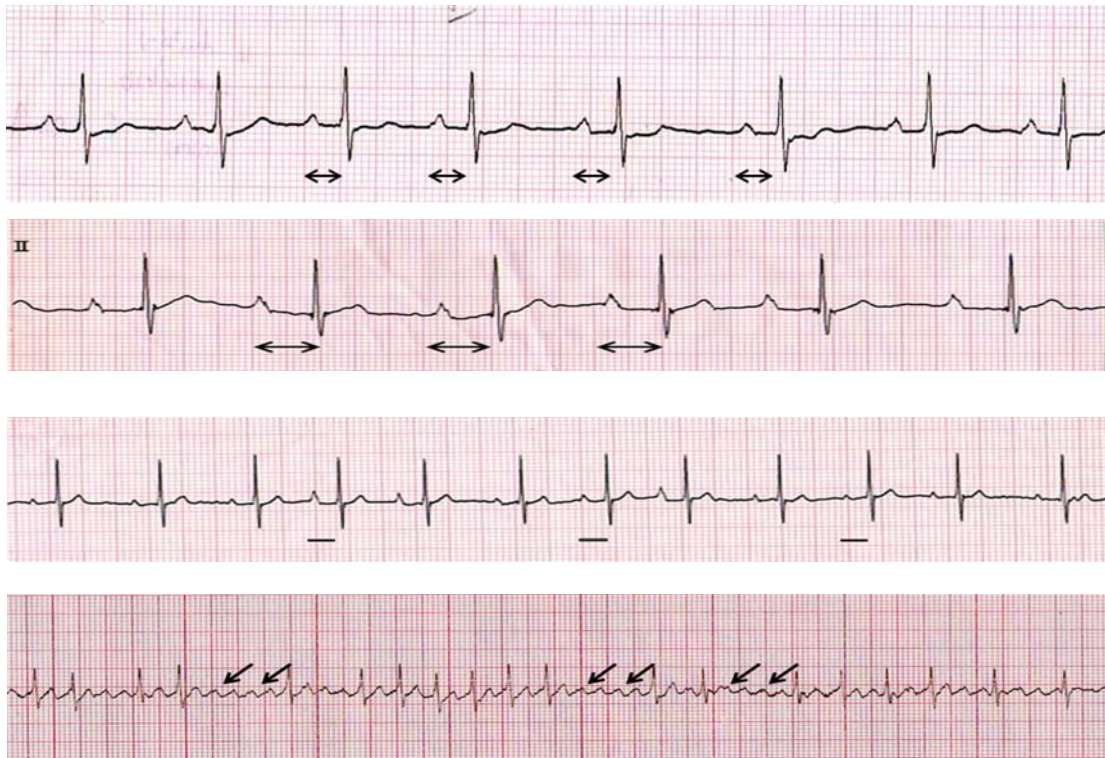
Please answer before turning to the next page.

Department of Physiology, ²Small Animal Hospital, Faculty of Veterinary Science, Chulalongkorn University

*Corresponding author

Interpretation

- Tracing I - Sinus arrhythmia
 Tracing II - Sinus arrhythmia with prolonged PR interval
 Tracing III - Respiratory sinus arrhythmia
 Tracing IV - Supraventricular arrhythmia with atrial flutter



The first strip (tracing I) showed normal sinus arrhythmia with a heart rate of 155 beats/minute. The shape of P-QRS-T complexes was normal. The PR-interval (arrows) was lasted by approximately 0.10 seconds which was within the reference range (< 0.16 seconds). Digoxin is the positive inotropic drug which is commonly prescribed in animals with congestive heart failure. The mechanism of this drug is the Na/K-ATPase inhibitor resulting in an alteration of Na-Ca exchanger and subsequently increased intracellular calcium ion concentration. The combined inotropic-bradycardic action of digoxin is unique when compared to other sympathomimetic drugs which tend to cause tachycardia. Digoxin activates parasympathetic system causing sinus slowing and atrio-ventricular nodal inhibition. Digoxin was given to this dog until the serum digoxin level reached the upper limit (normal range was between 1.0-2.5 ng/dl). Thus, digoxin overdosage may overcome. When the level of digoxin is high along with an increase in intracellular calcium content (calcium overload), the ECG waveform begins to change starting with the slow atrio-ventricular conduction as shown in ECG tracing II. The PR-interval became prolonged (0.20 seconds, arrows). The heart rate decreased to 120 beats/minute. Prolonged PR interval may not cause any changes in blood flow during normal cardiac cycle. However, digoxin toxicity which produces bradycardia in some cases may be more harmful and accompanying with other clinical abnormalities such as vomiting or diarrhea etc. The decrease in a dosage

of digoxin in this case caused digoxin level fell to 2.4 ng/ml and shortened the PR-interval to the normal range (0.16 seconds, solid line in tracing III). However, since the dog had severe congestive heart failure and also developed refractory edema, double diuretics were prescribed. The uncompensated heart failure due to limitation of using digitalis glycoside makes the pimobendan to be a drug of choice. Pimobendan is another group of drug that stimulates cardiac contractility. Pimobendan is a calcium sensitizer with positive inotropic action and vasodilator effects. It is also a selective inhibitor of phosphodiesterase III (PDE3). In dog, pimobendan has been widely used to treat congestive heart failure especially caused by mitral valve regurgitation. Since this dog had severe heart failure with poor cardiac output, he was transferred to the intensive care unit a week later. The ECG which was recorded on the last day showed atrial flutter with supraventricular arrhythmia (tracing IV). Atrial flutter was recognized when the P-waves cannot be seen as a single waveform but showed the saw-tooth like pattern (arrows). The atrial flutter with ventricular myocardial stretching will reduce venous return causing poor contractility and cardiac output which compromises a terminal stage of heart failure.