

Ophthalmology Snapshot

Nalinee Tuntivanich

History

A seven-month old, male exotic short hair cat was presented at the Ophthalmology Clinic, Small Animal Teaching Hospital, Faculty of Veterinary Science, Chulalongkorn University with impaired vision. The owner had had this cat since the cat was 4 months of age. At that time, that cat was in poor health condition. After he had recovered from his illness, the

owner noticed that the cat was reluctant to move around the house; particularly at night.

Ophthalmic examination revealed positive menace responses, as well as dazzle reflexes. Abnormalities of ocular adnexa were not evident. Schirmer tear test I values were within normal limit while intraocular pressures were slightly below normal.

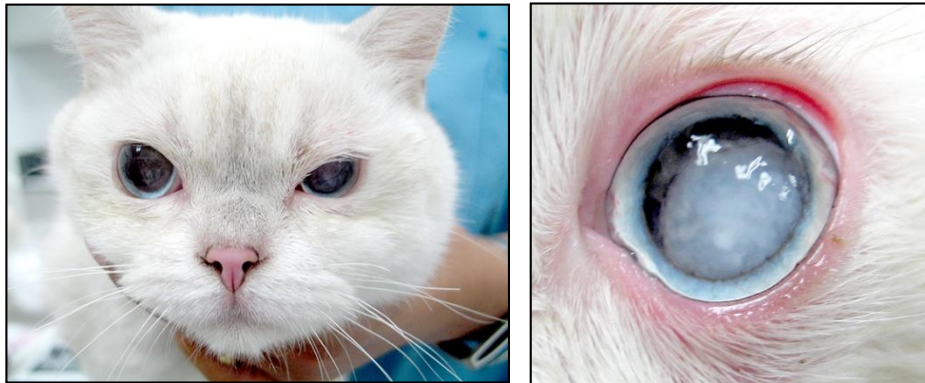


Figure 1 Photographs of the cat representing (A) both eyes from the front view; and (B) the left eye after pupil dilation.
(For better quality of photographs, please visit the TJVM website)

Question

What is your diagnosis?

Please turn to next page for the answer.

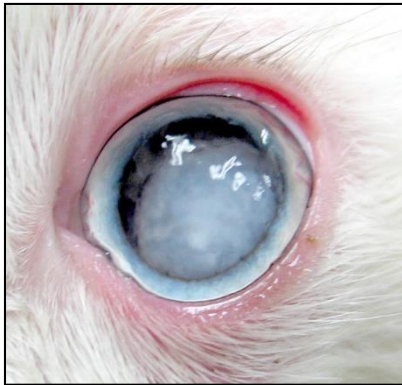
Answer**Cataract**

Figure 2 Photograph of the left eye revealing dense lens with irregularity of the anterior lens capsule. Lens cortex was vertically positioned in the anterior chamber.

Note: Pupil was not fully dilated. Inflammation of the iris was noted.

Comments

Cataract is rare in cats as compared to dogs. However, several causes play some roles in feline cataract. Secondary cataract associated with other ocular disorders is more common in cats than the primary type. The most common cause is inflammation of the anterior uvea.

Feline congenital cataract is not uncommon. Opacification of the lens usually involves the area of the Y suture at the posterior aspect, before progressing to the cortex by time. Breeds predisposed to cataract are Persian, Siamese and domestic short-haired. Cats that have previous history of dehydration that requires intravenous fluid therapy tend to develop cataract at the early age.

Since cats nowadays have longer life span, aged related feline cataract has become more evident. Regarding to a cross-sectional study from 2000 cats in the UK, prevalence of feline cataract was found in cats at an average age of 12.7 ± 3.4 years. Among these senile cats, some had metabolic cataract mainly from diabetes mellitus, of which lens opacity tended to be

located at the posterior lens cortex. In comparison to dogs, mechanism of diabetic cataractogenesis in cats is not considered rapid; unlikely to develop mature cataract.

To be able to examine lens thoroughly, topical mydriatics is required to fully dilate pupils. At advanced stage, leakage of lens protein through lens capsule causes uveitis. Ophthalmic signs of uveitis such as blepharospasm, red eye, miosis and decrease in intraocular pressure are detected. Regular cataract surgery, phacoemulsification, can be performed.

Reference

- Stiles J and Townsend WM 2007. Feline Ophthalmology. In: Veterinary Ophthalmology 4th ed KN Gelatt (ed) Ames: Blackwell Publishing 1130-1133.
- William DL and Heath MF 2006. Prevalence of feline cataract: results of a cross-sectional study of 2000 normal animals, 50 cats with diabetes and one hundred cats following dehydrational crises. Vet Ophthalmol. 9(5): 341-349.