

Acute Toxicity Study of Nanosilver Particles in Tilapia (*Oreochromis niloticus*): Pathological Changes, Particle Bioaccumulation and Metallothionein Protein Expression

Anunya Srinonate¹ Wijit Banlunara² Pattwat Maneewattanapinyo³

Chuchaat Thammacharoen³ Sanong Ekgasit³ Theerayuth Kaewamatawong^{2*}

Abstract

An acute toxicopathological study of silver nanoparticles (AgNPs) was conducted in concentrations of 0, 1, 10 and 100 ppm in adult tilapia (*Oreochromis niloticus*) at days 0, 1, 2, 3 and 4. Mortality, clinical sign, histopathology and immunohistochemistry were observed and evaluated. Calculated LC₅₀ at 24 hr was 53 ppm. The major clinical sign was respiratory distress. Histopathologic lesions were found mainly in gill, kidney, spleen and liver. Severity of the lesions depended on the concentration and exposure time. Superoxide dismutase (SOD) positive immunostaining was found in gill and renal tubular epithelium. Metallothionein (MT) positive staining was observed in renal tubular epithelium. Autometallography (AMG) positive grains were found in gill and gastrointestinal tract. In summary, AgNPs could cause acute toxicity to tilapia in a concentration and exposure time-dependent manner. Oxidative stress may be involved in the pathogenesis of acute AgNPs exposure. Moreover, the expression of MT in tissues responded to AgNPs accumulation.

Keywords: acute toxicity, autometallography, metallothionein, Nile tilapia, silver nanoparticles, superoxide dismutase

¹Department of Pre-Clinic in Veterinary Science, Faculty of Veterinary Sciences, Mahasarakham University, Mahasarakham, Thailand

²Department of Veterinary Pathology, Chulalongkorn University, Bangkok 10330, Thailand

³Sensor Research Unit, Department of Chemistry, Faculty of Science, Chulalongkorn University, Bangkok 10330, Thailand

*Correspondence: theerayuth.K@chula.ac.th

Introduction

Nanosilver particles (AgNPs) have been used extensively in a variety of research and industrial fields. Nowadays, AgNPs can be found in a lot of daily consumer products. Some products containing AgNPs such as detergents and wound dressings are increasingly and broadly used and possibly end up in the environment during waste disposal. Because of their wide and rapid use, contamination of the environment with AgNPs has received a lot of concern. Several studies reported that nanoparticles were exposed to the environment (Hund-Rinke et al., 2006; Moore, 2006; Wiench et al., 2009; Van Hoecke et al., 2011) and had significant effects on aquatic life organisms. Luoma and colleagues (2008) reported that AgNPs in either nanoparticle or ion form could enter and accumulate in living aquatic organisms. Environmental effects of nanoparticles are still questionable and remain unresolved.

Using natural-source-water fish as an environmental biomarker is very useful and may help to assess the risk of toxic substance consumption of human (Oliveira-Ribeiro et al., 2002; Jewett and Duffey, 2007; Raldúa et al., 2007). Tilapia fish (*Oreochromis niloticus*) is a widely distributed fresh water fish that is important in aquaculture (Maclean et al., 2002; Eroglu et al., 2005). Tilapia is one of the most favorite fish in Thai cuisine, resulting in culture making the highest yields from it and total values of production more than all freshwater fish (Fishery statistic analysis and research group, 2005). Tilapia can directly be exposed to high concentration of toxic substances and chemicals because caged culture involves mostly natural water sources and takes more than 6 months. In case of environmental toxicological studies, tilapia was used as the animal model in many researches because of its tolerance to water pollutants (Atli and Canli, 2003; Cheung et al., 2004; Cheung et al., 2005).

To study the distribution and accumulation of AgNPs in fish tissue, autometallography (AMG) was performed in this study. AMG is a potent histochemical staining that is used to determine heavy metals accumulation in the cells of fish and other species (Loumbourdis and Danscher, 2004; Alvarado et al., 2006). Several toxicity studies used the AMG technique to detect small amount of heavy metal in the cells of various kinds of animals (Woshiner et al., 2002; Danscher and Stoltenberg, 2006). In our previous study, we used AMG histochemical techniques to demonstrate the *in situ* deposition and distribution of AgNPs in the lungs and hilar lymph nodes of mice (Kaewamatawong et al., 2013).

To protect from oxidative harmful reaction, cells have developed a free-radical scavenging process by various kinds of antioxidant enzymes including superoxide dismutase, catalase and glutathione peroxidase. Superoxide dismutases are primary antioxidant enzymes that scavenge ROS by catalyzing the dismutation reaction of the superoxide anion to hydrogen peroxide. Several *in vitro* nanotoxicity studies revealed the association between the free-radical generation and SOD scavenging activity. Dey and colleagues (2008) demonstrated the increase in

manganese superoxide dismutase (MnSOD) protein levels induced by nanosized alumina in mouse skin epithelial cells. A decrease in SOD and glutathione (GSH) level that is associated with generation of peroxy radicals after AgNPs exposure to human fibrosarcoma (HT-1080) and human skin/carcinoma (A431) cells was reported (Arora et al., 2008). In this study, we tried to demonstrate the expression of SOD that may relate to AgNPs exposure in fish tissues.

Metallothionein (MT) is a low molecular weight (6,000-7,000) and cysteine-rich protein with high affinity for divalent cations such as Ag^{2+} , Cd^{2+} , Cu^{2+} , Zn^{2+} and Hg^{2+} (Lau et al., 2001; Wu et al., 2008; Gao et al., 2009). Although the role of MT is still unclear, it is believed that MT is involved in regulation of essential metals such as Zn and detoxification of non-essential metal ions such as Cd, Pb and Hg (Chan, 1994; Cheung et al., 2004). Several researches reported that heavy metals could induce MT gene and protein in many fish species and could reduce potential toxicity of heavy metal residues and therefore it can be used as a biomarker for heavy metal contamination in polluted water (Cheung et al., 2005; Quirós et al., 2007). The expression of MT in tissues responding to heavy metal exposure has been reported in various kinds of organisms and animals (Alvarado et al., 2006; Kaewamatawong et al., 2012). The protective role of MT from silver nanomaterials is still unknown. There is no report of MT expression *in vivo* study caused by exposure to AgNPs in aquatic organisms. At present, there is little information about AgNPs toxicity especially in aquatic environments in terms of pathological studies. Therefore, the purpose of this study was to investigate the acute toxicopathological changes of AgNPs on Nile tilapia. Pathogenesis and protective response were also elucidated.

Materials and Methods

Preparation and characterization of AgNPs: High concentration of colloidal AgNPs solution was synthesized via a chemical reduction process according to the method previously described (Manee Wattanapinyo et al., 2011). Briefly, a 0.094 M aqueous solution of silver nitrate (AgNO_3 ; Merck) was prepared with soluble starch (Merck) as a stabilizer. An aqueous solution of 0.07 M sodium borohydride (NaBH_4 ; Merck) reducing agent with the soluble starch solution as a solvent was sequentially prepared. By mixing both solutions, the AgNO_3 solution was added dropwise to the NaBH_4 solution under a vigorous stir. A dark cloud appeared and turned to yellowish brown within a few seconds. When all reactants were completely added, the solution turned dark brown. Purification of the AgNPs was precipitated by using centrifugation. Then, the precipitates of AgNPs were washed three times with DI water and adjusted to the same volume before dilution. The synthetic AgNPs were very pure (99.96%) and the Ag ions were very low in concentration (less than 0.04%). The AgNPs solutions were diluted with distilled water to obtain various concentrations of AgNPs prior to use. The particle morphology of AgNPs was observed using JEOL JEM-2010 analytical transmission electron microscope. The AgNPs had a spherical configuration

with a primary particle diameter of 10-20 nm. The plasmon extinction of AgNPs measured by Ocean Optics Portable UV-Visible spectrometer (USB 4000-UV-VIS detector) showed that the size distribution of AgNPs was narrow.

Experimental animals: Tilapias (*Oreochromis niloticus*), 25-50 g in weight and 9-12 cm in length, were obtained from Veterinary Medical Aquatic Research Center (VMARC), Chulalongkorn University. They were maintained in 62.5-liter glass aquaria filled with 50-liter tap water, where the experiment was conducted. The animals were acclimated to laboratory condition for one week before the experiment. Air pump with aquarium foam sponge filter was used for the aeration system. Water temperature, pH and dissolved oxygen (DO) were measured daily during the experiment. The average temperature was $27.14 \pm 0.39^\circ\text{C}$, pH was 7.30 ± 0.11 and DO was 9.56 ± 0.60 mg/l. All fish were fed twice daily on commercial food ad libitum throughout the experimental period. The tap water in the aquaria was changed every two days. All animal experiments were proved by the ethics committee of Chulalongkorn University Animal Care and Use Committee (CU-ACUC).

Experimental design: The tilapias were randomly divided into 1 control and 3 exposure groups of 15 animals each. The tilapias were raised in the aquaria which contained 1, 10, and 100 ppm AgNPs, respectively. One container of 15 tilapias was kept as an unexposed control group in the same condition. The animals in each group were sacrificed at 0, 1, 2, 3 and 4 days after exposure.

Sample collection: The fish were euthanized by rapid cooling with ice and necropsy was performed. After gross examination, the kidney, liver, spleen, gill, gut (stomach and intestine), brain, and muscle tissues were collected and preserved in 10% neutral buffered formalin. The tissues were routinely histologically processed. After paraffin embedding, 4 μm sections were cut and stained with hematoxylin and eosin (H&E) for histopathologic evaluation, autometallography staining and immunohistochemistry.

Immunohistochemistry: The tissue samples from various organs of the control and treated tilapias were immunostained to detect antioxidant enzymes (Cu/Zn SOD) and MT. After deparaffinization, the sections were treated with citrate buffer solution (pH= 5.4-6.0) for 20 min at 121°C by autoclave and microwave heat at 700 W for 5 min in the process of antigen retrieval. The sections were incubated with 3% H_2O_2 in methanol to quench endogenous peroxidase for 30 min at room temperature. The slides were then blocked with 10% normal goat serum (for detection of Cu/Zn SOD) for 5 min in microwave oven 250 w or 1% bovine serum albumin (for detection of MT) for 30 min at 37°C . Thereafter, the sample and positive control sections were incubated overnight at 4°C with primary antibodies (polyclonal rabbit anti-Cu-Zn SOD Ab, Stressgen Bioreagents, Victoria, Canada, 1:200 dilution; and monoclonal mouse anti-MT Ab, Dako®, Glostrup,

1:50 dilution). On the other hand, the negative control sections were incubated with phosphate buffered saline. The biotinylated anti-mouse IgG antibody and EnVision polymer (Dako^{REAL}™ EnVision™ detection system, Dako®, Denmark) were reacted to sections as a secondary antibody. Brown staining with the substrate 3,3'-diaminobenzidine tetrahydrochloride (DAB) was determined as a positive result and the sections were counterstained with Mayer's hematoxylin for 30 sec.

Autometallography: The tissue sections from various organs were performed for detecting intracellular mercury deposition. After deparaffinization, other metal residues were eliminated by incubating the sections with 1% KCN for 2 h and rinsed well with tap water and distilled water (DW). The sections were incubated with physical developer (50% Arabic gum, 50% citrate buffer, 5.6% hydroquinone, and 17% AgNO_3) to silver amplification for 1 h in an automatic shaker at 26°C and then with 10% sodium thiosulfate and Farmer's solution (20% sodium thiosulfate and 7.5% potassium ferric cyanide) to eliminate silver residues. Thereafter, the sections were rinsed in tap water and counterstained with Mayer's hematoxylin. Positive reactions resulted in yellow-brown to black silver grains in the cells. The sections were observed under a light microscope to identify cell types and locations of silver grains deposition. Scores were given by positive staining degrees and intensity of silver grains in each cell.

Statistical analysis: Data in the graphs are presented as percentage. The data were analyzed using analysis of variance (ANOVA). Values of $P < 0.05$ were considered as the level statistical significance. All statistical analyses were carried out using the SPSS statistical software for Windows, version 12.

Results

Clinical and macroscopic findings: In the control and 1 ppm AgNPs treated fish, there were no exposure-related clinical signs in any observation times. Tilapias of both 10 and 100 ppm groups showed respiratory distress characterized by swimming to surface of water, rapid opercula movements and dyspnea after a few hours post-exposure. The mortality of tilapias was observed at days 0-4 post-exposure. At day 1, a significant increase in mortality was observed in the 100 ppm AgNPs treated fish (Fig 1). Calculated median lethal concentration (LC_{50}) at 24 hr of AgNPs to the Nile tilapia was 53 ppm ($\mu\text{g}/\text{ml}$).

Grossly, there was no remarkable lesion in the control group in any observation times. In both 10 and 100 ppm AgNPs treated fish, tiny pin-head sized to patchy black brown foci scattered in the gill (Fig 2a) and gastrointestinal tracts throughout the experiment. At days 2-4 post-exposure, the gills from the 10 and 100 ppm AgNPs treated fish showed sloughing and pale in color (Fig 2b). Some fish revealed congested and enlarged spleen, and multifocal pin-point haemorrhages in the liver. The degree of lesions described above in the 100 ppm treated group was more severe than the 10 ppm treated group.

Microscopic findings: Trunk of the kidney from the control fish showed normal appearance with occasional mild congestion. However, the treated fish revealed mild to moderate tubular degeneration and hyaline droplets (Fig 3a). The most severe lesions were observed in the 100 ppm AgNPs exposure group followed by the 10 and 1 ppm groups, respectively, at day 0 post-exposure. The severity of the lesions increased from day 1 until the end of experiment. Increase in the numbers of MMCs in head of kidney and spleen was obviously observed in the experimental groups of 10 and 100 ppm compared to

the control group (Fig 3b). Moderate lesions were observed from day 1 until the end of the experiment. Loss of fat storage hepatocytes was observed in various degrees of the exposure groups. In the 100 ppm AgNPs exposure group, the degree of fat losing hepatocytes was moderate from day 1 until the end of experiment when compared to the control group (Figs 3c, 3d). Mild to moderate loss of fat storage was noted in the 10 ppm group. However, there was no difference in the severity of lesions among the 1 ppm and control groups.

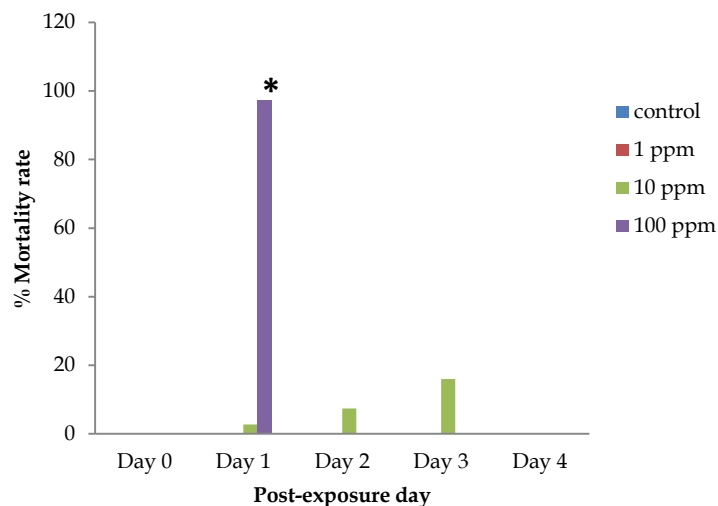


Figure 1 Effects of AgNPs in terms of % mortality at 24 hr. A significant increase in mortality was observed in 100 ppm AgNPs treated tilapia




Figure 2 Fish from 100 ppm AgNPs treated group at 1 day post-exposure showed patchy black brown foci scattered in gill (a; Bold arrow) with sloughing and pale of gill (b; arrowhead).

At day 0 post-exposure, accumulation of free aggregated brown-black AgNPs was found on the gill lamellae and lumen of all treated groups especially the 10 and 100 ppm groups. Mild to moderate sloughing of gill epithelium (Fig 3e) and eosinophil infiltration in gill lamellae (Fig 3f) were also found in the 10 and 100 ppm groups. At days 1-4, shortening and attachment of gill lamellae were noted in the 10 and 100 ppm groups with the accumulation of AgNPs (Fig. 3g). In gastrointestinal organs of the treatment groups, AgNPs accumulation was observed on the mucosal surface and in the lumen throughout the experiment. Moreover, brown-black dots or clumps of AgNPs were also seen in the cytoplasm of melano-macrophages, hepatocytes and gastric epithelial cells.

Cu/Zn Superoxide dismutase (Cu/Zn SOD) expression: The expression of Cu/Zn SOD was not observed in any sample tissues of the control fish (Figs 4a, 4c). In the 10 and 100 ppm treated fish, SOD expression was observed chiefly in the cytoplasm of gill epithelium, mucous cells, iodocytes and renal tubular cells from days 1-4 post-exposure (Fig 4b, 4d).

Metallothionein expression: Moderate intracytoplasmic MT protein expression in the cytoplasm of renal tubular epithelium was observed in the 10 and 100 ppm exposure groups from day 1 until the end of the experiment (Fig 5b). In the control and other exposure groups, MT protein was not detectable in any tissue samples (Fig 5a).

Autometallography: AgNPs deposition, yellow-brown to black positive silver grains, were found aggregating on lamellae and in lumen of the gill (Fig 6a), and gastrointestinal mucosa and lumen (Fig 6b) of the tilapias in the 10 and 100 ppm treated groups. The positive silver grains were also observed occasionally in the cytoplasm of the renal tubular epithelium of the kidneys, hepatocytes, MMCs of the spleen and intestinal epithelium of the experimental groups. Degrees and distribution of positive staining increased depending on the exposure concentration of AgNPs. By contrast, no evidence of positive silver grains was found in any tissues of fish of the control group.

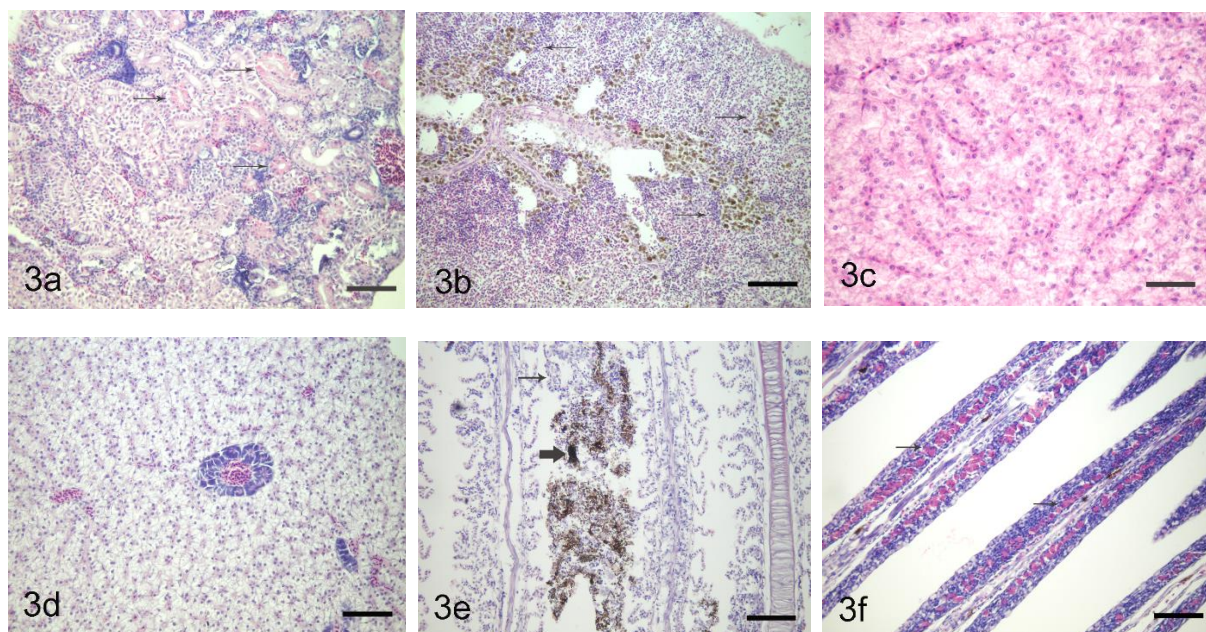


Figure 3 Various organs from various doses of AgNPs treated and control groups at various time points demonstrated a variety of histopathological changes, H&E stain. (a) Tubular degeneration and hyaline droplets in the trunk of the kidney (arrows); 10 ppm treated group at 0 day post-exposure, Bar = 350 μ m. (b) Increased MMCs in spleen (arrows); 1 ppm treated group at 1 day post-exposure, Bar = 250 μ m. (c) Loss of fat storage in hepatocytes of 100 ppm treated group at 0 day post-exposure (Bar = 450 μ m) compared to the control group (d), Bar = 350 μ m. (e) Sloughing of gill epithelium (arrow) with AgNPs accumulation (bold arrow); 100 ppm treated group at 0 day post-exposure, Bar = 350 μ m. (f) Eosinophil infiltration in gill lamellae (arrows); 100 ppm treated group at 0 day post-exposure, Bar = 500 μ m. (g) Shortening and attachment of gill lamellae (bold arrow) with accumulation of AgNPs (arrow); 100 ppm treated group at 2 days post-exposure, Bar = 500 μ m.

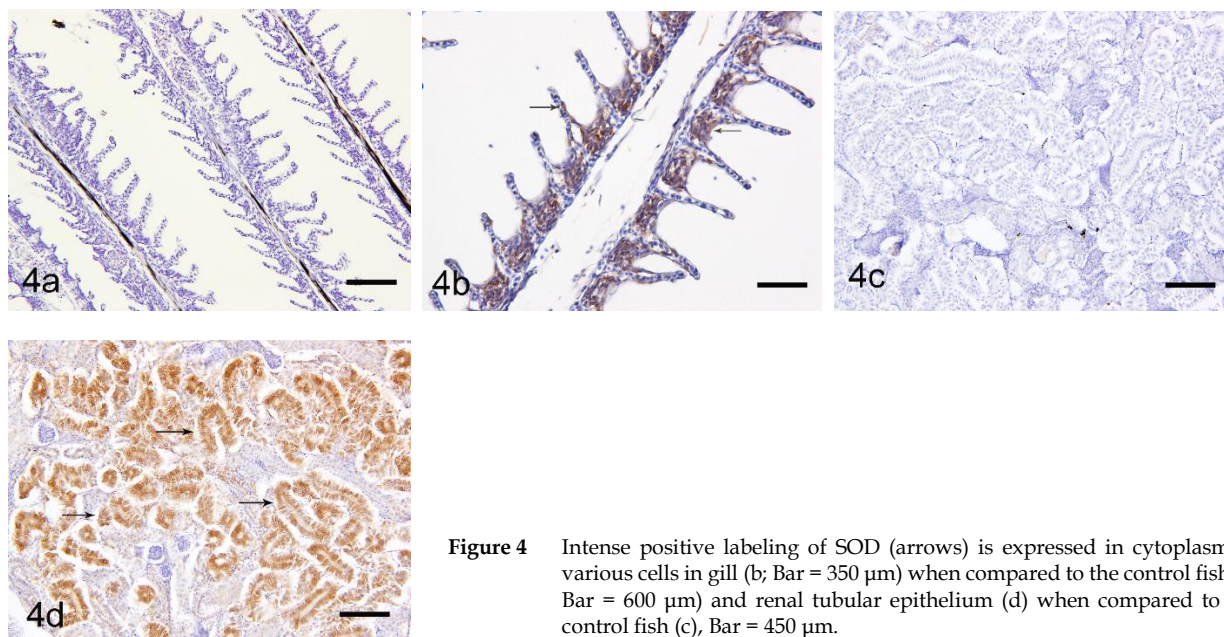


Figure 4 Intense positive labeling of SOD (arrows) is expressed in cytoplasm of various cells in gill (b; Bar = 350 μ m) when compared to the control fish (a; Bar = 600 μ m) and renal tubular epithelium (d) when compared to the control fish (c), Bar = 450 μ m.

Discussion

In the present study, mean mortality rate in the 100 ppm (μ g/l) AgNPs exposure group was 97.2% after the first day of experiment. The calculated 24-hour median lethal concentration (LC_{50-24h}) of AgNPs

in this experiment was estimated at 53 ppm. Comparing the LC_{50-24h} of this study with previous studies developed on commercial AgNPs toxicity in another fish, the value in the present study was rather higher than others (Shahbazzadeh, et al., 2009). The

higher values estimated in this study may be attributed to some differences in standard techniques involving type of the test-organisms and chemical. The fish used in this study were adult tilapias. In contrast, other studies that obtained lower values of LC_{50} used Rainbow Trout (*Oncorhynchus mykiss*) as the test-organisms. Several toxicity studies reported that tilapia is more tolerant than most commonly test-organisms to many substances and chemicals (Bradbury and Coats, 1989; Sarikaya, 2009).

Several studies reported the distribution of nanoparticles in various organs of aquatic organisms. Kashiwada (2006) used water-suspended fluorescent nanoparticles to investigate the distribution of nanoparticles in medaka. Nanoparticles were detected at high levels in the gills and intestine, moderate levels in testis and liver, and low levels in the brain. In our study, the distribution of AgNPs in the organs and tissues of tilapia were studied using

autometallographic technique. Gills and gastrointestinal organs were the critical organs for high accumulation of AgNPs. Low levels of positive AMG staining were observed in the trunk of kidney, spleen and hepatopancreas. These results suggest that AgNPs can distribute throughout the systemic system of aquatic organism. The major translocation pathway to enter the circulation of nanoparticles in fish may contribute via the gill-blood route and/or the intestine-blood route because gill and gastrointestinal organs are principal routes that are directly exposed to and uptake the toxicants from ambient water into the fish body. In the present study, there was no evidence of the distribution of AgNPs to the brain of the treated tilapias. However, several toxicity studies demonstrated the distribution of nanoparticles to the brain in other experimental fish such as medaka and largemouth bass via the blood-brain barrier or olfactory neuron (Kashiwada, 2006; Oberdörster et al., 2004).

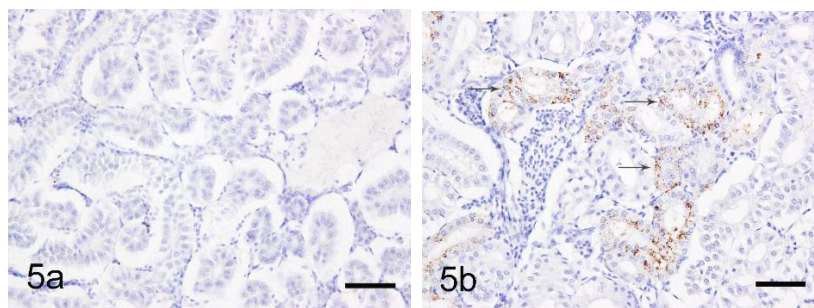


Figure 5 Immunohistochemical localization of MT in renal tubular epithelium of 100 ppm group at 3 days post-exposure, brown positive staining was observed in cytoplasm of tubular epithelium (a, arrows) compared to the control group (b), Bar = 600 µm.

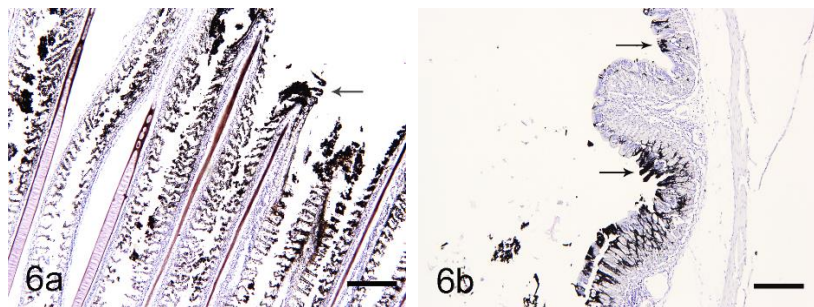


Figure 6 Black positive silver grains (arrows) in gill (a) and intestine (b) of 100 ppm group at 1 day post-exposure were observed on mucosa and in lumen, Bar = 300 µm

Nanoparticles have been reported to cause oxidative stress as a result of generation of reactive oxygen species (ROS) in a number of *in vivo* and *in vitro* studies (Dick et al., 2003; Donaldson and Stone, 2003; Kaewamatawong et al., 2006). An *in vivo* study of nanosilver also revealed the cytotoxicity of particles that are related to the generation of reactive oxygen species (Choi et al., 2010; Miura and Shinohara, 2009). In an aquatic toxicity study, Federici and colleagues (2007) demonstrated that the nanotoxicity of TiO_2 in rainbow trout was related to oxidative stress formation and anti-oxidant protective induction such as glutathione. In our study, we found the results of the positive Cu/Zn SOD immunoreactivity mainly in the cytoplasm of various cells in the gill tissues associated with the AgNPs aggregation. These results indicated that AgNPs might play an important role in producing oxidant stress related to the particle accumulation.

Several laboratory and field studies noted that metallothionein (MT) played an important role in heavy metal homeostasis and detoxification in

animals. An *in vitro* cytotoxicity study of astrocytes exposure to Ag-NPs showed upregulation of MT via activation of metal regulatory transcription factor 1 (MTF-1) (Luther et al., 2012). Certain mechanisms associated with the MT responses to AgNPs exposure remains unclear. Silver (Ag) can directly stimulate the production of MT via initiation of thionien in the cells (Kim et al., 2009). In another mechanism, enhancement of MT induction is associated with their antioxidant role that responses to an increase in oxyradicals (Haq et al., 2003). In the present study, MT immun-expression was detected in the cytoplasm of renal tubular epithelium that was associated with some AgNPs aggregated areas. This study, therefore, suggests that MT might have a protective role to AgNPs in fish at acute stage. The underlying mechanism of the induction of MT caused by exposure to AgNPs should be elucidated.

In conclusion, AgNPs used in our study can cause acute toxicity to adult tilapia in a concentration and exposure time-dependent manner. The systemic

distribution of AgNPs was discovered. Oxidative stress may involve in the pathogenesis of the acute AgNPs exposure. Moreover, the expression of MT in tissues responded to AgNPs accumulation. The AgNPs used in this study were in colloidal form that could easily disperse and flow into aquatic environments, leading to possible adverse effects to aquatic organisms. Therefore, the release of untreated AgNPs waste into the environment should be given special attention to control and restrict for clean environment and good quality of life.

Acknowledgements

This work was supported by funding from Chulalongkorn University-Veterinary Science Research Fund, Faculty of Veterinary Science, Chulalongkorn University 2010.

References

- Alvarado AE, Quesada I, Hylland K and Marigomez SM 2006. Quantitative changes in metallothionein expression in target cell-types in the gills of turbot (*Scophthalmus maximus*) exposed to Cd, Cu, Zn and after a depuration treatment. *Aquat Toxicol* 77: 64-77.
- Arora S, Jain J, Rajwade JM and Paknikar KM 2008. Cellular responses induced by silver nanoparticles: In vitro studies. *Toxicol Lett* 179: 93-100.
- Atli G and Canli M 2003. Natural occurrence of metallothionein-like proteins in the liver of fish *Oreochromis niloticus* and effects of cadmium, lead, copper, zinc, and iron exposures on their Profiles. *Bull Environ Contam Toxicol* 70: 619-627.
- Bradbury SP and Coats JR 1989. Comparative toxicology of pyrethroid insecticides. *Rev Environ Contam Toxicol* 108: 133-177.
- Chan KM 1995. Metallothionein: Potential biomarker for monitoring heavy metal pollution in fish around Hong Kong. *Marine Pollut Bull* 31: 411-415.
- Cheung APL, Lam THJ and Chan KM 2004. Regulation of tilapia metallothionein gene expression by heavy metal ions. *Marine Environ Res* 58: 389-394.
- Cheung APL, Lam VKL and Chan KM 2005. Tilapia metallothionein genes: PCR cloning and gene expression studies. *Biochemica et Biophysica Acta* 1731: 191-201.
- Choi JE, Kim S, Ahn JH, Youn P, Kang JS, Park K, Yi J and Ryu DY 2010. Induction of oxidative stress and apoptosis by silver nanoparticles in the liver of adult zebrafish. *Aquat Toxicol* 100: 151-159.
- Danscher G and Stoltenberg M 2006. Autometallography (AMG) silver enhancement of quantum dots resulting from (1) Metabolism of toxic metals in animals and humans, (2) In vivo, in vitro and immersion created zinc-sulphur/zinc-selenium nanocrystals, (3) Metal ions liberated from metal implants and particles. *Progr Histochem Cytochem* 41: 57-139.
- Dey S, Bakthavatchalu V, Tseng MT, Wu P, Florence RL, Grulke EA, Yokel RA, Dhar SK, Yang H, Chen Y and Clair DK 2008. Interactions between SIRT1 and AP-1 reveal a mechanistic insight into the growth promoting properties of alumina (Al₂O₃) nanoparticles. *Carcinogenesis* 29: 1920-1929.
- Dick CAJ, Brown DM, Donaldson K and Stone V 2003. The role of free radicals in the toxic and inflammatory effects of four different ultrafine particles types. *Inhal Toxicol* 15:39-52.
- Donaldson K and Stone V 2003. Current hypotheses on the mechanisms of toxicity of ultrafine particles. *Ann Ist Super Sanita* 39: 405-410.
- Eroglu K, Atli G and Canli M 2005. Effects of metal (Cd, Cu, Zn) interactions on the profiles of metallothionein-like proteins in the Nile fish (*Oreochromis niloticus*). *Bull Environ Contam Toxicol* 75: 390-399.
- Federici G, Shaw BJ and Handy R 2007. Toxicity of titanium dioxide nanoparticles to rainbow trout (*Oncorhynchus mykiss*): Gill injury, oxidative stress, and other physiological effects. *Aquat Toxicol* 84: 415-430.
- Fishery Statistic Analysis and Research Group: Fisheries Statistics of Thailand (2005). Fishery Information Technology Center. Department of Fisheries, Bangkok. 1-150 pp.
- Gao D, Wang GT, Chen XT and Nie P 2009. Metallothionein-2 gene from the mandarin fish *Siniperca chuatsi*: cDNA cloning, tissue expression, and immunohistochemical localization. *Comp Biochem Physiol* 149: 18-25.
- Haq F, Mahoney M and Koropatnick J 2003. Signaling events for metallothionein induction. *Mutat Res* 533: 211-226.
- Hund-Rinke K and Simon M 2006. Ecotoxic effect of photocatalytic active nanoparticles (TiO₂) on algae and daphnids. *Environ Sci Poll Res* 13: 225-232.
- Jewett C and Duffy LK 2007. Mercury in fishes of Alaska, with emphasis on subsistence species. *Sci Total Environ* 387: 3-27.
- Kaewamatawong T, Shimada A, Okajima M, Inoue H, Morita T, Inoue K and Takano H 2006. Acute and subacute pulmonary toxicity of low dose of ultrafine colloidal silica particles in mice after intratracheal instillation. *Toxicol Pathol* 34: 958-965.
- Kaewamatawong T, Rattanapinyopituk K, Ponpornpisit A, Pirarat N, Ruangwiset S and Rungsipat A 2012. Short-term exposure of Nile tilapia (*Oreochromis niloticus*) to mercury: Histopathological changes, mercury bioaccumulation, and protective role of metallothioneins in different exposure routes. *Toxicol Pathol* 41 (3): 470-479.
- Kaewamatawong T, Banlunara W, Maneewattanapinyo P, Thammacharoen C and Ekgasit S 2013. Acute pulmonary toxicity caused by single intratracheal instillation of various doses of colloidal silver nanoparticles in mice: Pathological changes, particle bioaccumulation and metallothionein protein expression. *Thai J Vet Med* 43(3): 375-382.
- Kashiwada S 2006. Distribution of nanoparticles in the See-through medaka (*Oryzias latipes*). *Environ Health Perspect* 114 (11): 1697-1702.

- Kim S, Choi JE, Choi J, Chung K, Park K, Yi J and Ryu D 2009. Oxidative stress- dependent toxicity of silver nanoparticles in human hepatoma cells. *Toxicol Vitro* 23: 1076-1084.
- Lau JC, Jackson-Boeters L, Daley TD, Wyscoki GP and Cherian MG 2001. Metallothionein in human gingival amalgam tattoos. *Arch. Oral Bio* 46: 1015-1020.
- Loumbourdis NS and Danscher G 2004. Autometallography tracing of mercury in frog liver. *Environ Pollut* 129(2): 299-304.
- Luoma SN 2008. Silver nanotechnologies and the environment: Old Problems or New Challenges? Project on emerging nanotechnologies. Available: http://nanotechproject.org/process/assets/files/7036/nano_pen_15_final.pdf. Accessed June 15, 2013.
- Luther EM, Schmidt MM, Diendorf J, Eppele M and Dringen R 2012. Upregulation of metallothioneins after exposure of cultured primary astrocytes to silver nanoparticles. *Neurochem Res* 37: 1639-1648.
- Maclean N, Rahman MA, Sohm F, Hwang G, Iyengar A, Ayad H, Smith A and Farahmand H 2002. Transgenic tilapia and the tilapia genome. *Gene* 295: 265-277.
- Maneewattanapinyo P, Banlunara W, Thammacharoen C, Ekgasit S and Kaewamatawong T 2011. An evaluation of acute toxicity of colloidal silver nanoparticles. *J Vet Med Sci* 73: 1417-1423.
- Miura N and Shinohara Y 2009. Cytotoxic effect and apoptosis induction by silver nanoparticles in hela Cells. *Biochem Biophys Res Commun* 390: 733-737.
- Moore MN 2006. Do nanopartocles present ecotoxicological risks for the health of the aquatic environment? *Environ Int* 32: 967-976.
- Oberdörster E 2004. Manufactured nanomaterials (Fullerenes, C60) induce oxidative stress in the brain of juvenile Largemouth bass. *Environ Health Perspect* 112: 1058-1062.
- Oliveira-Ribeiro C, Belger L, Pelletier E and Rouleau C 2002. Histopathological evidence of inorganic mercury and methyl mercury toxicity in the Arctic charr (*Salvelinus alpinus*). *Environ Res* 90: 217-225.
- Quirós L, Piña B, Solé M, Blasco J, López MÁ, Riva MC, Barceló D and Raldúa D 2007. Environmental monitoring by gene expression biomarkers in *Barbus graellsii*: Laboratory and field studies. *Chemosphere* 67: 1144-1154.
- Raldúa D, Díez S, Bayona JM and Barceló D 2007. Mercury levels and liver pathology in feral fish living in the vicinity of a mercury cell Chlor-alkali factory. *Chemosphere*, 66: 1217-1225.
- Sankaya R 2009. Investigation of acute toxicity of alpha-cypermethrin on adult Nile tilapia (*Oreochromis niloticus* L.). *Turkish J Fish Aqua Sci* 9: 85- 89.
- Shahbazzadeh D, Ahari H, Rahimi M, Dastmalchi F, Soltani M, Fotovat M, Rahmanny J and Khorasani N 2009. The effects of nanosilver (Nanocid®) on survival percentage of rainbow trout (*Oncorhynchus mykiss*). *Pakistan J Nutr* 8 (8): 1178-1179.
- Van Hoecke K, De Schamphelaere KAC, Van der Meeren PSG and Janssen CR 2011. Aggregation and ecotoxicity of CeO₂ nanoparticles in synthetic and natural waters with variable pH, organic matter concentration and ionic strength. *Environ Poll* 159: 970-976.
- Wiensch K, Wohlleben W, Hisgen V, Radke K, Salinas E, Zok S and Landsiedel R 2009. Acute and chronic effects of nano- and non-nano-scale TiO₂ and ZnO particles on mobility and reproduction of the freshwater invertebrate *Daphnia magna*. *Chemosphere* 76: 1356-1365.
- Woshiner VM, O'Hara TM, Eurell JA, Wallig MA, , Bratton GR, , Suydam RS and Beasley VR 2002. Distribution of inorganic mercury in liver and kidney of Beluga and Bowhead whales through autometallographic development of light microscope tissue sections. *Toxicol Pathol* 30: 209-215.
- Wu S, Weng C, Hwang J, Huang C and Hwang P 2008. Metallothionein induction in early larval stages of tilapia (*Oreochromis mossambicus*). *Physio Biochem Zool* 73(5): 531-537.

บทคัดย่อ

การศึกษาความเป็นพิษทางด้านพยาธิวิทยา การสะสมของอนุภาค และการตอบสนองของโปรตีน

เมทัลโลโธอินินในปลานิล (*Oreochromis niloticus*) ที่สัมผัสอนุภาคนาโนแร่เงิน

ในระยะเฉียบพลัน

อณัญญา สีนอนเตร¹ วิจิตร บรรณาร¹ ภัทวัฒน์ มณีวัฒนภิญโญ³ ชูชาติ ธรรมเจริญ³
 สอนง เอกสิทธิ์³ วีระยุทธ แก้วอมตวงศ์*

เพื่อศึกษาความเป็นพิษพยาธิวิทยาของอนุภาคนาโนแร่เงินในปลานิล (*Oreochromis niloticus*) ปลานิลโตเต็มวัยได้รับการสัมผัสกับอนุภาคนาโนแร่เงินขนาด 0 1 10 และ 100 พีพีเอ็ม ในวันที่ 0 1 2 3 และ 4 ของการทดลอง โดยในแต่ละวันจะทำการเก็บข้อมูลอัตราการตาย อาการที่สัตว์แสดงออก รวมทั้งทำการการุณยฆาตและทำการเก็บตัวอย่างชิ้นเนื้อเพื่อศึกษาทางพยาธิวิทยา ย้อมอโตเมทัลโลกราฟี และย้อมอิมมูโนฮิสโตเคมี จากผลการศึกษาพบว่าความเข้มข้นของอนุภาคนาโนแร่เงินซึ่งทำให้สัตว์ทดลองตายไปเป็นครึ่งหนึ่ง (LC₅₀) มีค่าเท่ากับ 53 พีพีเอ็ม จากการสังเกตอาการพบการหายใจลำบากเป็นอาการหลักในปลานิลที่ได้สัมผัสอนุภาคนาโนแร่เงิน ผลทางพยาธิวิทยาพบรอยโรคที่เด่นชัดปรากฏในเหงือก ไต และตับของปลาที่ได้สัมผัสสาร โดยความรุนแรงของรอยโรคแปรผันตามความเข้มข้นของสารที่ปลาได้รับ ผลจากการย้อมด้วยอิมมูโนฮิสโตเคมีของซูปเปอร์ออกไซด์ดิสมิวเตสพบผลบวกในเซลล์ที่บริเวณเหงือกและเยื่อหลุดไตฝอยของปลาในกลุ่มที่สัมผัสสาร ส่วนผลของการแสดงออกของโปรตีนเมทัลโลโธอินินพบการติดสีบริเวณเซลล์เยื่อของหลอดไตฝอยไตในปลากลุ่มที่สัมผัสสาร การย้อมอโตเมทัลโลกราฟีเพื่อศึกษาการสะสมของอนุภาคนาโนแร่เงินพบผลบวกในเซลล์ในบริเวณเหงือกและระบบทางเดินอาหาร จากผลการทดลองทั้งหมดสรุปได้ว่า การสัมผัสอนุภาคนาโนแร่เงินของปลานิลสามารถทำให้เกิดความพิษในระยะเฉียบพลันได้ โดยความรุนแรงขึ้นกับระดับความเข้มข้นและระยะเวลาที่สัมผัส จากการศึกษาพยาธิกำเนิดพบว่าอนุมูลอิสระมีความเกี่ยวข้องในความเป็นพิษที่เกิดขึ้น และพบว่าการปรากฏของโปรตีนเมทัลโลโธอินินมีความเกี่ยวข้องกับการสะสมของอนุภาคนาโนแร่เงินในเนื้อเยื่อของปลานิล

คำสำคัญ: ความเป็นพิษระยะเฉียบพลัน อโตเมทัลโลกราฟี เมทัลโลโธอินิน ปลานิล อนุภาคนาโนแร่เงิน ซูปเปอร์ออกไซด์ดิสมิวเตส

¹คณะสัตวแพทยศาสตร์ มหาวิทยาลัยมหาสารคาม อ.เมือง จ. มหาสารคาม 44000

²ภาควิชาพยาธิวิทยา คณะสัตวแพทยศาสตร์ จุฬาลงกรณ์มหาวิทยาลัย ปทุมวัน กรุงเทพฯ 10330

³หน่วยปฏิบัติการวิจัยอุปกรณ์รับรู้ภาควิชาเคมีคณะวิทยาศาสตร์จุฬาลงกรณ์มหาวิทยาลัย ปทุมวัน กรุงเทพฯ 10330

*ผู้รับผิดชอบบทความ E-mail: theerayuth.K@chula.ac.th