

Impaired cytokines gene expression by diazinon and its relation with blood chemistry and oxidative stress biomarkers in Nile Tilapia (*Oreochromis niloticus*)

Mahmoud El Sebaei^{1,2} Mohammad Shathele³ Sabry Mohamed El-Bahr^{1,4*}

Abstract

Diazinon (DZN) is a promising broad-spectrum organophosphorus insecticide. There is no evidence to support the hypothesis that DZN alters cytokine gene expression and that these modifications have an immediate impact on the histopathology, blood chemistry and oxidative stress in Nile tilapia (*Oreochromis niloticus*). Therefore, 225 fish were divided into one control group and four treatment groups (45 fish/group; 3 replicates/group; 15 fish/replicate). Fish in the control group were supplied with water free of DZN. Fish in the treatment groups (T1-T4) were intoxicated with DZN at 0.28 mg/L for 1, 2, 3 and 4 weeks, respectively. Activities of AST and ALT and the concentrations of uric acid, creatinine and MDA increased significantly in the serum of DZN treated fish compared to the control. Protein parameters, GSH concentration and activities of antioxidant enzymes decreased significantly in the serum of DZN treated fish. DZN intoxication induced an elevation in MDA concentration and a reduction in GSH concentration and activities of CAT and GPX enzymes in the liver and kidney tissues of DZN treated fish. DZN intoxication induced a significant elevation in gene expression levels of TNF- α , IL-8, IL-1 β accompanied by a significant reduction in IL-10 gene expression levels in the liver and kidney tissues of DZN treated fish. The histopathological changes in DZN intoxicated fish were in the form of necrosis and degeneration of hepatocytes as well as desquamation and vacuolation of renal epithelium. Conclusively, DZN intoxicated Nile Tilapia exhibited oxidative damage, reduced cytokine gene expression and hepatorenal necrosis, which was intensified with the length of fish exposure to DZN.

Keywords: toxicity, fish, TNF- α , interleukins, antioxidant, enzymes

¹Department of Biomedical Sciences, College of Veterinary Medicine, King Faisal University, PO Box 400, Al-Ahsa 31982, Saudi Arabia

²Department of Biochemistry and Chemistry of Nutrition, Faculty of Veterinary Medicine, Mansoura University, Mansoura, 35516, Egypt

³Department of Microbiology, College of Veterinary Medicine, King Faisal University, Al-Ahsa 31982, Saudi Arabia

⁴Department of Biochemistry, Faculty of Veterinary Medicine, Alexandria University, Alexandria, Egypt

*Correspondence: selbahar@kfu.edu.sa, sabryelbahr@hotmail.com (S.M. El-Bahr)

Received May 12, 2022

Accepted September 26, 2022

<https://doi.org/10.14456/tjvm.2022.76>

Introduction

As one of the fastest expanding animal food-producing sectors, aquaculture contributes to global food safety and security. Egyptian aquaculture has expanded and developed significantly in recent years but substantial limits to continued expansion are arising. Pesticide pollution of the aquatic ecology is one of the key restrictions (Soliman and Yacout, 2016). While pesticides serve a vital role in increasing land productivity and food quality for the world's growing population, particularly in developing nations, their presence in agricultural drainage poses a major threat to all aquatic ecosystem components (Abhilash and Singh, 2009). Semi-intensive aquaculture is the most common production method in Egypt (El-Sayed, 2017a, b; Yacout *et al.*, 2016). Agricultural drainage water is the only water source allowed for aquaculture activities under current rules (Law No. 124/1983; El-Sayed, 2017a, b). As a result, pesticide usage for crop enhancement offers a high danger of exposure and bioaccumulation in aquatic creatures, particularly aquaculture fish, potentially exposing humans to accumulated environmental contaminants (Storelli, 2008). The appropriateness of Nile tilapia in aquaculture systems, as well as its marketability and price stability, are regarded to be the most important elements in its global dispersion. The Nile tilapia (*Oreochromis niloticus*) is a significant warm-water aquaculture fish species, particularly for low-income countries/areas and subsidy farmers (Cai and Leung, 2017). Because Egypt is the world's second largest producer of farmed tilapia and many fish are consumed within the country, there is a considerable risk of contaminants like DZN entering the human food chain and interfering with fish health and productivity. Organophosphorus chemicals are a type of insecticides that inhibit the acetylcholine esterase enzyme and are commonly used to replace chlorinated pesticides like organochlorine pesticides because of their bioaccumulative concerns. Diazinon (DZN) is a significant organophosphorus chemical derivative that poses a threat to the veterinary field because to its potential broad-spectrum action against many insects. It is easily swept into surface waters, where it affects a variety of non-target creatures, including fish. DZN's stability in water can last up to 6 months, creating toxic accumulation in aquatic creatures' tissues. Pesticide exposure influences the immune system, and pesticide biological activity alters the innate immune responses (Girón-Pérez *et al.*, 2009). When pesticides are used, reactive oxygen species (ROS) are produced, which cause oxidative stress in the cells or organs involved (Zahran *et al.*, 2018). Superoxide dismutase (SOD), catalase (CAT), glutathione-S-transferase (GST), and reduced glutathione (GSH) are antioxidant enzymes that control the release of reactive oxygen species (ROS) and decrease tissue damage (Kumar *et al.*, 2011; Zahran *et al.*, 2018). Exposure to pesticides and other toxicants alters the immunological response to microorganisms, putting fish at risk of sickness (Li *et al.*, 2013b). Changes in the expression levels of pro-inflammatory cytokines including IL-1, IL-8, and TNF- provide an insight into the processes of specific pollutants' sub-lethal adverse effects (Secombes, 2002).

Recent research has revealed that chemicals in the water that have the ability to promote ROS generation are responsible for physiological dysfunction in aquatic creatures in polluted areas. Excessive ROS formation in response to xenobiotics producing substances overwhelms endogenous detoxification mechanisms, causing cumulative harm to afflicted cells (Livingstone 2001; Oakes *et al.*, 2004). Organophosphates are highly reactive and produce membrane damage by direct oxidation (Galloway and Handy, 2003). Damage generated by oxidative stress owing to various hazardous exposures are recognized by histopathological examination in many organ systems, including the fish's liver and kidneys (Cengiz and Unlu, 2006; El-Sayed and Saad, 2008). Previous research has indicated that DZN (0.28 mg/L) induces an elevation in liver and kidney function, malondialdehyde (MDA) and TNF- α gene expression and a significant decrease in glutathione (GSH), superoxide dismutase (SOD) and IL-10 expression in different tissues of Nile tilapia (*Oreochromis niloticus*; Abdelhamid, 2020). There is no literature on the influence of diazinon (DZN) on cytokine gene expression and its relationship to histopathology, blood chemistry or oxidative stress indicators. Further research concerning the long-term effects of DZN poisoning in Nile tilapia (*Oreochromis niloticus*) is needed. As a result, the goal of this study was to see how DZN poisoning (0.28 mg/L; 1/10 LC50) affected a wide range of biochemical, immunotoxic and pathological changes in Nile tilapia (*Oreochromis niloticus*) over the course of four weeks.

Materials and Methods

Chemicals: Diazinon (DZN) 600 EC (60%; each 1ml contains 600 mg DZN) was diluted with distilled water immediately before use. Other chemicals and buffers were of analytical grade.

Diet preparation: A basal diet was prepared to meet the nutritional needs of Nile tilapia (*Oreochromis niloticus*) and was isonitrogenous (32%) and isocaloric (3000 Kcal DE/kg) (NRC, 2011). The food was made weekly in the form of a water-stable sinking pellet and kept in plastic bags at 4 °C until needed. Table 1 lists the elements in the basic diet.

Fish, experimental design, and exposure: Two hundred and twenty-five healthy Nile tilapia fish (*Oreochromis niloticus*) weighing 61 ± 5.8 g and 11 ± 0.27 cm in total length were used. The experimental and analytical procedures followed the Research Ethical Committee of King Faisal University, Saudi Arabia, (permission # 216071 of GRANT101). Fish were maintained in an indoor system facilitated with freshwater with adequate aeration and internal power filters and the water was completely changed every 3 days. Water parameters were measured daily with SensoDirect 150 (Lovibond, Germany) for adjusting water temperature, pH and dissolved oxygen during the experimental period. The water parameters were maintained according to the requirement of *Oreochromis niloticus* as follows: (Temperature 22 ± 1.2 °C, pH 7.6-7.8, dissolved oxygen 7.05 ± 0.5 mg/L). All studied groups of fish

were fed the basal diet during the whole experimental period at 3% body weight (BW) twice daily (9.00–10.00 and 16.00–17.00 h). The fish were be acclimatized for two weeks before the beginning of the experiment. Then, fish were randomly divided equally into one control and four treatment groups (according to exposure time) in glass aquarium tanks supplied with dechlorinated tap water and aeration (40 x 60 x 30 cm "with about 80L water capacity") 15 Fish/tank). Three

replicates were assigned per group (a total 45 Fish/group). The fish were divided into one control group and four treatment groups (45 fish/group; 3 replicates/group; 15 fish/ replicate). Fish in the control group were supplied with water free of DZN. Fish in the treatment groups (T1-T4) were intoxicated with DZN at 0.28 mg/L (0.1 of DZN 96 h LC50; El-Sherif *et al.*, 2009) for 1, 2, 3 and 4 weeks, respectively.

Table 1 Formulation and chemical composition of the experimental groups (g/kg).

Ingredients (g/kg; dry matter basis)	Percentage (%)
Yellow corn (8.5%)	11.97
Soybean meal (44%)	20.22
Fish meal	20
Wheat bran	40
Corn gluten	1
Gelatin	2
oil	3
Vitamins and minerals and premix**	1
Salt (sodium chloride)	0.5
Dicalcium phosphate	0.1
Methionine	0.21
Chemical composition (%)	
Crude protein	32.15
DE (kcal/kg)	3000

**Vitamin and minerals mixture supplies the following per kilogram of diet: Vitamin A 1200.000 IU; Vitamin D3 200,000 IU; Vitamin E 12,000 mg; Vitamin K3 2400 mg; Vitamin B1 4800 mg; Vitamin B2 4800 mg; Vitamin B6 4000 mg; Vitamin B12 4800 mg; Folic acid 1200 mg; Vitamin C 48,000 mg; Biotin 48 mg; Choline 65,000 mg; Niacin 24,000 mg; Iron 10,000 mg; Cupper 600 mg; Manganese 4000 mg; Zinc 6000 mg; Iodine 20 mg; Cobalt 2 mg; Selenium 20 mg.

Sampling: At the end of each time point, blood samples and tissues (liver and kidneys) were collected from all groups including the control. Fish were collected from each aquarium (n = 10 per group); then anesthetized with tricaine methanesulphonate (MS-222, FINQUEL®, ARGENT) at a dose of 30 mg/L, buffered in sodium bicarbonate (60 mg/L) and euthanized with 200 mg/l of MS- 222 buffered in sodium bicarbonate (400 mg/L). Two blood samples were collected from the caudal blood vessels of every single fish. The first blood sample was collected in EDTA vacutainers.

Analysis of oxidative stress parameters in plasma: ELISA commercial assay kits supplied by Cayman Chemical, Ann Arbor, Michigan, USA were used for detection of all parameters according to the instruction manual. The obtained plasma was used for estimation of the activities of catalase (CAT; Catalogue # 707002) and glutathione S-transferase (GST; catalogue # 703302). In addition, erythrocyte lysates were separated to calculate the reduced glutathione (GSH; Catalogue # 703002) level and glutathione peroxidase (GPx; Catalogue # 703102) activity.

Analysis of serum biochemical and lipid peroxidation parameters: The second blood samples were collected in plain vacutainers for serum collection. The obtained sera were stored frozen at -80 °C until further estimation of aspartate transaminases (AST; catalogue # EP15-500), alanine transaminases (ALT; catalogue # EL07-1000), total proteins (catalogue # EP56-660), albumin (catalogue # EP03-570), globulin and albumin ratio (A/G ratio), creatinine (catalogue # EP33K-660), uric acid (catalogue # EP20-420) by commercial diagnostic kits (United Diagnostic Industry, UDI,

Dammam, Saudi Arabia). Malondialdehyde (MDA; catalogue # 10009055) levels using commercial assay kits supplied by Cayman Chemical, Ann Arbor, Michigan, USA according to the instruction manual. Part of the collected tissues (liver and kidneys) was washed with normal saline and homogenized in cold phosphate buffer saline (PH 7.5).

Analysis of oxidative stress biomarkers in liver and kidney tissues: Tissue homogenates were cold centrifuged for about 15 mins at 3000 rpm and the clear supernatants were carefully collected and stored frozen at -80 °C until further analysis of selected antioxidants and oxidative stress biomarkers (MDA, CAT, GST, and GSH). ELISA commercial assay kits supplied by Cayman Chemical, Ann Arbor, Michigan, USA were used for estimation of MDA (catalogue # 10009055), CAT (Catalogue # 707002), GST (catalogue # 703302) and GSH (Catalogue # 703002) according to the instruction manuals. Other parts of these tissues (liver and kidneys) were incised into small parts, placed in RNA Later® (Qiagen) (0.5 ml reagent per 50 mg of tissue) at 4 °C overnight, and stored frozen at -80 °C until the time of gene expression analysis.

Histopathological analysis of liver and kidney tissues: The last part of tissues from the liver and kidneys were fixed in 10% neutral buffered formalin. The fixed specimens were treated using the standard paraffin embedding method. 5-m thick slices were cut from the prepared paraffin blocks and stained with haematoxylin and eosin staining (Bancroft and Stevens, 1996).

Gene expression analysis of immune genes: Total RNA was extracted from liver and kidney tissues according to the method previously described (Zou *et al.*, 2014) with slight modifications. RNA purity and concentration were determined using NanoDrop spectrophotometer at 260/280nm (Q5000 UV-vis spectrophotometer, San Jose, USA) and RNA samples were stored frozen at -80°C until time of analysis. A total of 5 μg of total RNA was used as a template for synthesis of cDNA using Revert Aid™ reverse transcriptase (Fermentas, Thermo Scientific, USA) following the instructions manual. Real-time PCR system (SensiFAST™ SYBR® No-ROX Kit, Apparatus, Thermo scientific, USA) and SYBR® Green

PCR Master Mix 2x (Introbio, South Korea) were used to detect the expression of TNF- α , IL-8, IL-10 and IL-1 β in the examined tissues. Elongation factor-1 α (EF1- α) was used as a housekeeping gene. The accession number of primers that were used for the current real-time PCR are shown in Table 2. Amplification and general cycling protocol were conducted as follow: initial denaturation at 95°C for 10 mins followed by 45 cycles for denaturation at $95^{\circ}\text{C}/30\text{ s}$, annealing at $60^{\circ}\text{C}/30\text{ s}$, and extension at $72^{\circ}\text{C}/30\text{ s}$. The expression of GST, and pro-inflammatory cytokines (TNF- α , IL-8, IL-10, and IL-1 β) as well as EF-1 α , was analyzed proportionate to EF-1 α using the comparative CT method ($2^{-\Delta\Delta\text{CT}}$ method) (Livak *et al.*, 2001).

Table 2 Primers used for real-time PCR analysis of gene expression

Gene	Forward primer (5'-3')	Reverse primer (5'-3')	NCBI Accession number
TNF- α	CCAGAAAGCACTAAAGGCGAAGA	CCTTGGCTTTGCTGCTGATC	AY428948.1
IL-8	CTGT TCGCCACCTG TGAAGG	TCTT GTTGATCACITTTCTTC ACCCA	NM_001279704
IL-10	CTGCTAGATCAGTCCGTCGAA	GCAGAACCGTGTCCAGGTAA	XM_003441366.2
IL-1 β	CTGTGTGACAACTCTCAGAAAGATCTTG	TGTCATCATGGTATTGCTCCAGAA	XM_005457887
EF1- α	TGATCTACAAGTGGGAGGAA	GGAGCCCTTTCCCATCTCA	AB075952.1

NCBI: National Center for Biotechnology Information; TNF- α : tumor necrosis factor-alpha; IL: interleukin; EF1 α : Elongation factor 1 α

Statistical analysis: Data analysis and differences among variables was performed using the SPSS software statistical package (version 20, USA). Mean and standard error of the mean (SEM) were calculated for all measured analytes. One-way analysis of variance (ANOVA) was applied to detect the differences among variables followed by Duncan multiple range tests. Differences were considered statistically significant when P values were less than 0.05 ($P < 0.05$). Normality and homogeneity of variance for all recorded data were confirmed with Shapiro-Wilk and Levene's test, respectively.

Results

Analysis of liver and kidney parameters, oxidative stress biomarkers and antioxidant enzymes in serum and tissues: DZN intoxication induced a significant elevation of liver function parameters (AST and ALT; Table 3), kidney function parameters (uric acid and creatinine; Table 3) and lipid peroxidation marker (MDA; Table 4) in the serum of all treatment (T1-T4)

groups compared to the control. Furthermore, DZN intoxication induced a significant reduction in total protein, albumin, globulin and A/G ratio, TAC, GSH concentration, and activities of CAT, GST and GPX in the serum of all treatment (T1-T4) groups compared to the control (Table 4). These effects were time exposure dependent (Tables 3 and 4). Data summarized in Table 5 indicates that, DZN intoxication induced a significant elevation in MDA concentration and a significant reduction in GSH concentration and activities of CAT and GPX enzymes in the liver and kidney tissues of all treatment (T1-T4) groups compared to the control. These effects were time exposure dependent (Table 5).

Cytokine genes expression analysis in liver and kidney tissues: DZN intoxication induced a significant elevation in gene expression levels of TNF- α , IL-8, IL-1 β accompanied by a significant reduction in IL-10 gene expression levels in the liver and kidney tissues of all treatment (T1-T4) groups compared to the control (Table 6). These effects were time exposure dependent.

Table 3 Biochemical parameters in the serum of Nile tilapia (*Oreochromis niloticus*) exposed to DZN at 0.28 mg/L (1/10 LC50) for 1, 2, 3 and 4 weeks compared to the control.

Parameters	Groups					P value
	(Control)	T1	T2	T3	T4	
ALT (U/L)	10.46 \pm 0.028 ^e	16.04 \pm 1.01 ^d	20.75 \pm 0.79 ^c	25.56 \pm 0.63 ^b	28.36 \pm 0.56 ^a	($p < 0.01$)
AST(U/L)	51.62 \pm 0.60 ^e	66.38 \pm 0.68 ^d	72.08 \pm 0.35 ^c	88.91 \pm 0.55 ^b	105.46 \pm 0.98 ^a	($p < 0.01$)
TP (g/dl)	4.28 \pm 0.04 ^a	3.81 \pm 0.04 ^b	3.37 \pm 0.03 ^c	3.00 \pm 0.03 ^d	2.80 \pm 0.02 ^e	($p < 0.01$)
Albumin (g/dl)	1.81 \pm 0.07 ^a	1.55 \pm 0.05 ^b	1.31 \pm 0.04 ^c	1.10 \pm 0.03 ^d	1.00 \pm 0.03 ^e	($p > 0.05$)
Globulin (g/dl)	2.47 \pm 0.08 ^a	2.26 \pm 0.11 ^b	2.06 \pm 0.08 ^c	1.90 \pm 0.08 ^d	1.80 \pm 0.11 ^e	($p < 0.01$)
A/G ratio (%)	0.73 \pm 0.01 ^a	0.68 \pm 0.01 ^b	0.63 \pm 0.0 ^c	0.57 \pm 0.01 ^d	0.55 \pm 0.01 ^e	($p < 0.01$)
Creatinine (mg/dl)	0.42 \pm 0.02 ^e	0.67 \pm 0.02 ^d	1.77 \pm 0.02 ^c	2.1 \pm 0.01 ^b	2.92 \pm 0.02 ^a	($p < 0.01$)
Uric acid (mg/dl)	5.07 \pm 0.09 ^e	6.1 \pm 0.05 ^d	7.11 \pm 0.03 ^c	8.0 \pm 0.02 ^b	9.08 \pm 0.01 ^a	($p < 0.01$)

^{a-e}Means within a row not sharing a common superscript differ significantly with corresponding p value. Control: Fish supplied with water free of DZN throughout the experiment (4 weeks). T1-T4: Fish treated with DZN at 0.28 mg/L for one, two, three and four weeks, respectively. ALT: alanine transferase; AST: aspartate transferase; TP: total protein; A/G ratio: albumin/ globulin ratio/

Table 4 Oxidative stress biomarkers in serum of Nile tilapia (*Oreochromis niloticus*) exposed to DZN at 0.28 mg/L (1/10 LC50) for 1, 2, 3 and 4 weeks compared to the control.

Parameters	Groups					P value
	(Control)	T1	T2	T3	T4	
MDA (nmol/ml)	21.1±0.01 ^e	24.19±0.02 ^d	27.5±0.04 ^c	29.35±0.02 ^b	32.34±0.04 ^a	(<i>p</i> < 0.01)
TAC (mM/L)	1.37±0.02 ^a	1.30±0.03 ^b	1.27±0.02 ^c	1.24±0.03 ^d	1.15±0.03 ^e	(<i>p</i> < 0.05)
CAT (U/L)	495.5±2.68 ^a	451.74±5.03 ^b	421.98±6.93 ^c	409.33±6.18 ^d	390.30±5.73 ^e	(<i>p</i> < 0.01)
GST (U/L)	139.52±3.5 ^a	121.64±3.95 ^b	113.2±2.94 ^c	100.27±3.05 ^d	40.05±1.77 ^e	(<i>p</i> < 0.01)
GSH (U/mg)	9.96±0.09 ^a	7.67±0.08 ^b	5.13±0.08 ^c	4.76±0.06 ^d	2.23±0.03 ^e	(<i>p</i> < 0.01)
GPX (U/mg)	13.62±0.19 ^a	11.84±0.24 ^b	9.73±0.19 ^c	7.12±0.17 ^d	5.17±0.12 ^e	(<i>p</i> < 0.01)

^{a-e}Means within a row not sharing a common superscript differ significantly with corresponding *p* value. Control: Fish supplied with water free of DZN throughout the experiment (4 weeks). T1-T4: Fish treated with DZN at 0.28 mg/L for one, two, three and four weeks, respectively. MDA: malondialdehyde; TAC: total antioxidant capacity; CAT: catalase; GST: glutathione-S-transferase; GSH: reduced glutathione; GPX: glutathione peroxidase.

Table 5 Oxidative stress biomarkers in liver and kidney tissues of Nile tilapia (*Oreochromis niloticus*) exposed to DZN at 0.28 mg/L (1/10 LC50) for 1, 2, 3 and 4 weeks compared to the control.

Parameters	Groups					P value
	(Control)	T1	T2	T3	T4	
Liver						
MDA (nmol/g)	18.73±0.15 ^e	22.74±0.41 ^d	30.46±0.25 ^c	33.61±0.52 ^b	37.1±0.43 ^a	(<i>p</i> < 0.01)
CAT (U/g)	7.60±0.13 ^a	6.46±0.09 ^b	5.12±0.08 ^c	4.13±0.06 ^d	3.95±0.08 ^e	(<i>p</i> < 0.01)
GST (U/g)	234.61±1.51 ^a	159.28±2.34 ^b	138.1±1.49 ^c	119.32±3.51 ^d	100.93±3.0 ^e	(<i>p</i> < 0.01)
GSH (mg/g)	49.87±1.83 ^a	41.33±0.70 ^b	35.32±0.94 ^c	30.02±1.37 ^d	26.27±1.13 ^e	(<i>p</i> < 0.01)
Kidney						
MDA (nmol/g)	28.28±0.44 ^e	38.42±0.51 ^d	47.40±0.69 ^c	58.34±0.95 ^b	69.48±0.61 ^a	(<i>p</i> < 0.01)
CAT (U/g)	6.78±0.03 ^a	4.51±0.05 ^b	3.38±0.04 ^c	2.29±0.06 ^d	1.50±0.08 ^e	(<i>p</i> < 0.01)
GST (U/g)	215.91±2.43 ^a	179.73±4.36 ^b	150.62±1.44 ^c	141.3±2.06 ^d	128.51±2.54 ^e	(<i>p</i> < 0.01)
GSH (mg/g)	38.37±0.65 ^a	26.88±0.36 ^b	20.39±0.73 ^c	15.64±0.16 ^d	10.79±0.19 ^e	(<i>p</i> < 0.01)

^{a-e}Means within a row not sharing a common superscript differ significantly with corresponding *p* value. Control: Fish supplied with water free of DZN throughout the experiment (4 weeks). T1-T4: Fish treated with DZN at 0.28 mg/L for one, two, three and four weeks, respectively. MDA: malondialdehyde; CAT: catalase; GST: glutathione-S-transferase; GSH: reduced glutathione; GPX: glutathione peroxidase.

Table 6 Analysis of Cytokines (TNF- α , IL-8, IL-10, and IL-1 β) genes expression in liver and kidney tissues of Nile tilapia (*Oreochromis niloticus*) exposed to DZN at 0.28 mg/L (1/10 LC50) for 1, 2, 3 and 4 weeks compared to the control.

Parameters	Groups					P value
	(Control)	T1	T2	T3	T4	
Liver						
TNF- α	1±0.01 ^e	6.97±0.15 ^d	8.66±0.09 ^c	10.04±0.11 ^b	13.61±0.09 ^a	(<i>p</i> < 0.01)
IL-8	1±0.01 ^e	4.39±0.2 ^d	6.73±0.19 ^c	8.12±0.16 ^b	11.20±0.24 ^a	(<i>p</i> < 0.01)
IL-10	1±0.01 ^a	0.71±0.01 ^b	0.53±0.03 ^c	0.42±0.01 ^d	0.31±0.02 ^e	(<i>p</i> < 0.01)
IL-1 β	1±0.01 ^e	4.87±0.13 ^d	6.91±0.08 ^c	7.99±0.09 ^b	9.89±0.08 ^a	(<i>p</i> < 0.01)
Kidney						
TNF- α	1±0.01 ^e	5.93±0.16 ^d	7.54±0.09 ^c	10.05±0.14 ^b	12.12±0.19 ^a	(<i>p</i> < 0.01)
IL-8	1±0.01 ^e	4.64±0.06 ^d	7.08±0.09 ^c	11.21±0.07 ^b	13.15±0.13 ^a	(<i>p</i> < 0.01)
IL-10	1±0.01 ^a	0.86±0.02 ^b	0.64±0.02 ^c	0.48±0.02 ^d	0.28±0.02 ^e	(<i>p</i> < 0.01)
IL-1 β	1±0.01 ^e	5.46±0.14 ^d	9.06±0.16 ^c	12.93±0.18 ^b	16.85±0.13 ^a	(<i>p</i> < 0.01)

^{a-e}Means within a row not sharing a common superscript differ significantly with corresponding *p* value. Control: Fish supplied with water free of DZN throughout the experiment (4 weeks). T1-T4: Fish treated with DZN at 0.28 mg/L for one, two, three and four weeks, respectively. TNF- α : tumor necrosis factor-alpha; IL: interleukin.

Histopathological analysis of liver and kidney tissues:

Light microscopic examination of control livers (Fig. 1a) showed large polygonal hepatocytes. The hepatocytes were aligned in cords separated by blood sinusoids. Each hepatocyte showed a distinct round and central nucleus with nucleoli and granular cytoplasm. DZN treated liver for one week (Fig. 1b,c) showed congestion, massive necrosis and degeneration of hepatocytes with marked hemosiderosis. DZN treated liver for two weeks (Fig. 1d,e) showed eosinophilic recruitment around portal vein extensive necrosis of hepatocytes and marked hemosiderosis. DZN treated liver for three weeks (Fig. 1f,g) showed necrosis of hepatocytes and eosinophilic recruitment into hepatic tissue with diffuse hemosiderosis. DZN treated liver for four weeks (Fig. 1h,i) showed massive degeneration and necrosis of

hepatocytes with marked hemosiderosis. Histology of control kidneys (Fig. 2a,) of Nile tilapia fish showed distinct and normal sized proximal and distal conducting tubules, glomeruli and interstitial connective tissues. DZN treated kidney for one week (Fig. 2b,c) showed necrosis and desquamation and vacuolation of renal tubular epithelium. Whereas, DZN treated kidneys for two weeks (Fig. 2d,e) showed necrosis of renal tissue and aggregation mononuclear exudate. DZN treated kidneys for three weeks (Fig. 2f,g) showed desquamation of renal tubular epithelium and proliferation of glomeruli and mesangial cells. DZN treated kidneys for four weeks (Fig. 2h,i) showed mononuclear cell infiltration in interstitial tissue and necrosis of renal glomeruli.

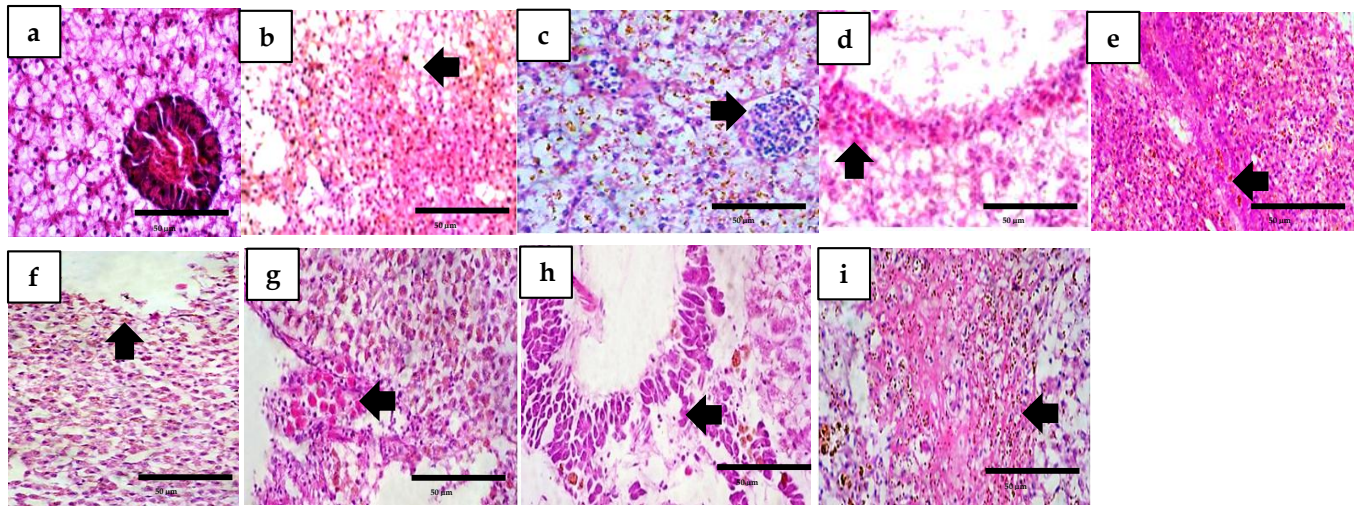


Figure 1 Histopathological examination of liver tissue (a) control liver showed large polygonal hepatocytes. The hepatocytes aligned in cords separated by blood sinusoids. Each hepatocyte showed a distinct round and central nucleus with nucleoli and granular cytoplasm. (b and c) DZN treated liver for one week (T1) showed congestion, massive necrosis and degeneration of hepatocytes with marked hemossiderosis (arrows). (d and e) DZN treated liver for two weeks (T2) showed eosinophilic recruitment around portal vein extensive necrosis of hepatocytes and marked hemossiderosis (arrows). (f and g) DZN treated liver for three weeks (T3) showed necrosis of hepatocytes and eosinophilic recruitment into hepatic tissue with diffuse hemossiderosis (arrows). (h and i) DZN treated liver for four weeks (T4) showed massive degeneration and necrosis of hepatocytes with marked hemossiderosis (arrows).

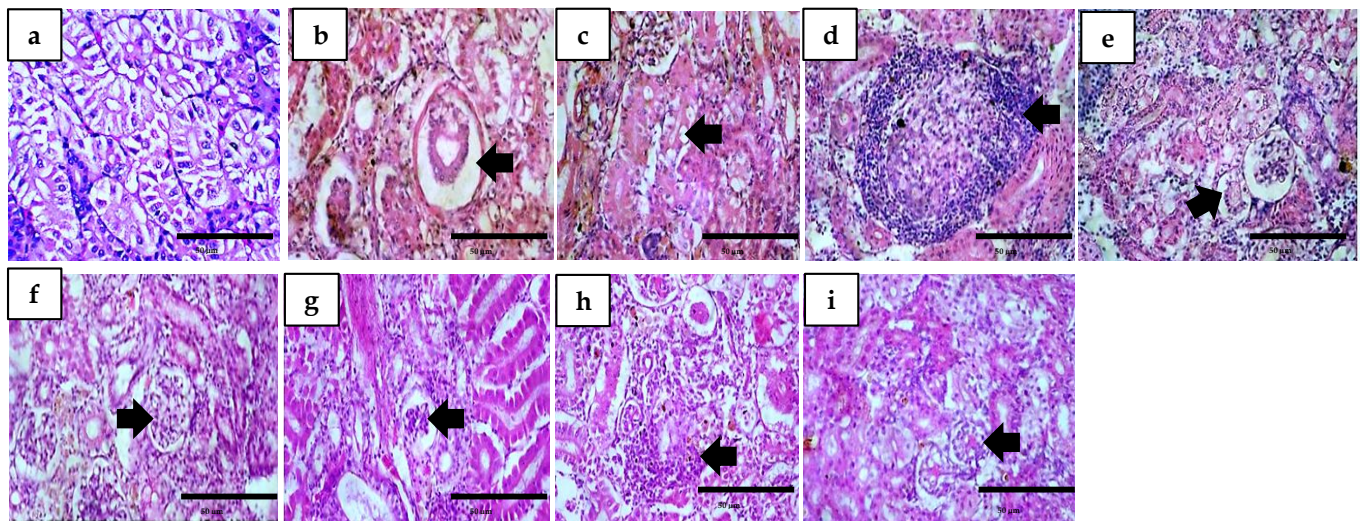


Figure 2 Histopathological examination of kidney tissue of Nile tilapia fish. (a) control kidney showed distinct and normal sized proximal and distal conducting tubules, glomeruli and interstitial connective tissues. (b and c) DZN treated kidney for one week (T1) showed necrosis and desquamation and vacuolation of renal tubular epithelium (arrows). (d and e) DZN treated kidney for two weeks (T2) showed necrosis of renal tissue and aggregation mononuclear exudate (arrows). (f and g) DZN treated kidney for three weeks (T3) showed desquamation of renal tubular epithelium and proliferation of glomeruli and mesangial cells (arrows). (h and i) DZN treated kidney for four weeks (T4) showed mononuclear cell infiltration in interstitial tissue and necrosis of renal glomeruli (arrows).

Discussion

Analysis of liver and kidney parameters, oxidative stress biomarkers and antioxidant enzymes in serum and tissues: To evaluate the acute and subchronic toxicity of DZN, the current experiment was divided into four exposure time points starting at 1, 2, 3 and 4 weeks. Furthermore, this was done to ensure toxic buildup in fish tissues and precise blood parameter detection (Girón-Pérez *et al.*, 2009). One week is enough time to ensure that any changes in blood and tissue parameters have occurred. The effects of diazinon on farmed fish have been monitored using changes in blood biochemical markers as a sensitive indication (Banaee *et al.*, 2011; Abdelhamid, 2020). According to

the current findings, DZN exposure significantly increased serum ALT and AST activity in all DZN-treated groups as compared to the control group. This was a dose-dependent rise. This increase in serum ALT and AST indicated liver damage because these enzymes are cytoplasmic in location and their release into circulation indicated damage to the cell membrane (El-Bahr, 2013). Diazinon metabolized by liver cytochrome P450 monooxygenase, converted it to diazoxon and other metabolites, including pyrimidinol (Abdelhamid, 2020). These metabolites induced a state of lipid peroxidation and increased ROS and hepatocyte permeability which allowed liver transaminase (ALT and AST) to seep into the

bloodstream (Srivastava *et al.*, 2004). After 30 days of exposure to three sub-lethal levels of diazinon (0.73, 1.095, and 1.46 mg/l), AST and ALT levels in *Clarias gariepinus* considerably increased (Al-Otaibi *et al.*, 2019). Furthermore, total serum protein, albumin, and globulin levels, as well as the A/G ratio, were considerably lower in all DZN treated groups compared to control. This was a dose-dependent decline. In Juvenile B. sharpeyi (*Barbus sharpeyi*) treated to DZN, similar findings (Alishahi *et al.*, 2016) indicated that total protein and globulin levels were significantly decreased. The decrease in total protein concentration had major consequences for cell physiology and fish growth (Toledo-Ibarra *et al.*, 2016). DZN has immunosuppressive effects, as evidenced by the considerable decrease in globulin levels in DZN-treated fish. DZN dramatically lowered lysozyme activity and immunoglobulin G (IgG) levels, as demonstrated earlier (Abdelhamid, 2020). In addition, a significant decrease in total plasma immunoglobulin in rainbow trout (*Oncorhynchus mykiss*) was observed after 60 days of exposure to a sub-lethal dosage of diazinon (0.287 mg/l; Hajirezaee *et al.*, 2019). Diazinon-induced tissue death and hepatocyte apoptosis could be the main explanations for the liver's reduced production of total protein and immunoglobulin (Gokcimen *et al.*, 2007). Creatinine and uric acid levels were similarly higher in DZN-exposed fish than in control fish, confirming the current findings (Alishahi *et al.*, 2016; Abbas *et al.*, 2021). Fish kidneys have excretory functions, maintain osmotic balance between the fish and its surroundings and serve as a hemopoietic organ (Henderson *et al.*, 1985). Due to renal glutathione depletion, the glomerular filtration rate of the fish intoxicated with DZN decreased, resulting in an increase in serum creatinine levels (Akturk *et al.*, 2006).

Pesticide poisoning in fish has long been known to cause oxidative damage due to an excess of reactive oxygen species (ROS) and the incapacity of enzymatic and non-enzymatic antioxidant defense systems to remove or neutralize ROS and protect cells from oxidative damage (Banaee *et al.*, 2013). The antioxidant enzymes SOD and catalase are the initial lines of defense against oxidative cell damage (Mohanty *et al.*, 2018). Fish with injured livers and kidneys have a large reduction in serum antioxidant status (Hai *et al.*, 1997), but DZN-intoxicated fish have a significant increase in MDA activity, which is an obvious response to DZN toxicity (Akturk *et al.*, 2006). In the current study, DZN increased MDA levels in serum, liver and kidneys, whereas antioxidant enzymes (CAT, GST, and GSH) activity in serum, liver, and kidneys was reduced considerably compared to the control. The results were similar to that observed earlier in Nile tilapia (Abdelkhalek *et al.*, 2017), Zebrafish (Al-Ghanim *et al.*, 2020) and catfish (Ali *et al.*, 2015). After 45 and 90 days of DZN exposure, Nile tilapia showed a significant decrease in blood levels of catalase (CAT), copper zinc superoxide dismutase (Cu Zn-SOD) and reduced glutathione (GSH), as well as a significant increase in the oxidative stress marker malondialdehyde (MDA) (Abbas *et al.*, 2021). In the current study, there was a dose-dependent increase in MDA levels and a decrease in the activity of the examined antioxidant enzymes in

serum, liver and kidneys. The increased MDA suggested lipid oxidation, which was caused by an abundance of strong oxidizing radicals (superoxide and hydroxyl anions) produced during DZN metabolism (Mirvaghefi *et al.*, 2016), which was accompanied by a decrease in GSH activity (Giordano *et al.*, 2007). Furthermore, xenobiotics may promote glutathione breakdown or decrease glutathione synthesis, resulting in lower GSH levels (Guptha *et al.*, 2016). Antioxidant enzyme activity can be increased or decreased based on a variety of parameters such as the type of xenobiotic, the exposure length, tolerance, species and so on (Slaninova *et al.*, 2009). In rainbow trout, *Oncorhynchus mykiss*, DZN toxicity (0.287 mg/l) caused lipid peroxidation, resulting in increased hepatic MDA and decreased hepatic SOD, CAT, GSH-Px, and TAC (Rafieepour *et al.*, 2018). After 28 days of exposure to 0.28 mg/L DZN, Nile tilapia's liver and kidneys showed a significant decrease in catalase, GSH, and SOD activity, as well as a large increase in MDA (Abdelkhalek *et al.*, 2017).

Cytokine genes expression analysis in liver and kidney tissues:

In terms of the mRNA levels of pro-inflammatory cytokine TNF- α and anti-inflammatory cytokine IL-10 in the liver and kidney, the current findings showed that TNF- α , IL-8, and IL-1 β were considerably enhanced while IL-10 was reduced in DZN exposed fish compared to the control. In the spleen of DZN-intoxicated Nile tilapia (*Oreochromis niloticus*), TNF- α gene expression was elevated whereas IL-10 gene expression was downregulated (Abdelhamid, 2020). After 60 days of exposure to 0.287 mg/L diazinon, significant increases in renal IL-1 β were also observed in rainbow trout (*Oncorhynchus mykiss*; Hajirezaee *et al.* 2019), and Nile tilapia (*Oreochromis niloticus*; Abdelhamid, 2020). These could be attributable to inflammatory reactions resulting from diazinon-induced cell damage (Eder *et al.*, 2006). DZN also activated macrophages and enhanced inflammatory responses by causing excessive ROS production, which activated the NF- κ B pathway, resulting in the expression of inflammatory cytokines (TNF- α IL-1 β and IL-6), inducible cyclooxygenase (COX-2) and inducible nitric oxide synthase (iNOS) (Ogasawara *et al.*, 2017).

Histopathological analysis of liver and kidney tissues:

Based on histopathological examination, various hepatic lesions, including congestion, massive necrosis and degeneration of hepatocytes with marked hemosiderosis have been accompanied by hepatic function alteration. The current results were similar to those reported earlier (Hoekstra *et al.*, 2013; Abbas *et al.*, 2021). These histopathological findings confirmed the obtained biochemical alteration in liver enzymes (ALT and AST) in fish exposed to DZN compared to control. In common carp exposed to DZN, dilation of bile ducts, sinusoids, hepatic veins, congestion, lymphocyte infiltration, pyknotic nucleus pigment deposition and necrosis were seen (Korkmaz and Donmez, 2017). DZN caused an increase in urea and creatinine levels in the blood, as well as histological changes that indicate a low glomerular filtration rate and kidney problems. Glomerular shrinkage, tubular

lumen decreasing, renal tubule necrosis, and degeneration were the main histopathological lesion observed in DZN-intoxicated rainbow trout (*Oncorhynchus mykiss*; Banaee et al., 2013). Hepatocyte necrosis, renal glomerular enlargement and hemorrhages, were histological changes caused by DZN toxicity in catfish, which were similar to the current findings (Al-Otaibi et al., 2019). DZN intoxicated Nile Tilapia exhibited hepatorenal necrosis, which intensified with the length of fish exposure to DZN. This effect was evidenced in histopathological pictures of liver and kidney tissues as indicated in the following paragraphs. The histopathological pictures of liver tissue in DZN treated fish for one week showed congestion, massive necrosis and degeneration. After 2 weeks of DZN exposure, these changes were in the form of eosinophilic recruitment around portal vein with extensive necrosis of hepatocytes. However, DZN treated liver for three and four weeks showed diffuse hemosiderosis. The same effect of time exposure was observed in kidney tissue. The histopathological examination of kidney tissue in DZN treated fish for one week showed necrosis and vacuolation of renal tubular epithelium. After two weeks of DZN exposure, aggregation of mononuclear exudate was observed. However, after 3 weeks of DZN exposure, proliferation of glomeruli and mesangial cells were observed. After 4 weeks DZN exposure, mononuclear cell infiltration in interstitial tissue and necrosis of renal glomeruli were the most pathognomonic lesions.

In conclusion, the current study concluded that the activities of AST and ALT and the concentrations of uric acid, creatinine and MDA increased significantly in serum of DZN treated fish compared to the control. Total protein, albumin, globulin and A/G ratio, GSH concentration and activities of CAT, GST and GPX decreased significantly in serum of DZN treated fish compared to the control. DZN intoxication induced a significant elevation in MDA concentration and a significant reduction in GSH concentration and activities of CAT and GPX enzymes in the liver and kidney tissues of DZN treated fish compared to the control. DZN intoxication induced a significant elevation in gene expression levels of TNF- α , IL-8, IL-1 β accompanied by a significant reduction in IL-10 gene expression level in the liver and kidney tissues of DZN treated fish compared to the control. Histopathology showed congestion, massive necrosis and degeneration of hepatocytes with marked hemosiderosis necrosis and desquamation as well as vacuolation of renal tubular epithelium, necrosis of renal tissue and desquamation of renal tubular epithelium in DZN treated fish compared to control. DZN related effects were time exposure dependent. This study suggested that DZN induced a time exposure-dependent oxidative damage and impaired cytokines gene expression in Nile Tilapia (*Oreochromis niloticus*).

Conflicts of interest: There were no conflicts of interest that may have biased the work reported in this study.

Acknowledgements

The authors thank the Deanship of Scientific Research, King Faisal University, Al-Ahsa, Saudi Arabia for financial support (Nasher track grant # 216071) of this study.

Authors' contribution: Mahmoud El Sebaei, Mohammad Shathele and Sabry El-Bahr: Conceptualization, Investigation, Methodology, Software, Data curation, Writing – review & editing, Writing – original draft and approved the final version of the manuscript.

References

- Abbas EA, Mowafy RE, Khalil AA, Sdeek FA 2021. The potential role of the dietary addition of bentonite clay powder in mitigating diazinon-induced hepatorenal damage, oxidative stress, and pathological alterations in Nile tilapia. *Aquaculture*. 533, 736182.
- Abdelhamid FM, Elshopakey GE, Aziza AE 2020. Ameliorative effects of dietary *Chlorella vulgaris* and β -glucan against diazinon-induced toxicity in Nile tilapia (*Oreochromis niloticus*). *Fish Shellfish Immunol*. 96: 213–222.
- Abdelkhalek NK, Eissa IA, Ahmed E, Kilany OE, El-Adl M, Dawood MA, Abdel-Daim MM 2017. Protective role of dietary *Spirulina platensis* against diazinon-induced Oxidative damage in Nile tilapia; *Oreochromis niloticus*. *Environ Toxicol Pharmacol*. 54: 99–104.
- Abhilash P and Singh N 2009. Pesticide use and application: an Indian scenario. *J Hazard Mater*. 165: 1–12.
- Akturk O, Demirin H, Sutcu R, Yilmaz N, Koylu H, Altuntas I 2006. The effects of diazinon on lipid peroxidation and antioxidant enzymes in rat heart and ameliorating role of vitamin E and vitamin C. *Cell Biol. Toxicol*. 22: 455.
- Al-Ghanim KA, Mahboob S, Vijayaraghavan P, Al-Misned FA, Kim YO, Kim H J 2020. Sub-lethal effect of synthetic pyrethroid pesticide on metabolic enzymes and protein profile of non-target Zebrafish, *Danio rerio*. *Saudi J Biol Sci*. 27: 441–447.
- Ali M, Mirvaghefi A, Asadi F 2015. Effects of vitamin E, selenium, and vitamin C on various biomarkers following oxidative stress caused by diazinon exposure in rainbow trout. *J Aquac Mar Biol*. 2: 1–9.
- Alishahi M, Mohammadi A, Mesbah M, Razi Jalali M 2016. Haemato-immunological responses to diazinon chronic toxicity in *Barbus sharpeyi*. *Iran J Fish Sci*. 15: 870–885.
- Al-Otaibi AM, Al-Balawi HFA, Ahmad Z, Suliman EM 2019. Toxicity bioassay and sub-lethal effects of diazinon on blood profile and histology of liver, gills and kidney of catfish, *Clarias gariepinus*. *Braz J Biol*. 79: 326–336.
- Al-Otaibi AM, Al-Balawi HFA, Ahmad Z, Suliman EM 2019. Toxicity bioassay and sub-lethal effects of diazinon on blood profile and histology of liver, gills, and kidney of catfish, *Clarias gariepinus*. *Braz J Biol*. 79 (2).

- Banaee M, Sureda A, Mirvaghefi AR, Ahmadi K 2011. Effects of diazinon on biochemical parameters of blood in rainbow trout (*Oncorhynchus mykiss*). *Pestic Biochem Physiol.* 99: 1-6.
- Banaee M, Sureda A, Mirvaghefi AR, Ahmadi K 2013. Biochemical and histological changes in the liver tissue of rainbow trout (*Oncorhynchus mykiss*) exposed to sublethal concentrations of diazinon. *Fish Physiol Biochem.* 39: 489-501.
- Bancroft, J.D., Gamble, M., 2008. Theory and practice of histological techniques. Elsevier health sciences.
- Cai J and Leung PS. 2017. Short-term Projection of Global Fish Demand and Supply Gaps. FAO Fisheries and Aquaculture technical paper, (607).
- Cengiz EI and Unlu E 2006. Sublethal effects of commercial deltamethrin on the structure of the gill, liver and gut tissues of mosquitofish, *Gambusia affinis*: a microscopic study. *Environ Toxicol Pharmacol.* 21: 246-253.
- Eder KJ, Clifford MA, Hedrick RP, Köhler HR, Werner I 2008. Expression of immune- regulatory genes in juvenile Chinook salmon following exposure to pesticides and infectious hematopoietic necrosis virus (IHNV). *Fish Shellfish Immunol.* 25: 508-516.
- El-Sayed AFM. 2017a. Regional Review on Status and Trends in Aquaculture Development in the Near East and North Africa-2015, FAO Fisheries and Aquaculture Circular, C1135/6 #43 p.
- El-Bahr SM. 2014. Camel Milk Regulates Gene Expression and Activities of Hepatic Antioxidant Enzymes in Rats Intoxicated with Carbon Tetrachloride. *Asian J. Biochem.* 9: 30-40.
- El-Sayed AFM. 2017b. Tilapia Co-culture in Egypt, Tilapia in Intensive Co-culture. 211-236.
- El-Sayed YS and Saad TT. 2008. Subacute intoxication of a deltamethrin-based preparation (Butox® 5% EC) in monosex Nile Tilapia, *Oreochromis niloticus* L. *Basic Clin Pharmacol Toxicol.* 102: 293-299.
- El-Sherif MS, Ahmed MT, El-Danasoury, MA, El-Nwishy, NHK. 2009. Evaluation of diazinon toxicity on Nile tilapia fish (*O. niloticus*). *J Fish Aquat Sci.* 4: 169-177, doi: 10.3923/jfas.2009.169.177.
- Galloway T and Handy R 2003. Immunotoxicity of organophosphorous pesticides. *Ecotoxicology.* 12: 345-363.
- Girón-Pérez MI, Velázquez-Fernández J, Díaz-Resendiz K, Díaz-Salas F, Canto- Montero C, Medina-Díaz I, Robledo-Marengo M, Rojas-García A, Zaitseva G 2009. Immunologic parameters evaluations in Nile tilapia (*Oreochromis niloticus*) exposed to sublethal concentrations of diazinon. *Fish Shellfish Immunol.* 27: 383-385.
- Gokcimen A, Gulle K, Demirin H, Bayram D, Kocak A, Altuntas I 2007. Effects of diazinon at different doses on rat liver and pancreas tissues. *Pestic Biochem Physiol.* 87: 103-108.
- Guptha JS, Renuka M, Suneetha Y, Reddy MS 2016. Evaluation of antioxidant defense system during xenobiotic induced oxidative stress in freshwater fish *Oreochromis mossambicus*. *Int J Fish Aquat Stud.* 4: 379-385.
- Hai DQ, Varga SI, Matkovic B 1997. Organophosphate effects on antioxidant system of carp (*Cyprinus carpio*) and catfish (*Ictalurus nebulosus*). *Comp Biochem Physiol. Part C: Pharmacol Toxicol Endocrinol.* 117: 83-88.
- Hajirezaee S, Rafieepour A, Shafiei S, Rahimi R 2019. Immunostimulating effects of Ginkgo biloba extract against toxicity induced by organophosphate pesticide, diazinon in rainbow trout, *Oncorhynchus mykiss*: innate immunity components and immune-related genes. *Environ Sci Pollut Res.* 31: 1-10.
- Henderson IW, Hazon N, Hughes K 1985. Hormones, ionic regulation, and kidney function in fishes. *Symp Soc Exp Biol.* 39: 245-265.
- Hoekstra LT, de Graaf W, Nibourg GA, Heger M, Bennink RJ, Stieger B, van Gulik TM, 2013. Physiological and biochemical basis of clinical liver function tests: a review. *Ann Surg.* 257: 27-36.
- Korkmaz C and D'onzme E 2017. Effects of Diazinon on 17 β -estradiol, plasma Vitellogenin, liver and gonad tissues of common carp (*Cyprinus carpio*, L., 1758). *Mediterranean fisheries and Aquac Res.* 1: 4-5.
- Kumar N, Prabhu PAJ, Pal A, Remya S, Aklakur M, Rana R, Gupta S, Raman R, Jadhao S 2011. Anti-oxidative and immuno-hematological status of Tilapia (*Oreochromis mossambicus*) during acute toxicity test of endosulfan. *Pestic Biochem Physiol.* 99: 45-52.
- Li X, Liu L, Zhang Y, Fang Q, Li Y, Li Y, 2013b. Toxic effects of chlorpyrifos on lysozyme activities, the contents of complement C3 and IgM, and complement C3 expressions in common carp (*Cyprinus carpio*). *Chemosphere* 93: 428-433.
- Livak KJ, Schmittgen TD 2001. Analysis of relative gene expression data using realtime quantitative PCR and the 2- $\Delta\Delta$ CT method. *Methods* 25: 402-408.
- Livingstone DR 2001. Contaminant-stimulated reactive oxygen species production and oxidative damage in aquatic organisms. *Mar Pollut Bull.* 42: 656-666.
- Mirvaghefi A, Ali M, Poorbagher H 2016. Effects of vitamin C on oxidative stress parameters in rainbow trout exposed to diazinon. *Ege JFAS.* 33: 113-120.
- Mohanty D and Samanta L 2018. Dietary supplementation of Spirulina ameliorates iron-induced oxidative stress in Indian knife fish *Notopterus Notopterus*. *Environ Toxicol Pharmacol.* 61: 71-78.
- NRC 2011. Nutrient Requirements of Fish and Shrimps. National Academies Press, Washington, DC. p. 392.
- Oakes KD, McMaster ME, Van Der Kraak GJ 2004. Oxidative stress responses in longnose sucker (*Catostomus catostomus*) exposed to pulp and paper mill and municipal sewage effluents. *Aquat Toxicol.* 67: 255-271.
- Ogasawara N, Matsushima M, Kawamura N, Atsumi K, Yamaguchi T, Ochi H, Ueyama J 2017. Modulation of immunological activity on macrophages induced by diazinon. *Toxicol.* 379: 22-30.
- Rafieepour A, Hajirezaee S, Rahimi R 2018. Dietary oregano extract (*Origanum vulgare* L.) enhances the antioxidant defence in rainbow trout, *Oncorhynchus mykiss* against toxicity induced by

- organophosphorus pesticide, diazinon. *Toxin Rev.* 1-11.
- Secombes C 2002. Cloning and bioactivity of fish cytokines and their relevance to disease resistance. *Bull.-Eur. Assoc. Fish Pathol.* 22: 110-116.
- Slaninova A, Smutna M, Modra HA 2009. Review: oxidative stress in fish induced by pesticides, *Neuroendocrinol. Lett.* 30: 2-12.
- Soliman NF and Yacout DM 2016. Aquaculture in Egypt: status, constraints and potentials. *Aquacult Int.* 24: 1201-1227.
- Srivastava AS, Oohara I, Suzuki T, Shenouda S, Singh S, Chauhan DP, Carrier E 2004. Purification and properties of cytosolic alanine aminotransferase from the liver of two freshwater fish, *Clarias batrachus* and *Labeo rohita*. *Comp Biochem Physiol B Biochem Mol Biol.* 137: 197-207.
- Storelli, M.M., 2008. Potential human health risks from metals (Hg, Cd, and Pb) and polychlorinated biphenyls (PCBs) via seafood consumption: estimation of target hazard quotients (THQs) and toxic equivalents (TEQs). *Food Chem Toxicol.* 46, 2782-2788.
- Toledo-Ibarra GA, Díaz Resendiz KJG, Ventura-Ramónb GH, González-Jaime F, Vega-López A, Becerril-Villanueva E, Pavón L, Girón-Pérez MI. 2016. Oxidative damage in gills and liver in Nile tilapia (*Oreochromis niloticus*) exposed to diazinon. *Comp Biochem Physiol. Part A* 200: 3-8.
- Yacout DMM, Soliman NF, Yacout MM. 2016. Comparative life cycle assessment (LCA) of Tilapia in two production systems: semi-intensive and intensive. *Int J Life Cycle Assess.* 21: 806-819.
- Zahran E, Risha E, Awadin W, Palić D 2018. Acute exposure to chlorpyrifos induces reversible changes in health parameters of Nile tilapia (*Oreochromis niloticus*) *Aqua Toxicol.* 197: 47-59.
- Zou J, Gorgoglione B, Taylor NG, Summathed T, Lee PT, Panigrahi A, Genet C, Chen YM, Chen TY, Hassan MU, S.M. Mughal SM 2014. Salmonids have an extraordinary complex type I IFN system: characterization of the IFN locus in rainbow trout *Oncorhynchus mykiss* reveals two novel IFN subgroups. *J Immunol.* 193: 2273-2286.