

## Radiographic cardiac indices for the evaluation of cardiac and left atrial sizes in healthy Wistar albino rats (*Rattus norvegicus*)

Mehmet Alper ÇETİNKAYA<sup>1</sup> Mahir KAYA<sup>2\*</sup>

### Abstract

This study was performed for the purpose of comparing vertebral heart score (VHS), radiographic left atrial dimension (RLAD) and vertebral left atrial size (VLAS) values derived from plain and contrast right lateral thoracic radiographs from 70 healthy, young adult Wistar albino rats and to identify reference values for these radiographic cardiac indices. Measurements were taken by two observers blinded to the study data. VHS, RLAD and VLAS median values and reference ranges were 8v and 7-9.3v for plain radiography, 8.2v and 7.4-9.5v for contrast radiography ( $P < 0.000$ ), 1.3v and 1-1.8v for plain radiography, 1.3v and 1.1-1.6v for contrast radiography ( $P < 0.000$ ) and 1.9v and 1.4-2.4v for plain radiography and 1.95v 1.5-2.4v for contrast radiography ( $P < 0.001$ ), respectively. The only statistically significant difference was observed in terms of gender between VHS values from plain and contrast radiographs ( $P < 0.02$ ). Intraobserver and interobserver measurements revealed excellent agreement for radiographic cardiac indices obtained from contrast radiography. The study measurements indicate that contrast radiography provides a more effective quantitative assessment of cardiac and left atrial sizes than plain radiography. The radiographic cardiac index measurements presented in this study can serve as a reference baseline for both veterinarians and experimental cardiovascular studies.

---

**Keywords:** Thoracic radiography, VHS, RLAD, VLAS, Wistar albino rat

---

<sup>1</sup>Hacettepe University, Laboratory Animal Research and Application Center, 06100, Sıhhiye-Ankara, Turkey

<sup>2</sup>Medical Imaging Techniques Program, Health Services Vocational College, Akdeniz University, 07070, Antalya, Turkey

\*Correspondence: kayamahir@gmail.com (M. KAYA)

Received February 14, 2022

Accepted June 7, 2022

<https://doi.org/10.14456/tjvm.2022.55>

## Introduction

Cardiac diseases seen in pet rats (Sharp and Villano, 2012; Dias *et al.*, 2017), whose numbers are increasing rapidly, are also observed in other small exotic mammals including ferrets (Wagner, 2009), rabbits (Orcutt and Malakoff, 2020) and African hedgehogs (Black *et al.*, 2011). Spontaneous cardiomyopathy is relatively common in older rats as part of the ageing process. The presence of left atrial and ventricular thrombosis in elderly rats has been linked to cardiomyopathy in previous studies (McInnes, 2012).

Diagnostic imaging methods are important to the rapid and accurate diagnosis of cardiac diseases in pet rats and during follow-up in the therapeutic process. Radiological cardiac evaluation may also be required in experimental rat studies. Although echocardiography is an important imaging technique in the diagnosis of cardiac diseases, a special ultrasonography probe and software are required due to rats' small body mass and high heart rate and experience is also needed on the part of the operator (Dias *et al.*, 2021). Thoracic radiography is simpler and less expensive than echocardiography. The dimension of the cardiac silhouette can be evaluated both subjectively and objectively using thoracic radiography in cats and dogs, while other x-ray findings suggesting the presence of congestive heart disease, such as pulmonary edema, pleural effusion, an enlarged caudal vena cava (CaCV) and hepatomegaly-related hepatic congestion can also be identified.

The vertebral heart score (VHS) system for the objective measurement of the cardiac silhouette with thoracic radiography was first developed for dogs (Buchanan and Bucheler, 1995) and this evaluation system has also been described for several other species (Stepien *et al.*, 1999; Litster and Buchanan 2000; Onuma *et al.*, 2010; Black *et al.*, 2011; de Moura *et al.*, 2015; Garcia *et al.*, 2016; Dickson *et al.*, 2016; Doss *et al.*, 2017) including Sprague-Dawley (Dias *et al.*, 2021) and Wistar albino (Dogan *et al.*, 2022) rats.

As in VHS, there are two new indices capable of objectively evaluating the size of the left atrium from thoracic radiography in dogs - vertebral left atrial size (VLAS) (Malcom *et al.*, 2018) and radiographic left atrial dimension (RLAD) (Sanchez Salguero *et al.*, 2018). VLAS was recently included by the American College of Veterinary Internal Medicine in the consensus guidelines in the diagnosis and follow-up of myxomatous mitral valve diseases in dogs (Keene *et al.*, 2019). RLAD possesses high specificity and sensitivity in determining left atrial enlargement (Sanchez Salguero *et al.*, 2018). VLAS and RLAD reference values have not been reported for rats.

Due to the difficulty in obtaining thoracic radiographs at the inspiration peak on account of the high respiration rate in rats (Dias *et al.*, 2021), insufficient clarity of the cardiac silhouette because of the opacity of the cranioventral mediastinum on lateral radiographs and occasional superimposition of the apex of the heart over the diaphragm can adversely affect VHS measurements. Our hypothesis is that with the application of non-ionic contrast material from the tail vein, rather than the cardiac silhouette, the heart

can be evaluated directly as its borders become clear and the CaCV can be unequivocally employed as the site for VHS, VLAS and RLAD value measurement.

The purpose of this study was to reveal any difference between VHS, VLAS and RLAD values obtained from plain and contrast thoracic radiographs from young adult Wistar albino rats (*Rattus Norvegicus*) and to determine the normal values of these radiographic indices.

## Materials and Methods

**Animals:** Approval for the experimental protocol was granted by the Akdeniz University Animal Care Ethics Committee, Antalya, Turkey (no. B.30.2.AKD.0.05.07.00/27). Seventy healthy, young adult intact rats (*Rattus Norvegicus*, Albinus, Wistar) were housed in the Akdeniz University Experimental Research and Application Center (Turkey), in groups of four to six animals (of the same sex), at 50-60% humidity and 20-21°C in a 12-h dark/light cycle. Ad libitum access was permitted to standard rat chow and water. Each rat underwent daily physical examinations throughout the study and no cardiovascular or pulmonary abnormalities (such as murmur, arrhythmia or abnormal respiratory sounds) were determined in any of the rats included in the study.

**Anesthesia protocol:** Radiographs from all rats were obtained under general anesthesia, using the anesthesia protocol described by Dias *et al.* (2021). Anesthesia was induced in an induction chamber by means of 5% isoflurane gas (Aerrane Volatil®, Eczacıbası-Baxter, Istanbul, Turkey) in oxygen at a rate of 2 L/min. Anesthesia was subsequently maintained by 1-3% isoflurane delivered in oxygen at a rate of 1 L/min, using a small face mask and a non-rebreathing circuit. A positive pressure breathing hold was employed solely at the time of radiographic exposure in order to yield an image at the inspiration peak. While a positive pressure breathing hold was employed, care was taken not to cause pulmonary hyperinflation, to preserves the opacity of the CaVC and not to cause excessive caudal displacement of diaphragm. Otherwise, all animals continued breathing spontaneously during which breathing was maintained by all the animals throughout the entire procedure. Venous access was opened from the tail vein under anesthesia for the administration of contrast material.

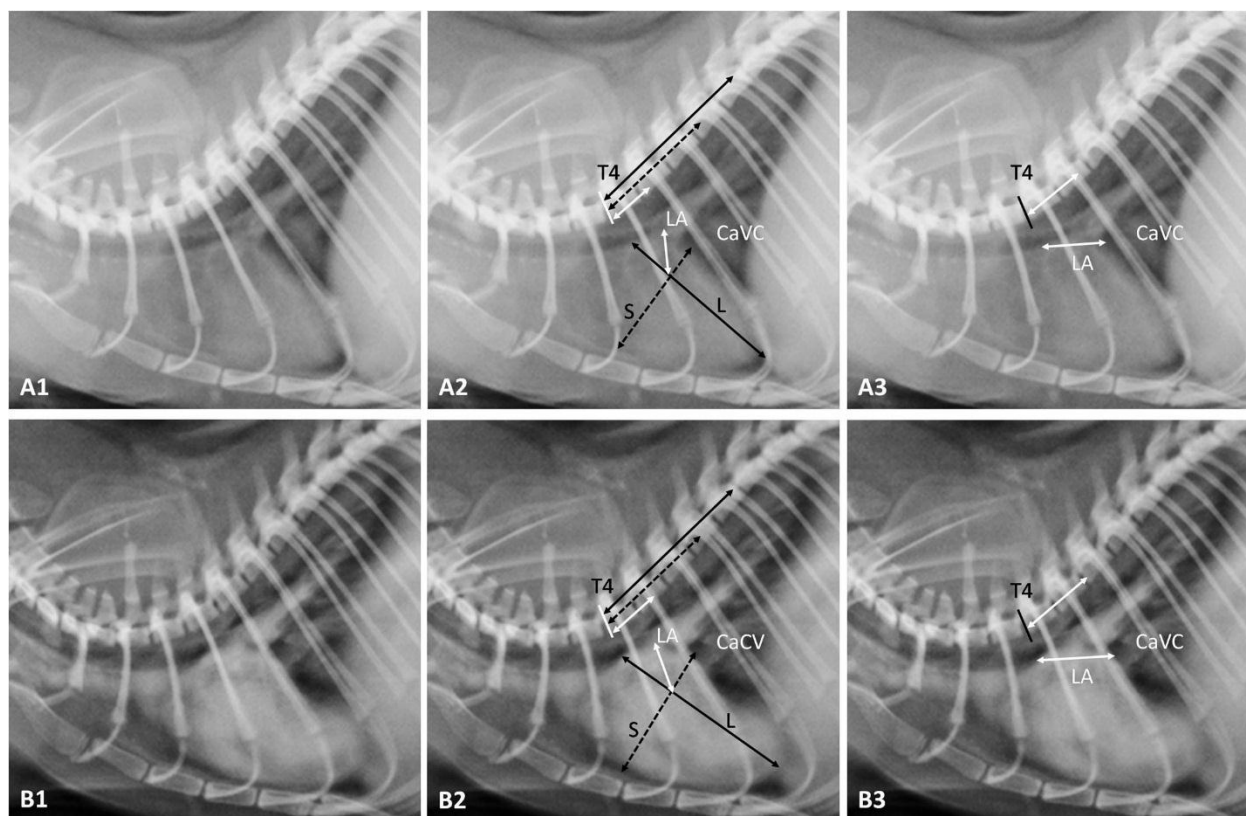
### Thoracic radiography:

**Thoracic plain radiography (Figure 1A1):** Right lateral thoracic radiographs were obtained separately for each animal (X-ray tube: ORIX-65, Ardet®, Istanbul, Turkey. Parameters: 65 kVp, 8 mA, 0.1 s, 30-cm film-focus distance). The rat was positioned in a right lateral recumbency at the center of the x-ray cassette, and the thoracic and pelvic legs were pulled in a cranial and caudal directions, respectively. The beam was then centered at the level of the thorax between the scapulohumeral joint and the last rib.

**Thoracic contrast radiography (Figure 1B1):** Once the cassette had been replaced, exposure was performed following a 0.5 ml bolus injection of non-ionic

iodinated contrast material (300 mg I/ml, Iohexol, Omnipaque®, Opakim, Turkey) using the same radiographic position and factors as for the plain radiography.

Both plain and contrast radiographs were regarded as being of diagnostic quality in case of substantial symmetry/superposition of the ribs and scapulae in addition to widely accessible cardiothoracic structures exhibiting sufficient contrast and pulmonary inflation.



**Figure 1** Plain (A1) and contrast (B2) radiographic studies of thorax in right lateral recumbencies (parameters: 65 kVp, 8 mA, 0.1 s, 30-cm film-focus distance). Example of VHS and RLAD (A2 and B2), and VLAS (A3 and B3) measurements on right lateral plain and contrast views. L: long axis of VHS, S: short axis of VHS, LA: left atrium, T4: fourth thoracic vertebrae, CaVC: caudal vena cava.

A computed radiography reader (FCR Prima T2, FujiFilm®, Tokyo, Japan) was used to transfer the image on the cassette to a digital environment and the images obtained were stored. After being anonymized and randomized, these radiographic images were evaluated by two observers on commercially available computer software (Image Intelligence™, FujiFilm®, Tokyo, Japan). The observers were blinded to each rat's sex, age and body weight. The observers were able to manipulate the images when they considered this necessary, including for altering the window width, level and magnification and radiographic cardiac index measurements were performed. Each observer performed VHS, VLAS and RLAD measurements obtained from plain and contrast radiographs twice, at one-week intervals. Corresponding VHS, VLAS, and RLAD means were calculated for both observers, these being the values employed for statistical analyses.

**Measurements of radiographic cardiac indices:** VHS (Buchanan, 2000), VLAS (Malcom *et al.*, 2018), and RLAD (Sanchez Salguero *et al.*, 2018) from both plain and contrast right lateral radiographs were measured in accordance with their respective published methods. These are described below and also illustrated in Figure 1.

For VHS, the long and short axes of the cardiac silhouette were measured from the right lateral view. The cardiac long axis (L) was defined as the distance between the ventral border of the left main stem bronchus and the most distant ventral contour of the cardiac apex. The cardiac short axis (S) on the same view was determined by measuring the distance from the intersection of the caudal border of the heart silhouette with the dorsal border of the CaVC to the cranial border of the heart silhouette. Commercial computer software was employed to apply a 90-degree rotation between L and S. L and S were then relocated over the thoracic vertebrae from the cranial edge of the fourth thoracic vertebra (T4), parallel to the vertebral column. Next, each length was expressed as the number of thoracic vertebrae (v) to the nearest 0.1v. The sum of the two values was adopted as VHS (Figure 1A2 and B2).

The radiographic images used for VHS were also employed to calculate RLAD values, on the same computer software. A line bisecting the 90° angle at the junction of the VHS L and S axes was extended from there to the radiographic projection of the dorsal edge of the left atrium. The computer software was employed in order to establish a 45° angle between this line and the junction of the L and S axes. This length was then normalized to v beginning from the cranial

edge of the T4 and to the nearest 0.1v, similarly to VHS. This was then employed as the RLAD value (Figure 1A2 and B2). In the event of difficulty in distinguishing the dorsal anatomical margins of the left atrium and the pulmonary veins in this area, the most dorsal aspect of the soft tissue or contrast opacities observed at this level was employed for all calculations.

VLAS was also obtained from the radiographic images employed for the calculation of VHS, and on the same computer software. In the first step, a line was measured from the center of the most ventral aspect of the carina to the most caudal aspect of the left atrium at the junction with the dorsal border of the CaVC. This was then relocated over the thoracic vertebrae beginning from the cranial edge of T4, similarly to VHS. This length was then normalized to v beginning from the cranial edge of T4 and to the nearest 0.1v, similarly to both VHS and RLAD, and was adopted as VLAS for the analyses (Figure 1A3 and B3).

**Statistical analysis:** All statistical analysis was performed on Statistical Package for the Social Sciences version software 22.0 (SPSS Inc., Chicago, IL, USA). Descriptive statistics were generated. Normality of data distribution was evaluated using the Shapiro-Wilk test. No variables were found to be normally distributed and the results were expressed as median and interquartile range (IQR). Wilcoxon's signed rank test was applied to compare pre- and post-contrast material administration values. Correlations between VHS, RLAD and VLAS values obtained from plain and contrast radiographs were calculated using Spearman's rank-order correlation coefficient. Interobserver and intraobserver variabilities for VHS, RLAD and VLAS were evaluated by means of intraclass correlation coefficient (ICC) estimates and 95% confidence intervals (CIs) based on a single rater, absolute agreement, with a two-way random (interobserver) and mixed (intraobserver) effect. ICC values >0.9 were regarded as excellent, 0.75 to 0.9 as good, 0.5 to 0.75 as moderate and <0.5 as poor. Both intraobserver and interobserver variabilities assessed by means of ICC were found to exhibit good to excellent agreement for both radiographic methods

(ICC >0.75) (Koo and Li, 2016). *P* values < 0.05 were considered significant for all analyses.

## Results

The study was performed with 70 healthy rats, 35 male and 35 female, with a median age of 11 weeks (range 8-14) and a median weight of 322.5 g (range 200-455). Median weights were 350 g for the male rats (range 210-455) and 260 g for the females (range 200-335).

No complications associated with anesthesia or contrast material were encountered in any animals and no mortality occurred. Measurement of radiographic cardiac indices was performed in a problem-free manner from both plain and contrast radiographs.

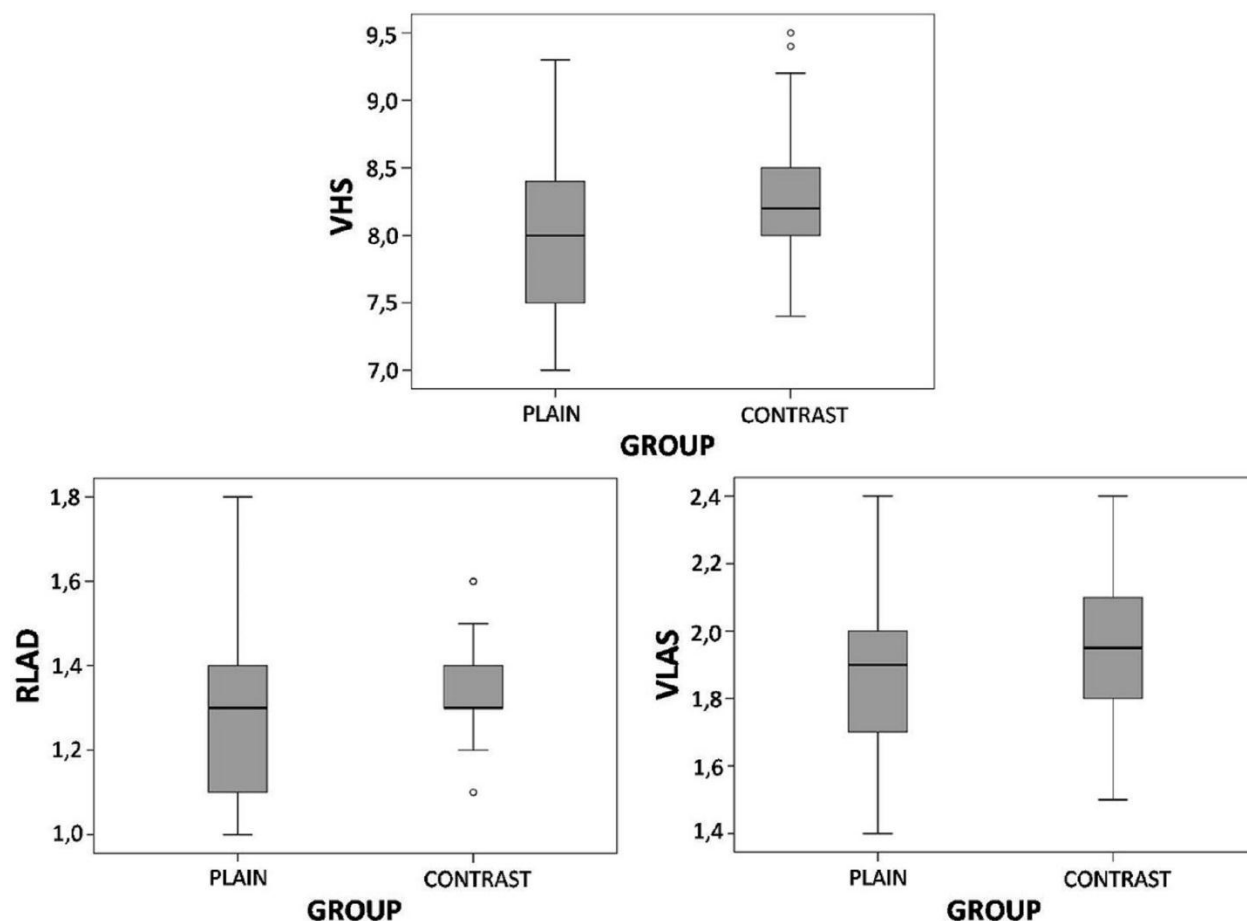
VHS, VLAS and RLAD values obtained from plain and contrast radiographs are summarized in Table 1. Median values and reference ranges for VHS were 8v (7-9.3v) for plain radiographic measurements and 8.2v (7.4-9.5v) for contrast radiographic measurements (*P* < 0.000). Median values and reference ranges for RLAD were 1.3v (1-1.8v) for plain radiographic measurements and 1.3v (1.1-1.6v) for contrast radiographic measurements (*P* < 0.001), and 1.9v (1.4-2.4v) for plain radiographic measurements and 1.95v (1.5-2.4v) for contrast radiographic measurements for VLAS (*P* < 0.000) (Figure 2). Only VHS exhibited a significant gender difference on both plain and contrast radiographs (*P* < 0.02) (Table 2).

No correlation was determined between VHS and RLAD (*r* = 0.07, *P* > 0.05), between VHS and VLAS (*r* = 0.08, *P* > 0.05) or between RLAD and VLAS (*r* = 0.04, *P* > 0.05) in terms of plain radiographic measurements. No correlation was also determined between VHS and RLAD (*r* = -0.10, *P* > 0.05), between VHS and VLAS (*r* = -0.04, *P* > 0.05) or between RLAD and VLAS (*r* = 0.02, *P* > 0.05) in terms of contrast radiographic measurements.

VHS, RLAD and VLAS methods exhibited good intraobserver and interobserver agreement for plain radiographic measurements. Intraobserver and interobserver measurements also revealed excellent agreement for contrast radiographic measurements for all variables (Table 3).

**Table 1** Mean and standard deviation (SD), 95% confidence interval (95% CI) and *P* values of vertebral heart score (VHS), radiographic left atrial dimension (RLAD) and vertebral left atrial size (VLAS) in Wistar rats.

Variable		Mean±SD	95% CI	<i>P</i> value
VHS	Plain	7.97±0.52	7.85-8.1	0.000
	Contrast	8.22±0.41	8.13-8.32	
RLAD	Plain	1.27±0.18	1.23-1.32	0.000
	Contrast	1.34±0.12	1.32-1.37	
VLAS	Plain	1.86±0.23	1.82-1.92	0.001
	Contrast	1.96±0.21	1.91-2	



**Figure 2** Boxplots comparing vertebral heart score (VHS), radiographic left atrial dimension (RLAD) and vertebral left atrial size (VLAS) values from plain and contrast radiographs.

**Table 2** Mean and standart deviation (SD) of vertebral heart score (VHS), radiographic left atrial dimension (RLAD) and vertebral left atrial size (VLAS) for female versus male rats.

Variable		Females (n=35)	Males (n=35)
VHS	Plain	7.85±0.43*	8.11±0.57*
	Contrast	8.07±0.32*	8.31±0.46*
RLAD	Plain	1.24±0.19	1.29±0.16
	Contrast	1.32±0.12	1.34±0.11
LVAS	Plain	1.85±0.18	1.9±0.24
	Contrast	1.93±0.17	1.97±0.23

\*Superscript within the same row significantly differ ( $P < 0.05$ )

**Table 3** Intraobserver and interobserver agreement for vertebral heart score (VHS), vertebral left atrial size (VLAS) and radiographic left atrial dimension (RLAD) in Wistar rats

Variable		Intraobserver agreement			Interobserver agreement		
		ICC	95% CI	P value	ICC	95% CI	P value
VHS	Plain	0.81	0.51-0.92	<0.001	0.75	0.36-0.90	< 0.05
	Contrast	0.97	0.92-0.99	<0.001	0.96	0.90-0.98	<0.001
RLAD	Plain	0.81	0.52-0.92	<0.001	0.73	0.32-0.89	< 0.005
	Contrast	0.96	0.89-0.98	<0.001	0.92	0.79-0.97	<0.001
LVAS	Plain	0.88	0.69-0.95	<0.001	0.85	0.63-0.94	<0.001
	Contrast	0.98	0.94-0.99	<0.001	0.91	0.78-0.96	<0.001

Abbreviations: ICC, intraclass correlation coefficient; CI, confidence interval.

## Discussion

The purpose of this study was to compare VHS, RLAD and VLAS values obtained from plain and contrast right lateral thoracic radiographs from 70 healthy albino Wistar rats and to determine the normal values for these radiographic cardiac indices.

VHS is a reliable index for evaluating cardiac enlargement associated with eccentric hypertrophy, particularly due to volume overload, in patients with suspected heart disease based on measurements of cardiac silhouette dimensions from thoracic radiography (Buchanan and Bucheler, 1995; Buchanan, 2000). This radiographic cardiac index is based on a

good correlation between heart size and the length of the thoracic vertebral body. (Sanchez Salguero *et al.*, 2018). A slight variation was subsequently developed by measuring the short axis from the dorsal border of the CaCV order to include the left atrial body at lateral thoracic radiography (Buchanan, 2000). Since the size of the left atrium was to be evaluated with VLAS and RLAD methods in this study, VHS measurements were performed on the basis of that variation.

VHS measurement has been shown to be affected by the cardiac cycle and respiration phases (Oliver *et al.*, 2015, Brown *et al.*, 2020). Rats possess a high respiration rate and cardiac cycle. However, rat intubation is both difficult and is not performed in veterinary clinical practice and it may therefore not be possible to obtain thoracic radiographs in the inspiration phase in rats if the animals are not intubated (Dias *et al.*, 2021). Additionally, similarly to rabbits (Pariatus, 2009), due to soft tissues such as the thymus and intrathoracic fat, the cranioventral mediastinum in rats exhibits soft tissue opacity and this may adversely affect VHS measurement since it will blur the cranial margin of the heart. In a study conducted in Wistar rats, it has been shown that thymus weight and its total volume reached the highest values in between 2 and 3 month old animals, gradually decreasing from the 3<sup>rd</sup> to 6<sup>th</sup> month and remaining constant after the 6<sup>th</sup> month (Brelinska *et al.* 2008). In the present study, the prominence of the cranial margin of the heart on right lateral thoracic radiographs was corrected with positive pressure breath-holding during radiographic exposure, in such a way as to allow measurements on plain radiographs and respiratory movement-related (secondary) motion artifact was minimized. VHS is a radiographic measurement method that evaluates the dimension of the cardiac silhouette in an objective manner. High values can thus be obtained in VHS measurements obtained from plain radiography in the presence of excessive pericardial fat or pericardial effusion. However, since the heart can be evaluated directly using contrast thoracic radiography, cardiomegalies deriving from cardiomyopathy can be diagnosed. In contrast to plain radiography, the heart can be evaluated directly with its clear margins, rather than the cardiac silhouette, at contrast radiography in the present study. Additionally, the dorsal border of the CaCV used as the measurement site for VHS, VLAS and RLAD values was clearer at contrast radiography. Similar to VLAS and RLAD values, a statistically significant difference was observed between VHS values obtained with plain and contrast radiography ( $P < 0.000$ ).

Dias *et al.* (2021), and Dogan *et al.* (2022), also reported VHS values in healthy rats. However, the VHS values in the present research were higher than in those two studies. Breed-associated variations affect VHS values and VHS values in dogs have been shown to be breed-specific (Puccinelli *et al.*, 2012; Bodh *et al.* 2016; Bagardi *et al.*, 2021). The VHS values in this study were different from VHS values reported in Dias *et al.*'s (2021), study involving Sprague-Dawley rats. Those two studies were performed in rats of similar age and body weight. However, the difference in VHS values suggests that this radiographic cardiac index may be

breed-specific. Doğan *et al.* (2022), obtained VHS values from Wistar rats (7.34v) but their results were different, which may be attributable to their measuring VHS using the uncommon method described by Ljubica *et al.* (2007), in 10-month-old male rats irrespective of the respiration phases. Age is an important factor for VHS (Gunther-Harrington *et al.*, 2021). However, both male and female rats are considered to reach sexual maturity at 4.5 weeks of age. Additionally, average body weight is 267-500 g for adult male rats and 225-325 g for adult female rats (Lennox and Bauck, 2012). Both median age (11 weeks) and median body weight (322.5 g; 350 g for male rats and 260 g for female rats) in the present study were similar to Dias *et al.*'s (2021), study. As they pointed out, considering the sexual maturation age and adult body weight, the radiographic cardiac indices obtained in this study are considered representative of adult rats. The absence of physeal lines at the vertebrae in all thoracic radiographies was an indication of bone maturity (Figure 1). The effect of the age factor on VHS values was beyond the scope of this study. Further studies are now needed to determine how breed-associated variations and age may affect VHS in rats. Similarly to Dias *et al.* (2021), we determined a gender difference in terms of VHS values obtained from both plain and contrast radiography ( $P < 0.02$ ), with higher values being determined in male rats compared to females (Table 2).

Left atrium size has been shown to be capable of being measured objectively in dogs and VLAS and RLAD can be used in the radiographic diagnosis of myxomatous mitral valve disease (Malcom *et al.*, 2018; Stepien *et al.*, 2020; Mikawa *et al.*, 2020; Lam *et al.*, 2021). VLAS and RLAD methods are positively correlated with echocardiographically-derived left atrial (LA)-to-aortic root (Ao) ratio values in dogs (Lam *et al.*, 2021). VLAS  $\geq 2.5v$  exhibits 87% sensitivity and 67% specificity for left atrium enlargement (LA/Ao  $\geq 1.6$ ) (Malcom *et al.*, 2018), while RLAD  $\geq 1.8v$  exhibits 93.5% specificity and 96.8% sensitivity (Sanchez Salguero *et al.*, 2018). Further studies are needed to compare the relationship of these two radiological indices with the echocardiographic dimension of the left atrium in rats. VLAS median values and reference intervals of 2.1v (1.8-2.3v) (Malcom *et al.*, 2018) and 1.9v (1.4-2.2v) (Vezzosi *et al.*, 2020) have been reported for healthy dogs. Similar to VHS, VLAS is also breed-specific in dogs. Median VLAS values for Maltese dogs are 2v (1.8-2.1v) (Baisan and Vulpe, 2021), compared to 1.8v (1.3-2.1v) (Puccinelli *et al.*, 2021) for Chihuahuas and 1.79v (1.68-1.9v) for Cavalier King Charles Spaniels (Bagardi *et al.*, 2021). The VLAS values obtained from both plain and contrast radiography in the present study were more compatible with those reported by Vezzosi *et al.*, (2020), and in agreement with their study, we determined no effect of gender on VLAS. While positive correlation between VLAS and VHS has been determined in dogs (Vezzosi *et al.*, 2020; Baisan and Vulpe, 2021), no correlation was observed between VLAS or RLAD and VHS on either plain or contrast radiographs in the present study.

The RLAD values obtained from plain and contrast radiography in the present study were higher than those obtained by Lam *et al.* (2021), and Bagardi *et al.*

(2021), from healthy dogs or dogs without left atrial enlargement ( $1.22 \pm 0.24$  and  $1.2 \pm 0.24$ , respectively) but lower than those reported by Sanchez Salguero *et al.* (2018) ( $1.41 \pm 0.23$ ). Consistent with Bagardi *et al.* (2021), our results show that gender has no effect on RLAD in Wistar albino rats.

Another factor affecting VHS is interobserver variability (Hansson *et al.*, 2005; Boswood *et al.*, 2000). The excellent agreement in intra- and interobserver variability for cardiac indices obtained from contrast radiography shows that this technique, which is easy and uncomplicated, is more effective than plain radiography in the direct quantitative evaluation of heart and left atrium dimensions.

In conclusion, this study presents reference values for VHS, VLAS and RLAD obtained from plain and contrast right lateral thoracic radiographs from healthy Wistar albino rats. Further studies are now needed to determine whether VHS obtained from contrast radiography in rats can be used in the diagnosis of cardiomegaly originating from cardiomyopathies and whether VLAS and RLAD can be employed in the diagnosis of left atrial enlargement. The VHS, RLAD and VLAS obtained from Wistar albino rats in this study can serve as a reference baseline both by veterinarians and in experimental studies.

### Acknowledgements

This research received no grant from any funding agency/sector. We declare that there is no conflict of interest with any financial organization regarding the material discussed in the manuscript.

### References

- Bagardi M, Locatelli C, Manfredi M, Bassi J, Spediacci C, Ghilardi S, Zani DD and Brambilla PG 2021. Breed-specific vertebral heart score, vertebral left atrial size, and radiographic left atrial dimension in Cavalier King Charles Spaniels: reference interval study. *Vet Radiol Ultrasound*. doi: 10.1111/vru.13036, "in press".
- Baisan RA and Vulpe V 2021. Vertebral heart size and vertebral left atrial size reference ranges in healthy Maltese dogs. *Vet Radiol Ultrasound*. doi: 10.1111/vru.13027, "in press".
- Black PA, Marshall C, Seyfried AW and Bartin AM 2011. Cardiac assessment of African hedgehogs (*Atelerix albiventris*). *J Zoo Wildlife Med.* 42: 49-53.
- Bodh D, Hoque M, Saxena AC, Gugjoo MB, Bist D and Chaudhary JK 2016. Vertebral scale system to measure heart size in thoracic radiographs of Indian Spitz, Labrador retriever and Mongrel dogs. *Vet World.* 9: 371-376.
- Brelinska R, Malendowicz LK, Malinska A and Kowalska K 2008. Characteristics of age-related changes in rats thymus: morphometric analysis and epithelial cell network in various thymic compartments. *Biogerontology.* 9: 93-108.
- Buchanan JW and Bucheler J 1995. Vertebral scale system to measure canine heart size in radiographs. *J Am Vet Med Assoc.* 206: 194-199.
- Buchanan JW 2000. Vertebral scale system to measure heart size in radiographs. *Vet Clin North Am Small Anim Pract.* 30: 373-393.
- de Moura CR, das Neves Diniz A, da Silva Moura L, Sousa FCA, Baltazar PI, Freire LD, Guerra PC, de Souza JM, Giglio RF, Pessoa TG, de Sa RP and Alves FR 2015. Cardiothoracic ratio and vertebral heart scale in clinically normal black-rumped agoutis (*Dasyprocta prymnolopha*, Wagler 1831). *J Zoo Wildlife Med.* 46: 314-319.
- Dias S, Anselmi C, Casanova M, Planellas M, Martorell J 2017. Clinical and pathological findings in 2 rats (*Rattus norvegicus*) with dilated cardiomyopathy. *J Exot Pet Med.* 26: 205-212.
- Dias S, Anselmi C, Espada Y, Martorell J 2021. Vertebral heart score to evaluate cardiac size in thoracic radiographs of 124 healthy rats (*Rattus norvegicus*). *Vet Radiol Ultrasound.* 6: 294-401.
- Dickson KV, Davies CW, Routh A, Killick R and Barbon AR 2016. Radiographic cardiac silhouette measurement in captive livingstone's fruit bats (*Pteropus livingstonii*). *J Zoo Wildl Med.* 47: 963-969.
- Dogan E, Okur S, Hayirli A and Okumus Z. Vertebral heart score and cardiothoracic ratio in Wistar rats. *Ankara Univ Vet Fak Derg.* doi: 10.33988/auvfd.905135, "in press".
- Doss GA, Mans C, Hoey S, Di Girolamo N, Stepien RL and Waller KR 2017. Vertebral heart size in chinchillas (*Chinchilla lanigera*) using radiography and CT. *J Small Anim Pract.* 58: 714-719.
- Garcia EB, Eshar D, Thomason JD, Harkin KR and Biller D 2016. Cardiac assessment of zoo-kept, black-tailed prairie dogs (*Cynomys ludovicianus*) anesthetized with isoflurane. *J Zoo Wildl Med.* 47: 955-962.
- Gunther-Harington C, Sharpe AN, Vernau KM, Ueda Y, Montgomery EA, Surmick JD, Fernandez N, Ontiveros E, Walker AL and Stern JA 2021. Reference intervals for radiographic, echocardiographic and N-terminal pro B-type natriuretic peptide values in healthy kittens. *J Feline Med Surg.* 23: 293-301.
- Hansson K, Häggström J, Kvart C and Lord P 2005. Interobserver variability of vertebral heart size measurements in dogs with normal and enlarged hearts. *Vet Radiol Ultrasound.* 46: 122-130.
- Keene BW, Atkins CE, Bonagura JD, Fox PR, Haggstrom J, Fuentes VL, Oyama MA, Stepien R and Uechi M 2019. ACVIM consensus guidelines for the diagnosis and treatment of myxomatous mitral valve disease in dogs. *J Vet Intern Med.* 33: 1127-1140.
- Koo TK and Li MY 2016. A Guideline of Selecting and Reporting Intraclass Correlation Coefficients for Reliability Research. *J Chiropr Med.* 15: 155-163.
- Lam C, Gavaghan BJ and Meyers FE 2021. Radiographic quantification of left atrial size in dogs with myxomatous mitral valve disease. *J Vet Intern Med.* 35: 747-754.
- Lamb CR, Tyler M, Boswood A, Skelly BJ and Cain M 2000. Assessment of the value of the vertebral heart scale in the radiographic diagnosis of cardiac disease in dogs. *Vet Rec.* 146: 687-690.
- Lennox AM and Bauck L 2012. Basic anatomy, physiology, husbandry, and clinical techniques in small rodents. In: *Ferrets, Rabbits, and Rodents - Clinical Medicine and Surgery*. 3<sup>rd</sup> ed. Quesenberry KE and Carpenter JW (eds). St. Louis, Missouri: Elsevier. 339-353.
- Ljubica SK, Krstic N and Trailovic RD 2007. Comparison of three methods of measuring vertebral heart size in German shepherd dogs. *Acta Veterinaria (Beograd).* 57: 133-141.
- Litster A and Buchanan JW 2000. Vertebral scale system to measure heart size in radiographs of cats. *J Am Vet Med Assoc.* 216: 210-214.
- Malcom EL, Visser LC, Phillips KL and Johnson LR 2018. Diagnostic value of vertebral left atrial size as determined from thoracic radiographs for assessment of left atrial size in dogs with myxomatous mitral valve disease. *J Am Vet Med Assoc.* 253: 1038-1054.
- McInnes EF 2012. Wistar and Sprague-Dawley rats. In: *Background Lesions in Laboratory Animals A Color Atlas*. 1<sup>st</sup> ed. McInnes EF (ed). St. Louis, Missouri: Elsevier. 17.
- Mikawa S, Nagakawa M, Ogi H, Akabane R, Koyama Y and Sakatani A 2020. Use of vertebral left atrial size for staging

- of dogs with myxomatous valve disease. *J Vet Cardiol.* 30: 92-99.
- Onuma M, Ono S, Ishida T, Shibuya H and Sato T 2010. Radiographic measurement of cardiac size in 27 rabbits. *J Vet Med Sci.* 72: 529-531.
- Orcutt CJ and Malakoff RL 2020. Cardiovascular disease. In: *Ferrets, Rabbits and Rodents: Clinical medicine and surgery.* 4<sup>th</sup> ed. Quesenberry KE, Orcutt CJ, Mans C and Carpenter JW (eds). St. Louis, Missouri: Elsevier 250-257.
- Pariaut R 2009. Cardiovascular physiology and diseases of the rabbit. *Vet Clin Nort Am Exot Anim Pract.* 12: 135-144.
- Puccinelli C, Citi S, Vezzosi T, Garibaldi S and Tognetti R 2021. A radiographic study of breed-specific vertebral heart score and vertebral left atrial size in Chihuahuas. *Vet Radiol Ultrasonoud.* 62: 20-26.
- Sanchez Salguero X, Prandi D, Labres-Diaz F, Manzanilla GE and Bussadori C 2018. A radiographic measurement of left artial size in dogs. *Ir Vet J.* 71: 25.
- Sharp P and Villano J 2021. Important biological features. In: *The Laboratory Rat.* 2<sup>nd</sup> ed. Sharp P and Villano J, (eds) Boca Raton: CRC Press.1.
- Stepien RL, Benson KG and Forrest LJ 1999. Radiographic measurement of cardiac size in normal ferrets. *Vet Radiol Ultrasound.* 40: 606-610.
- Stepien RL, Rak MB and Blume LM 2020. Use of radiographic measurements to diagnose stage B2 preclinical myxomatous mitral valve disease in dogs. *J Am Vet Med Assoc.* 256: 1129-1136.
- Vezzosi T, Puccinelli C, Tognetti R, Pelligra T and Citi S 2020. Radiographic vertebral left atrial size: A reference interval study in healty adult dogs. *Vet Radiol Ultrasound.* 61: 507-511.
- Wagner RA 2009. Ferret cardiolgy. *Vet Clin Nort Am Exot Anim Pract.* 12: 115-114.