

# Biocompatibility and postoperative complications of different subcutaneous suturing methods in cats undergoing ovariohysterectomy by midline incision

Ameer Hamza Rabbani<sup>1\*</sup> Yasir Razzaq Khan<sup>2</sup> Omer Naseer<sup>2</sup> Qudratullah<sup>1</sup>

Hafiz Muhammad Safwan<sup>1</sup> Abdul Waheed<sup>3</sup> Ahmad Ali<sup>2</sup> Muhammad Waqas<sup>4</sup>

## Abstract

This study evaluated the clinical efficacy of three different closure techniques on postoperative pain and surgical complications in cats. It was a randomized, clinical trial conducted at different veterinary clinics in Lahore, Pakistan. Forty-eight (n = 48) cats underwent midline incision for ovariohysterectomy and were assigned to one of three Groups representing different closure methods. In Group A, continuous subcutaneous apposition was carried out with buried knots and intermittent tacking to the rectus fascia (Group A, n=16) in a quilting fashion to obliterate dead space using Polyglactin 910 (Vicryl™) USP 3-0 suture, superimposed by horizontal mattress pattern employing Polypropylene (Prolene™) USP 2-0. Individuals of Group B were subjected to continuous subcutaneous apposition with buried knots without incorporating any fascia (Group B, n=16) by means of Polyglactin 910 (Vicryl™) USP 3-0 suture overlaid with horizontal mattress sutures pattern via Polypropylene (Prolene™) USP 2-0. While in Group C, no subcutaneous closure was performed and edges of skin were sutured in a horizontal mattress pattern (Group C, n=16). Incidence of post-operative complications such as seroma, erythema, dehiscence and exudative discharge were rare in Group A due to subcutaneous attachment with muscle sheet. Moreover, mechanical threshold to peri-incisional stimulation was significantly improved in Group A as well. However, pain and discomfort scores according to feline composite pain scale were comparable across all cases at 2<sup>nd</sup>, 8<sup>th</sup> and 14<sup>th</sup> day after surgery. In conclusion, suturing subcutaneous tissues in a quilting fashion reduced seroma formation and mechanical pain threshold in cats undergoing abdominal closure during ovariohysterectomy.

---

**Keywords:** Continuous subcutaneous apposition, Ovariohysterectomy, Polyglactin 910 suture, Post-operative complications, Post-operative pain

---

<sup>1</sup>Department of Surgery, Faculty of Veterinary Sciences, Cholistan University of Veterinary and Animal Sciences, Bahawalpur, Pakistan

<sup>2</sup>Department of Medicine, Faculty of Veterinary Sciences, Cholistan University of Veterinary and Animal Sciences, Bahawalpur, Pakistan

<sup>3</sup>Institute of continuing education and extension, Cholistan University of Veterinary and Animal Sciences, Bahawalpur, Pakistan

<sup>4</sup>In charge Civil Veterinary Dispensary, Zafarke kot Radha Kishen district Kasur, Pakistan

\*Correspondence: ameerhamzarabbani@cuvas.edu.pk (A. H. Rabbani)

Received December 2, 2020.

Accepted May 24, 2021.

doi: <https://doi.org/10.14456/tjvm.2021.69>

## Introduction

Ovariohysterectomy (Spaying) in domesticated cats is most commonly performed through midline laparotomy (Gates *et al.*, 2020). Healing of these surgical incisions often gets delayed due to a myriad of complications. Such phenomenon may be attributed to utter disregard of clients in following postoperative guidelines or the inquisitive nature of felines to abuse any sutures tagged onto their skin (Stavisky and Brennan, 2020). This presents a vexing conundrum as neglect may lead to serious self-manipulations of surgical site by veterinary patient (Misk and EL-sherry, 2020). Postoperative seroma has been frequently observed as a common complication after midline incision ovariohysterectomy in domestic cats (Lopez *et al.*, 2020). Stretching of the skin due to excessive fluid accumulation results in patient discomfort and an increased probability for post-operative infections (Ouldamer *et al.*, 2016). Surgical site infections (SSI) and dehiscence have reportedly emerged as a sequelae to disruption of lymphatic drainage and introduction of bacterial infection during extensive surgical dissection, effectively creating dead space between tissue planes (Read *et al.*, 2017). This accumulation of fluid as a consequence of inflammation or impaired lymphatics causes uneasiness for clients as well as the patients (Ouldamer *et al.*, 2016). Pain and discomfort at surgical site, provokes the patient to scratch and harass the suture line (Travis *et al.*, 2018).

Simple interrupted pattern that was once used has been replaced by horizontal mattress suture pattern applied using Polpropylene USP 2-0 (Özer *et al.*, 2017). This pattern provided adequate security in terms of incisional apposition as suture was adequately anchored on both sides. It was quite difficult to pull on them with teeth or nails as knots were tucked under the everted bulge of tissue (Özer *et al.*, 2017). Suture patterns that run parallel to the incision line incorporate greater surface area of tissue effectively distributing tension across the entire incision causing less post-operative pain (Kumar, 2020). Yet incidence of seroma was quite high in such cases. As this methodology failed to obliterate the undermined dead space and created percutaneous tracts which were attributed to higher incidence of infections (Hendrickson, 2018). Following this rationale, continuous sub-cutaneous suture pattern with buried knots are frequently being employed for closure of subcutaneous tissue overlaid with tissue glue or horizontal mattress pattern for skin closure to mitigate post-operative seroma and self-mutilation in veterinary practices (Gouletsou *et al.*, 2020; Marsidi *et al.*, 2020). Continuous sub-cutaneous pattern thwarted formation of percutaneous suture tracts responsible for severe postoperative wound infections (Travis *et al.*, 2018). However, seroma formation in active cats persisted since space between subcutaneous tissue and muscular sheets continued to exist (Lopez *et al.*, 2020).

Recently it has been observed that post-operative seroma caused due to creation of dead spaces during surgical undermining may be resolved by tacking the subcutaneous tissues to the rectus fascia during closure (Travis *et al.*, 2018). This technique employed a quilting pattern to suture subcutaneous and muscular tissues

while obliterating any dead spaces between them (Scharner *et al.*, 2018). In dogs this modified technique of subcutaneous suture pattern has been successful in controlling incidences of seroma and postoperative pain (Travis *et al.*, 2018). This technique has been found efficacious in humans as well during repair of large ventral hernias (Alhussini *et al.*, 2019), single-port laparoscopic surgery (Chang *et al.*, 2018), breast reconstructions (Hart *et al.*, 2017) and mastectomies (Ouldamer *et al.*, 2016). However, it has been postulated that study outcomes in cats may vary due to lower tensile strength and collateral blood supply of subcutaneous tissue causing decreased tissue perfusion in acute phases of wound healing (Gouletsou *et al.*, 2020). Regeneration of any non-infected wound is predicated upon proliferation of fibroblast, capillary, and epithelial cells. The collagen meshwork laid underneath the presumed epithelial lining continues to contract as to allow the margins of the defect to come closer to each other (Zellner *et al.*, 2016). Such phenomenon creates stresses in the tissue. In cases where large defects are present connective tissue is created to fill the space thereby causing scarring (Miller *et al.*, 2017). Lesser the space is, between the tissues after closure of incision fewer the cells are required to regenerate and assist in healing (Panayi *et al.*, 2020). Buried continuous sub-cutaneous suture pattern along with quilting of abdominal muscles has been known to create a cosmetic look as the incidence of scarring was greatly reduced (Kitshoff *et al.*, 2018). Husslein *et al.* (2014) reported that incisional appearance and incidence of seroma were significantly improved in women that underwent cesarean section closure in a similar fashion. However, risk of hematoma was slightly increased.

Buried continuous sub-cutaneous suture pattern with quilting comes very handy when dealing with aggressive cats which are not very keen about suture removal (Papazoglou *et al.*, 2010). As the suture materials that are often used for application of such patterns are of absorbable nature. By using this technique, edges of the skin are evenly apposed thereby promoting hasty recovery. However, employing this technique during surgery is cumbersome and requires greater tissue manipulation thereby causing micro sites of tissue trauma, hyperemia and in certain severe cases post-operative hematoma (Lopez *et al.*, 2020). Furthermore, a lot of material has to be left in-situ leading to greater tissue reaction and may even act as a nidus for infection (Lopez *et al.*, 2020; Zellner *et al.*, 2016). Therefore, type of suture material being used has a huge impact on the quality of closure obtained by this technique (Fortelny, 2018). Polyglactin 910 USP 3-0 (Vicryl; Ethicon) is a synthetic absorbable braided suture that boasts adequate tensile strength and is relatively pliable as compared to catgut. Being non capillary and coated, it has a low coefficient of friction despite it being much cheaper than other synthetic absorbable mono filaments of similar cadre. These characteristics make it quite suitable for suturing delicate soft tissues. Moreover, tissue drag has proven to be significantly lesser in research models when compared with chromic cat gut suture of comparable size (Maftai *et al.*, 2019).

The objective of this study was to compare the effects of three different methods of wound closure by evaluating post-operative wound complications in domesticated cats, severity of postoperative pain, incidence of dehiscence, incisional appearance, and incisional closure time while employing Polyglactin 910 (Vicryl™) suture material.

### Materials and Methods

**Inclusion and selection of animals:** This study involved 48 client-owned cats presented at two different private veterinary practices in Lahore, Pakistan. Same surgeon did all the procedures involved in the study. Each cat enrolled in the study was aged to be less than 2 years old. It was assured that none of the cats had received any antibiotic or anti-inflammatory drugs in the past week prior to the study and was determined to be free of skin diseases after a thorough general examination. All owners gave informed consent prior to their cats being involved in the study.

**Anesthetic protocol:** All cats were pre medicated using Tramadol (2mg/kg) prior to anesthetic induction using a combination of Ketamine (Ketarol 50 mg/ml, Global Pharmaceuticals) at 6.6 mg/kg and Xylazine (Xylaz 20 mg/ml, Farvet) at 2.2 mg/kg intramuscularly. Anesthesia was maintained using isoflurane (Forane, Baxter Healthcare Corporation).

**Surgical Procedure:** Hair at the surgical site were clipped using a no. 40 clipper blade and skin was surgically scrubbed with a 4% chlorhexidine gluconate solution (LP-Ion; Lahore Pharma, Pakistan), followed by isopropyl alcohol (70%). A 1.5 to 2.5cm incision was made across ventral midline, fat and fascia were dissected free from linea alba whereby a stab incision was made to approach the inner abdomen hemostatically. The suture material used to ligate ovarian and uterine pedicles was Polyglactin 910

(Vicryl™) 2-0 suture while linea alba was everted with a horizontal mattress interrupted pattern using Polyglactin 910 (Vicryl™) 2-0 suture whereas Polyglactin 910 (Vicryl™) 3-0 suture material was employed for the closure of subcutaneous layer. When the animal was deemed to be normotensive, Meloxicam (Diclostar, Star Laboratories) was administered as a postoperative analgesic at a dose rate of 0.2 mg/kg body weight subcutaneously. Ceftriaxone sodium was injected 50 mg/kg intramuscularly for three days after surgery. Mercurochrome solution was used as an antiseptic at surgical site until complete apposition of skin edges.

**Techniques for Wound closure:** Cats were randomly assigned into three groups namely Group A, B and C.

Group A: Continuous Subcutaneous apposition with buried knots and intermittent tacking to the rectus fasciae (Group A, n=16) with Polyglactin 910 (Vicryl™) USP 3-0 suture, superimposed by horizontal mattress sutures pattern employing Polypropylene USP 2-0.

Group B: Continuous Subcutaneous apposition with buried knots without incorporating any fasciae (Group B, n=16) with Polyglactin 910 (Vicryl™) USP 3-0 suture overlaid with horizontal mattress sutures pattern employing Polypropylene USP 2-0.

Group C: no subcutaneous closure, only horizontal mattress suture pattern on skin (Group C, n=16). Polypropylene USP 2-0 on a reverse cutting needle was used.

**Scoring of incision for post-operative changes:** A trained individual other than the one who performed the surgery, scored the appearance of skin at 2<sup>nd</sup>, 8<sup>th</sup> and 14<sup>th</sup> day post operation. Scoring was predicated on objective assessment of wound healing and degree of scarring. Dehiscence, swelling, discharge and erythema were quantitatively scored (Table 1) using a previously established scoring system published in prior studies (Smeak, 1992).

**Table 1** Criteria used to score appearance of wounds

Sr.No.	Outcome	Score			
		0	1	2	3
1	Swelling (mm)	None	0-2 mm	2-5 mm	5 mm
2	Erythema (mm)	None	0-2 mm	2-5 mm	5 mm
3	Dehiscence (% of suture line)	None	0-20%	20%-50%	50%
4	Discharge	None	Serosanguinous	Purulent	

**Assessment of Pain:** Peri-incisional evaluation of pain was performed to determine mechanical threshold by a force algometer equipped with a 1cm<sup>2</sup> diameter probe head (Pain Test™ FPX, Wagner Instruments USA). Observations were recorded at 2<sup>nd</sup>, 8<sup>th</sup> and 14<sup>th</sup> day post-surgery. Furthermore, objective assessment of pain was made by using feline composite pain scale (FCPS) at similar durations of time post-surgery.

**Scoring for postoperative scarification:** A modified visual analog scale was employed to quantify incisional appearance using a 0 to 100-mm line anchored at each end by descriptors. Degree of exudation, dehiscence and inflammation, were graded at 14<sup>th</sup> day of surgery to assess post-surgical healing by

visual examination of surgical site as described by Lopez *et al.* (2020).

**Ethical considerations:** This study was conducted on clinical patients after informed consent was obtained from their owners. Experimental design conformed to the guidelines outlined by Pakistan's Prevention of Cruelty to Animals Act (1890) and is in compliance with the Guide for the Care and Use of Laboratory Animals in Research and Teaching.

**Statistical methods:** Data are presented as mean  $\pm$  SEM and differences between three treatment groups were analyzed by means of GraphPad Prism (Ver. 8.4.3 for Windows; GraphPad Software, La Jolla California,

USA). In case of normal continuous data one-way ANOVA test was employed while a Kruskal Wallis equality of populations rank was used when data were not normal. Post hoc two-group comparisons were made by using a Tukey test.

## Results

48 cats were inducted into this study whereby they were divided equally into three groups with each having 16 individual surgical patients. Individuals included in this study were comparable in terms of age,

weight, and length of surgical incision. Incision wounds were scored postoperatively in terms of swelling, erythema, dehiscence and discharge at 2<sup>nd</sup>, 8<sup>th</sup> and 14<sup>th</sup> day after surgery. On 2<sup>nd</sup> day, incisional wounds in Group A (Subcutaneous with tacking, Vicryl™) demonstrated least number of complications than either Group B (Subcutaneous without tacking, Vicryl™) or Group C (No subcutaneous suturing). Erythema scores were significantly lower in Group A than either Group B ( $P = 0.0034$ ) or Group C ( $P < 0.0001$ ) (Table 2).

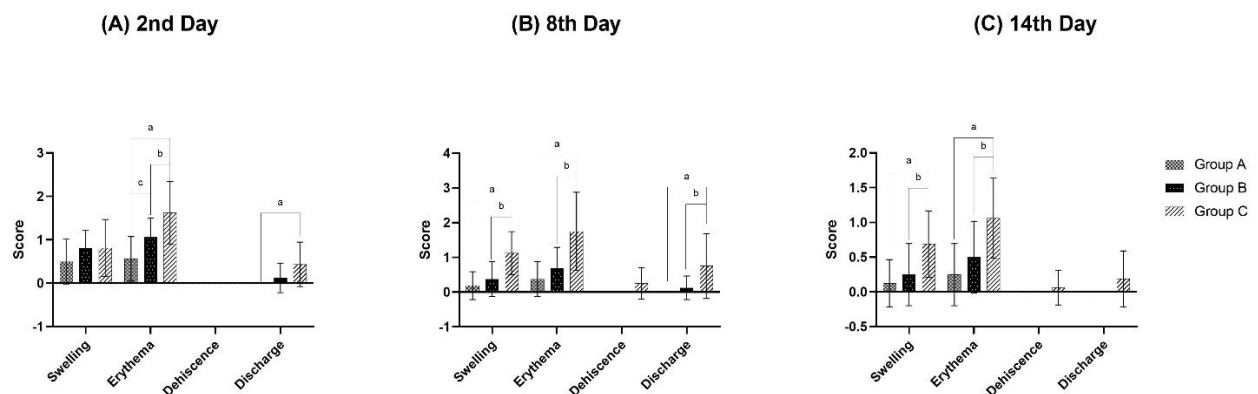
**Table 2** Mean score of swelling, erythema, dehiscence and discharge for different closure techniques at times 2<sup>nd</sup>, 8<sup>th</sup> and 14<sup>th</sup> day after surgery for assessment of post-operative wound.

Sr. No.	Outcome	Group A	Group B	Group C
<b>2d</b>				
1	Swelling	0.5±0.51 <sup>a</sup>	0.81±0.40 <sup>a</sup>	0.81±0.65 <sup>a</sup>
2	Erythema	0.56±0.51 <sup>c</sup>	1.06±0.44 <sup>b</sup>	1.62±0.71 <sup>a</sup>
3	Dehiscence	0 <sup>a</sup>	0 <sup>a</sup>	0 <sup>a</sup>
4	Discharge	0 <sup>b</sup>	0.12±0.34 <sup>b</sup>	0.43±0.51 <sup>a</sup>
5	Composite	1.0625 <sup>b</sup>	2 <sup>b</sup>	2.875 <sup>a</sup>
<b>8d</b>				
1	Swelling	0.18±0.40 <sup>b</sup>	0.37±0.5 <sup>b</sup>	1.12±0.61 <sup>a</sup>
2	Erythema	0.37±0.5 <sup>b</sup>	0.68±0.60 <sup>b</sup>	1.75±1.12 <sup>a</sup>
3	Dehiscence	0 <sup>a</sup>	0 <sup>a</sup>	0.25±0.44 <sup>a</sup>
4	Discharge	0 <sup>c</sup>	0.12±0.34 <sup>b</sup>	0.75±0.93 <sup>a</sup>
5	Composite	0.5625 <sup>b</sup>	1.1875 <sup>b</sup>	3.875 <sup>a</sup>
<b>14d</b>				
1	Swelling	0.125±0.34 <sup>b</sup>	0.25±0.44 <sup>b</sup>	0.68±0.47 <sup>a</sup>
2	Erythema	0.25±0.44 <sup>b</sup>	0.5±0.51 <sup>b</sup>	1.06±0.57 <sup>a</sup>
3	Dehiscence	0 <sup>a</sup>	0 <sup>a</sup>	0.06±0.25 <sup>a</sup>
4	Discharge	0 <sup>a</sup>	0 <sup>a</sup>	0.18±0.40 <sup>a</sup>
5	Composite	0.375 <sup>b</sup>	0.75 <sup>b</sup>	2 <sup>a</sup>

Values are represented as mean ± SEM. Dissimilar superscripts (abc) within a row indicate significant difference whereby  $P < 0.05$ .

By 8<sup>th</sup> day swelling, erythema and discharge were non-significant between Group A and Group B. However, values in Group A were significantly better than Group C with regards to swelling ( $P < 0.0001$ ), erythema ( $P < 0.0001$ ) and exudative discharge ( $P = 0.0007$ ). Whereas, there was no statistical significance

in case of dehiscence amongst the three respective groups. At 14<sup>th</sup> day post-surgery, a similar trend continued as scores in all fields were significantly better in Group A as compared to Group C. No incidence of purulent dehiscence was reported during the course of this study (Fig 1).

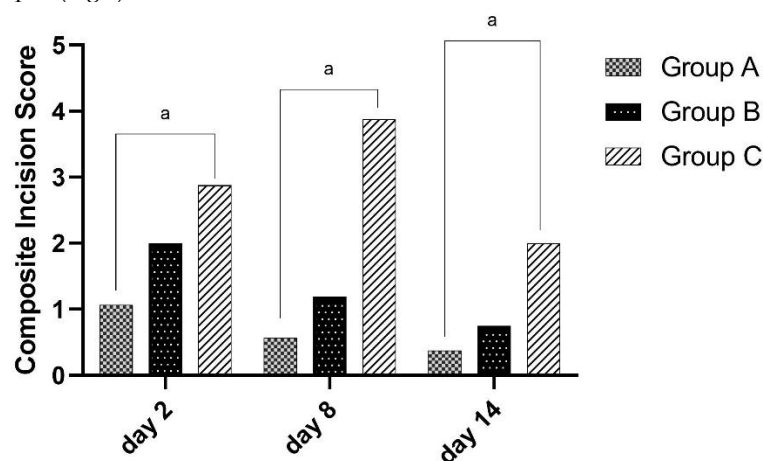


**Figure 1** Comparative effects of different suturing methodologies on wound scoring parameters (swelling, erythema, dehiscence and discharge) following canine ovariohysterectomy at day 2<sup>nd</sup> (A), day 8<sup>th</sup> (B) and day 14<sup>th</sup> (C). \*a-c: Differences between groups with different letters are statistically significant ( $P < 0.05$ ).

A quilting technique implemented during subcutaneous suturing was observed to significantly reduce postoperative swelling due to edema and

exudative drainage from the wound when a composite score for swelling, erythema, dehiscence and discharge were statistically analyzed at 2<sup>nd</sup>, 8<sup>th</sup> and 14<sup>th</sup> day.

Scores for Group A were demonstrably favorable as opposed to that of Group C (Fig 2).



**Figure 2** Effects of different suture patterns on composite incision score following canine ovariohysterectomy at day 2<sup>nd</sup>, day 8<sup>th</sup> and day 14<sup>th</sup>. \*a-c: Differences between groups with different letters are statistically significant ( $P < 0.05$ ).

Peri-incisional evaluation of pain was conducted by quantification of mechanical threshold using an Algometer and by scoring individuals on a feline composite pain scale at 2<sup>nd</sup>, 8<sup>th</sup> and 14<sup>th</sup> day after surgery. Mean scores of mechanical pain thresholds at 2<sup>nd</sup>, 8<sup>th</sup> and 14<sup>th</sup> day were recorded whereby Group A

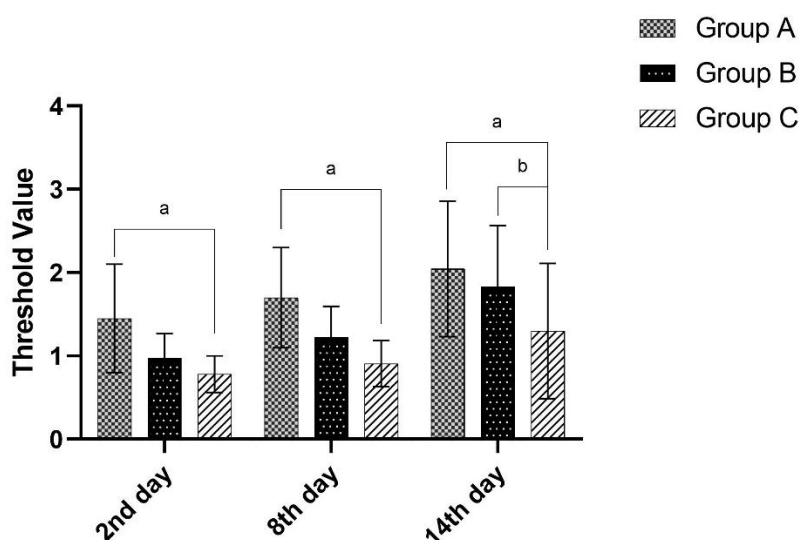
exhibited the highest peri-incisional threshold of pain ranging between 1.45-2.04 at different days (Table 3).

Mechanical thresholds were observed to be consistently lowest in individuals of Group C and significantly different than Group A at 2<sup>nd</sup> ( $P = 0.0038$ ), 8<sup>th</sup> ( $P = 0.0005$ ) and 14<sup>th</sup> ( $P = 0.0011$ ) day (Fig. 3).

**Table 3** Mean scores for Mechanical threshold of pain on peri-incisional area at 2<sup>nd</sup>, 8<sup>th</sup> and 14<sup>th</sup> day after surgery.

Pain threshold	Group A	Group B	Group C
Pain threshold (N) at 2nd day	1.45±0.65 <sup>a</sup>	0.97±0.29 <sup>b</sup>	0.78±0.21 <sup>b</sup>
Pain threshold (N) at 8th day	1.7±0.60 <sup>a</sup>	1.22±0.37 <sup>b</sup>	0.90±0.27 <sup>b</sup>
Pain threshold (N) at 14th day	2.04±0.81 <sup>a</sup>	1.83±0.73 <sup>b</sup>	1.3±0.81 <sup>c</sup>

Values are represented as mean ± SEM. Dissimilar superscripts (abc) within a row indicate significant difference whereby  $P < 0.05$ .



**Figure 3** Effects of different suture patterns on mechanical threshold values following canine ovariohysterectomy at day 2, 8 and 14. \*a-c: Differences between groups with different letters are statistically significant ( $P < 0.05$ ).

There was no significant difference between groups when scoring was performed while wielding a feline composite pain scale (Table 4) (Fig. 4).

Scarification and wound healing were analyzed using a modified visual analog scale. There was clear superiority in terms of exudation and drainage of

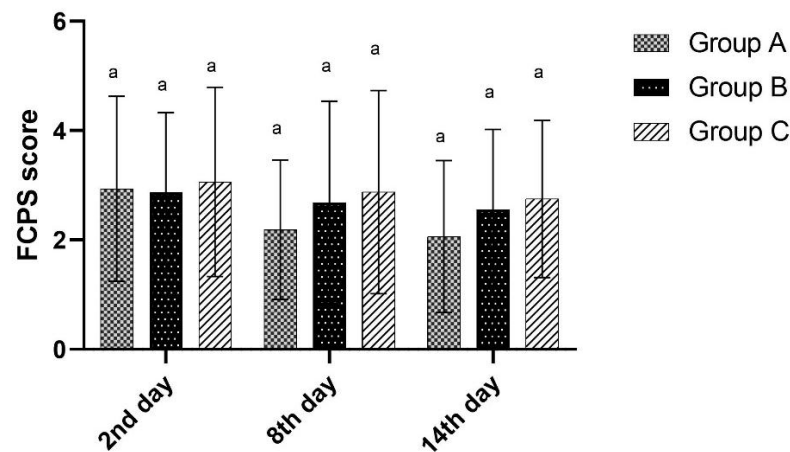
wound when Group A was analyzed as opposed to either Group B ( $P = 0.0157$ ) or Group C ( $P < 0.0001$ ) (Table 5) (Fig. 5).

Quality of apposition or dehiscence was slightly improved in Group A as well (Fig. 6).

**Table 4** Objective assessment of pain using feline composite pain scale (FCPS) at 2<sup>nd</sup>, 8<sup>th</sup> and 14<sup>th</sup> day after surgery.

Days post-surgery	Group A	Group B	Group C
2nd day	2.93±1.69 <sup>a</sup>	2.87±1.45 <sup>a</sup>	3.06±1.73 <sup>a</sup>
8th day	2.18±1.27 <sup>a</sup>	2.68±1.85 <sup>a</sup>	2.87±1.85 <sup>a</sup>
14th day	2.06±1.38 <sup>a</sup>	2.56±1.45 <sup>a</sup>	2.75±1.43 <sup>a</sup>

Values are represented as mean ± SEM. Dissimilar superscripts (<sup>abc</sup>) within a row indicate significant difference whereby  $P < 0.05$ .

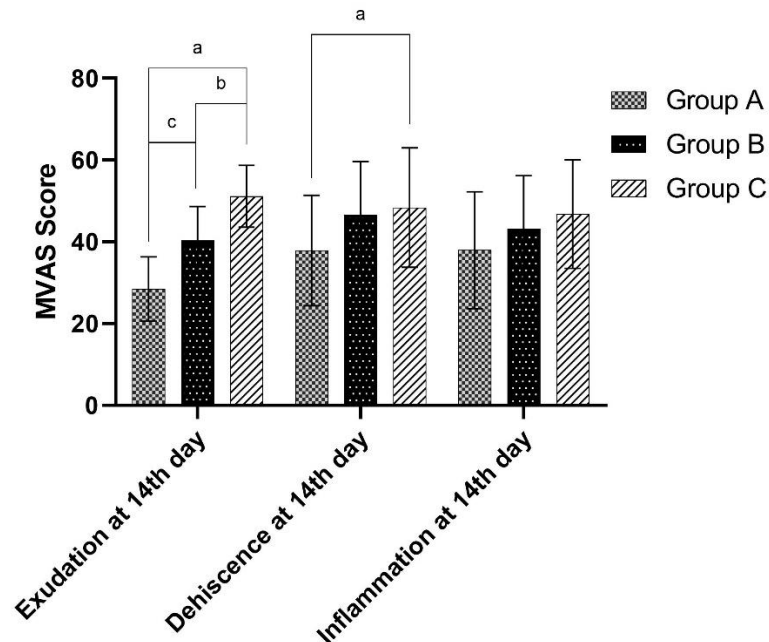


**Figure 4** Effects of different suture patterns on feline composite pain scale (FCPS) values following canine ovariohysterectomy at day 2, 8 and 14. \*a-c: Differences between groups with different letters are statistically significant ( $P < 0.05$ ).

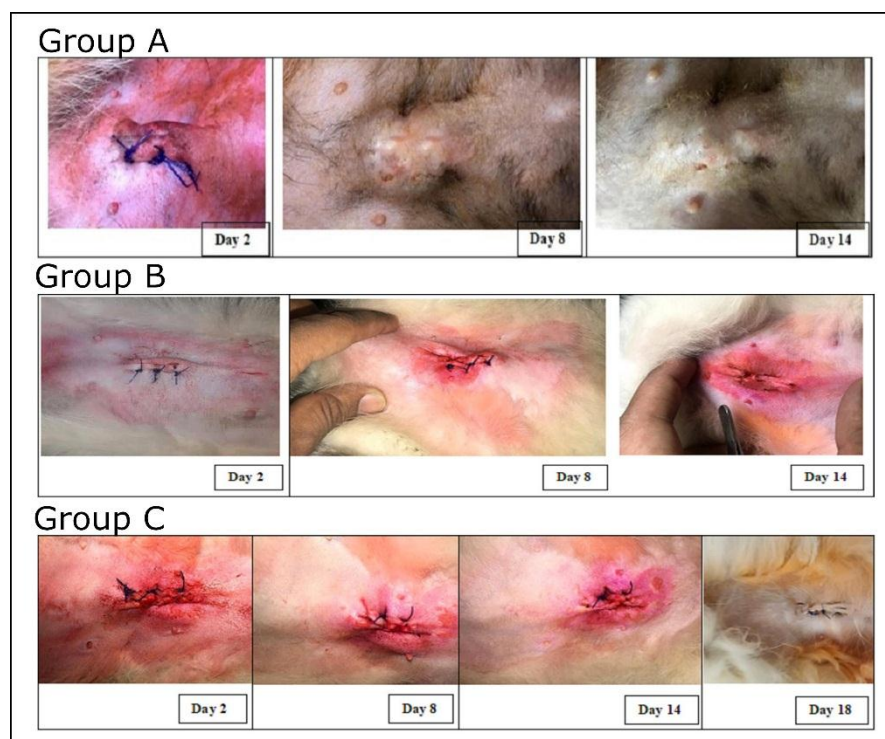
**Table 5** Mean scores for incisional appearance after suture removal by using modified visual analog scale.

Modified visual analog scale	Group A	Group B	Group C
Exudation at 14th day	28.43±7.85 <sup>c</sup>	40.37±8.28 <sup>b</sup>	51.12±7.55 <sup>a</sup>
Dehiscence at 14th day	37.87±13.51 <sup>b</sup>	46.62±12.99 <sup>b</sup>	48.37±14.60 <sup>a</sup>
Inflammation at 14th day	37.93±14.30 <sup>a</sup>	43.25±12.92 <sup>a</sup>	46.75±13.27 <sup>a</sup>

Values are represented as mean ± SEM. Dissimilar superscripts (<sup>abc</sup>) within a row indicate significant difference whereby  $P < 0.05$ .



**Figure 5** Effects of different suture patterns on scoring accomplished by modified visual analog scale (MVAS) for analysis of incisional appearance after suture removal following canine ovariohysterectomy at day14. \*a-c: Differences between groups with different letters are statistically significant ( $P < 0.05$ ).



**Figure 6** Pictorial progression of incisional healing in surgical patients; Group A (subcutaneous continuous pattern with rectus tacking employing PGA USP 3-0 suture was subsequently over-sewn by horizontal mattress pattern using polypropylene USP 2-0), Group B (subcutaneous continuous pattern without rectus fascia incorporation using PGA USP 3-0 suture subsequently over-sewn by horizontal mattress pattern with polypropylene USP 2-0) and Group C (No subcutaneous suturing).

### Discussion

This study was predicated upon implementing a myriad of Subcutaneous closure techniques while employing Polyglactin 910 (Vicryl™) USP 3-0 suture to compare their effects on biocompatibility and postoperative pain experienced by cat that had undergone ovariohysterectomy. It was a randomized trial performed on clinical patients after informed consent was obtained. Ovariohysterectomy (spaying) was performed and incisional wounds along with parameters of pain assessment were monitored at 2<sup>nd</sup>, 8<sup>th</sup>, and 14<sup>th</sup> days after surgery. At 2<sup>nd</sup> day, swelling and erythema were observable in all groups which may be attributed to increased tissue handling and immunological response to implanted sutures (Runk *et al.*, 1999).

A prior study has concluded that postoperative swelling may even be elevated when subcutaneous tissue is apposed during suturing. Similar studies have discussed the bio-reactive nature of absorbable sutures and analyzed the characteristics of suture material that have a correlation with inflammatory reactions (Muir *et al.*, 1993). Most postoperative complications are linked to tissue reactions that cause seroma and erythema leading to dehiscence. This factor has been linked to several postoperative complications in dogs and cats ranging from 1-24% (Pollari and Bonnett, 1996). In veterinary medicine several factors such as surgical duration, postoperative care and aseptic conditions all may bear demonstrable effect on healing. Interestingly enough, NSAIDs such as meloxicam are capable anti-inflammatories and can therefore reduce inflammatory indications of tissue reaction postoperatively. However, as in our research plan

meloxicam was administered in all groups thereby its positive effects could not have influenced overall scheme of the study. Polyglactin 910 (Vicryl™) suture was found to be adequate for subcutaneous tissue closure as it imposed tolerable tissue response and reasonable tensile support during healing process (Bezwada *et al.*, 1995). A resounding absence of any instance of suture failure are testament of this suture's abilities. As described in previous studies, authors made sure to tie knots securely by hurling at least four throw square knots (Trimbos *et al.*, 1995).

Continuous subcutaneous sutures with deep buried knot are time taking and labor intensive requiring high level of technical acumen. Based on incisional reaction at different stages of healing, we have observed that subcutaneous apposition was quite useful for closure and obliteration of dead spaces. A modified methodology to maximize efficacy of a subcutaneous deep buried knot pattern is to incorporate rectus fasciae or external sheath at intermittent distances while taking a bite through subcutaneous fascia (Lopez *et al.*, 2020). This technique commonly referred to as quilting has been studied in humans and proven effective in closure of laparotomic incisions, traumatic skin avulsion injuries, ventral hernia repairs (Alhussini *et al.*, 2019), port site closure after laparoscopy (Fortelny, 2018), latissimus dorsi breast reconstruction (Khater *et al.*, 2015) and mastectomies (Mazouni *et al.*, 2015).

A study with comparable primary outcomes in dogs concluded that by tacking bites of suture through rectus tissue incidence and severity of seroma could be considerably reduced thereby reducing postoperative pain (Travis *et al.*, 2018). Outcomes in our study



corroborated previously published evidence as well (Fig. 1). The current study has discovered that there was significant improvement in convalescence and healing of patients in whom subcutaneous tissue closure was employed as compared to instances where only superficial layers of skin were sutured (Fig. 2). Similar to earlier outcomes our research has also observed an improvement in mechanical threshold readings taken with an algometer at peri-incisional sites at different time durations (Fig. 3). This phenomenon may be rationalized by a marked lack of inflammation and seroma formation along with adequate tissue stabilization which hastened healing to such a degree that most patients inducted in Group A of our study had their sutures removed by 8<sup>th</sup> day. This consequently helped in reducing overall erythema and soreness around incisional areas.

However, quilting optimized benefits of subcutaneous closure in certain regards only. Our study did not discover any evidence reinforcing a misconception that in cats suturing subcutaneous fat leads to steatosis thereby leading towards decreased movement and causing stretching of sub cut in relation to surrounding tissue. It has been believed that due to such overbearing tension on underlying tissue quilting is not feasible in cats (Freeman *et al.*, 1987; Gouletsou *et al.*, 2020). But we have observed that there was no significant difference observed on Feline composite pain scale indicating any abnormal vocalization or discomfort in patient's free movement (Fig. 4).

There have been investigations into developing other techniques such as suction drains, compression bandaging and use of fibrin glue to stabilize rectus sheath and subcutaneous fat but considering the required postoperative care or cost that is involved in their effective execution, quilting is still the most feasible amongst the lot (Bercial *et al.*, 2012; Bristow *et al.*, 2015; Chang *et al.*, 2018). Authors of this manuscript have observed that cosmetic appearance and rate of apposition in tacked and untacked subcutaneous pattern were similar however these findings were in contrast to prior observations (Pollari and Bonnett, 1996). To this end, cosmetic evaluation of incisions was performed at 14<sup>th</sup> day when all cases would presumably have healed, to verify if suturing methodology posed a significant impact on the outlook of a surgical incision. A similar design had been previously employed by Lopez *et al.* (2020) and Travis *et al.* (2018). Nevertheless, as there were no cases of purulent dehiscence reported in this study and superficial layers of skin in all cases were everted using horizontal mattress pattern consequently observations made with modified visual analog scale (Fig. 5) did not pose considerable bearing on overall findings (Quinn and Wells, 1998).

In conclusion, a modified technique for the placement of continuous subcutaneous deep buried knot suture pattern termed as quilting suture pattern effectively reduced seroma formation thereby significantly hastening wound healing and improving peri-incisional pain scores with minimal compromise, if any in cosmetic appearance of the incision. In light of present findings, authors recommend suturing of subcutaneous tissues to avoid post-operative seroma, exudation and pain. We believe that ubiquitous

implementation of a quilting pattern during spaying would improve animal's health and decrease emotional distress for pet owners.

**Conflict of Interest:** Authors declare no conflict of interest pertaining to this study.

### Acknowledgements

Authors thank Dr. Taimoor Saleem, The Vets Animal Hospital; Dr. Khalil, KM Pets Clinic; Dr. Muhammad Umar Haider, Paws to Hooves veterinary clinic for their support in regards with preparation for this research manuscript.

### References

- Alhussini MA, Awad AT, and Kholosy HM 2019. Using quilting sutures in decreasing seroma formation after managing large ventral hernias: a comparative study. *Hernia*. 23: 717-722.
- Bercial ME, Neto MS, Calil JA, Rossetto LA, and Ferreira LM 2012. Suction drains, quilting sutures, and fibrin sealant in the prevention of seroma formation in abdominoplasty: which is the best strategy? *Aesthetic Plast Surg*. 36: 370-373.
- Bezwada RS, Jamiolkowski DD, Lee I-Y, Agarwal V, Persivale J, Trenka-Benthin S, Erneta M, Suryadevara J, Yang A, and Liu S 1995. Monocryl® suture, a new ultra-pliable absorbable monofilament suture. *Biomaterials*. 16: 1141-1148.
- Bristow PC, Halfacree ZJ, and Baines SJ 2015. A retrospective study of the use of active suction wound drains in dogs and cats. *J Small Anim Pract*. 56: 325-330.
- Chang JW, Oh J, and Jung US 2018. Umbilical Quilting Suture Technique during Single-Port Laparoscopic Surgery. *J Soc Laparoendosc Surg*. 22: e2017.00088.
- Fortelny RH 2018. Abdominal wall closure in elective midline laparotomy: the current recommendations. *Front Surg*. 5: 34.
- Freeman LJ, Petit GD, Robinette JD, Lincoln JD, and Person MW 1987. Tissue reaction to suture material in the feline linea alba a retrospective, prospective, and histologic study. *Vet Surg*. 16: 440-445.
- Gates MC, Littlewood KE, Kongara K, Odom TF, and Sawicki RK 2020. Cross-sectional survey of surgical techniques used to perform dog and cat spays in New Zealand veterinary practice. *N Z Vet J*. 68: 46-53.
- Gouletsou PG, Prassinis NN, Papazoglou LG, Kostoulas P, and Galatos AD 2020. Comparison of continuous intradermal with simple interrupted suture pattern: an experimental study in dogs. *Top Companion Anim Med*. 41: 100454.
- Hart AM, Duggal C, Pinell-White X, and Losken A 2017. A prospective randomized trial of the efficacy of fibrin glue, triamcinolone acetone, and quilting sutures in seroma prevention after latissimus dorsi breast reconstruction. *Plast Reconstr Surg*. 139: 854e-863e.
- Hendrickson DA 2018. Management of Superficial Wounds, Deep and Chronic Wounds, Sinus Tracts and Fistulas. In: *Equine Surgery*. 5th ed. JA Auer,



- JA Stick, JM Kümmerle, and T Prange (eds). Philadelphia: WB Saunders. 403-425.
- Husslein H, Gutschi M, Leipold H, Herbst C, Franz M, and Worda C 2014. Suture Closure versus Non-Closure of Subcutaneous Fat and Cosmetic Outcome after Cesarean Section: A Randomized Controlled Trial. *PLoS One*. 9: e114730.
- Khater A, Elnahas W, Roshdy S, Farouk O, Senbel A, Fathi A, Hamed E, Abdelkhalek M, and Ghazy H 2015. Evaluation of the quilting technique for reduction of postmastectomy seroma: a randomized controlled study. *Int J Breast Cancer*. 2015.
- Kitshoff AM, Louwagie J, Or M, Devriendt N, Dehuysser V, Koenraad A, Vandenabeele S, Sys SU, and De Rooster H 2018. Biomechanical properties of celiotomy wounds closed with tape and cyanoacrylate versus intradermal sutures. *Vet Surg*. 47: 1087-1093.
- Kumar V 2020. Abdominal intercostal hernia in a Cat (*Felis domestica*). *Top Companion Anim Med*. 40: 100437.
- Lopez DJ, Hayes GM, Fefer G, McCalla SA, LaLonde-Paul DF, Flanders JA, and Sumner JP 2020. Effect of subcutaneous closure technique on incisional complications and postoperative pain in cats undergoing midline celiotomy: A randomized, blinded, controlled trial. *Vet Surg*. 49: 321-328.
- Maftai GA, Martu CM, Popa C, Geletu G, Danila V, Jelihovschi I, and Foia L 2019. The Biomechanical Properties of Suture Materials and Their Relationship to Bacterial Adherence. *Mater*. 56: 980.
- Marsidi N, Vermeulen SAM, Horeman T, and Genders RE 2020. Measuring Forces in Suture Techniques for Wound Closure. *J Surg Res*. 255: 135-143.
- Mazouni C, Mesnard C, Cloutier A-S, Amabile M-I, Bentivegna E, Garbay J-R, Sarfati B, Leymarie N, Kolb F, and Rimareix F 2015. Quilting sutures reduces seroma in mastectomy. *Clin Breast Cancer*. 15: 289-293.
- Miller KJ, Cao W, Ibrahim MM, and Levinson H 2017. The effect of microporous polysaccharide hemospheres on wound healing and scarring in wild-type and Db/Db mice. *Adv Skin Wound Care*. 30: 169-180.
- Misk TN and EL-sherry TM 2020. Pyometra in Cats: Medical Versus Surgical Treatment. *J Curr Vet Res*. 2: 86-92.
- Muir P, Goldsmit SE, Simpson DJ, and Bellenger CR 1993. Incisional swelling following celiotomy in cats. *Vet Rec*. 132: 189-190.
- Ouldamer L, Bonastre J, Brunet-Houdard S, Body G, Giraudeau B, and Caille A 2016. Dead space closure with quilting suture versus conventional closure with drainage for the prevention of seroma after mastectomy for breast cancer (QUISERMAS): protocol for a multicentre randomised controlled trial. *BMJ Open*. 6: e009903.
- Özer K, Karabağlı M, Ömer H, and Demir ME 2017. Surgical treatment of dorsal scapular luxation in cats: 6 cases (2010-2016). *Kafkas Univ Vet Fak Derg*. 23: 503-506.
- Panayi AC, Reitblat C, and Orgill DP 2020. Wound Healing and Scarring. In: *Total Scar Management*. R Ogawa (ed). Singapore: Springer. 3-16.
- Papazoglou LG, Tsioli V, Papaioannou N, Georgiadis M, Savvas I, Prassinis N, Kouti V, Bikiaris D, Hadzigiannakis C, and Zavros N 2010. Comparison of absorbable and nonabsorbable sutures for intradermal skin closure in cats. *Can Vet J*. 51: 770.
- Pollari FL and Bonnett BN 1996. Evaluation of postoperative complications following elective surgeries of dogs and cats at private practices using computer records. *Can Vet J*. 37: 672.
- Quinn J V and Wells GA 1998. An assessment of clinical wound evaluation scales. *Acad Emerg Med*. 5: 583-586.
- Read J, Price CE, Adams S, and Hudson DA 2017. Morel-Lavallée Lesion Contour deformity: quilting sutures to prevent recurrent seroma after resection. *Plast Reconstr Surg Glob Open*. 5: e1267.
- Runk A, Allen SW, and Mahaffey EA 1999. Tissue reactivity to poliglecaprone 25 in the feline linea alba. *Vet Surg*. 28: 466-471.
- Scharner D, Gittel C, Winter K, Blaue D, Schedlbauer C, Vervuert I, and Brehm W 2018. Comparison of incisional complications between skin closures using a simple continuous or intradermal pattern: a pilot study in horses undergoing ventral median celiotomy. *PeerJ*. 6: e5772.
- Smeak DD 1992. Buried continuous intradermal suture closure. *Compend Contin Educ Pract Vet*. 14: 907-913.
- Stavisky J and Brennan M 2020. Comparing wound complications associated with midline and flank approaches for spaying cats. *Vet Rec*. 186: 86-92.
- Travis BM, Hayes GM, Vissio K, Harvey HJ, Flanders JA, and Sumner JP 2018. A quilting subcutaneous suture pattern to reduce seroma formation and pain 24 hours after midline celiotomy in dogs: A randomized controlled trial. *Vet Surg*. 47: 204-211.
- Trimbos JB, Niggebrugge A, Trimboos R, and Van EJR 1995. Knotting abilities of a new absorbable monofilament suture: poliglecaprone 25 (Monocryl). *Eur J Surgery = Acta Chir*. 161: 319-322.
- Zellner EM, Hedlund CS, Kraus KH, Burton AF, and Kieves NR 2016. Comparison of tensile strength among simple interrupted, cruciate, intradermal, and subdermal suture patterns for incision closure in ex vivo canine skin specimens. *J Am Vet Med Assoc*. 248: 1377-1382.