

Generalized enamel hypoplasia in a dog: a case report

Issarin Sittijarusub¹ Panithi Sukho² Patchamon Supannawapat³ Namphung Suemanotham^{2*}

Abstract

A one-year-old, spayed female Welsh Corgi dog referred to the dental and oral clinic with chief complaint of apparent pitted, rough teeth surfaces, stained a tan to dark brown color. The dog was diagnosed with diffused enamel hypoplasia with no evidence of endodontic disease or malformation of tooth root. A restorative procedure with nanohybrid composite resin was performed. After treatment, the dog showed a good outcome with a smooth tooth surface, restorative material replaced to cover the previous defect and no evidence of pain or discomfort. Even though enamel hypoplasia is a rare, this condition remains an important problem that can lead to severe problems of dental status in the future. This is the first report of generalized enamel hypoplasia in a canine clinical case at Prasu-Arthorn Animal Hospital, the Faculty of Veterinary Science at the Mahidol University with treatment and a 20 months follow up.

Keywords: Enamel hypoplasia, Restorative dentistry, Dog

¹Graduate Diploma Program in Clinical Veterinary Science, Faculty of Veterinary Science, Mahidol University, 999 Thanon 3310, Salaya, Phutthamonthon District, Nakhon Pathom 73170, Thailand

²Department of Clinical Sciences and Public Health, Faculty of Veterinary Science, Mahidol University, 999 Thanon 3310, Salaya, Phutthamonthon District, Nakhon Pathom 73170, Thailand

³Prasu-Arthorn Animal Hospital, the Faculty of Veterinary Science at the Mahidol University, 999 Thanon 3310, Salaya, Phutthamonthon District, Nakhon Pathom 73170, Thailand

*Correspondence: namphung.sue@mahidol.edu (N. Suemanotham)

Received: November 5, 2020.

Accepted: January 20, 2021.

doi: <https://doi.org/10.14456/tjvm.2021.47>

Introduction

Enamel hypoplasia is defined as enamel defects that present incomplete or defective formation of the enamel matrix (Lobprise, 2019). A decrease of enamel thickness occurs during tooth development. Enamel acts as a barrier to protect the oral cavity from bacteria invading dental pulp, thus an uneven surface leading to increased accumulation of plaque and tartar can cause the early onset of periodontal disease (Hale, 2005). The lesions of enamel hypoplasia include a discolored and abnormal tooth surface which is pitted and rough (Hale, 2005; Lobprise, 2019).

Enamel hypoplasia can be classified by its clinical features, pathogenesis or etiology (Boy *et al.*, 2016). However, the Federation Dentaire International suggests using the developmental defects of enamel as a standardized classification of enamel hypoplasia in humans using clinical findings such as either pits, grooves or lines or areas of absent enamel (Boy *et al.*, 2016). Pathogenesis of enamel hypoplasia that is related to the process of amelogenesis can be described in two groups: first, hypoplastic enamel due to incomplete or disrupted matrix production; second, inadequacy of enamel matrix mineralization (Kanchan *et al.*, 2015). Etiological factors can be divided into hereditary factors and environmental factors (Boy *et al.*, 2016; Lobprise, 2019).

In dogs, the incidence of enamel defect is very rare (Kyllar and Witter, 2005; P *et al.*, 2016). Previous studies have reported enamel hypoplasia is as inherited disease in standard poodles, Italian greyhounds and Samoyeds (Gandolfi B, 2013; Mannerfelt and Lindgren, 2009; Pedersen *et al.*, 2017). Enamel hypoplasia may be found as localized (single tooth) or diffused (multiple teeth). Diffuse or multiple teeth involved are more common which may be caused by insult during enamel formation, nutritional deficiencies, epitheliotropic viral infection (especially when caused by morbilliviruses, such as distemper) (Dubielzig *et al.*, 1981), pyrexia of any origin, disturbances of the metabolism, trauma, chemicals which have a toxic effect on ameloblasts at the age of 2 weeks to 3 months (Lobprise, 2012, 2019; Wong, 2014).

Diagnosis of enamel hypoplasia is based on clinical appearance (Lobprise, 2012, 2019; Wong, 2014). The clinical signs in canine species usually present after 6 months of age at a time of full mouth eruption (Lobprise, 2012). Differential diagnoses of this condition include: crown fracture from trauma, tooth malformation, caries and enamel staining (Lobprise, 2012; Niemiec, 2010). A dental explorer is used for examination of the affected area (Niemiec, 2010). This fine instrument will become snagged in a roughened but hard surface and create a tugging effect from lesions (Tutt, 2006). Dental radiography should be performed to evaluate the severity of abnormalities when in deep in the pulp cavity and root (Niemiec, 2010).

Treatment options depend on many factors including the number of affected teeth, the severity of the defects, the owner's expectations, budget and the veterinarian's knowledge, skill and resources (Lobprise, 2012). The treatment goal is providing the smoothest surface to decrease plaque accumulation

and seal the exposed dentinal tubules to prevent endodontic infection (Niemiec, 2010). Therefore, the most effective technique to accomplish these aims is to bond composite restoration and to reduce the risk of periodontal disease with homecare management by brushing techniques (Niemiec, 2010). Other techniques that can be used on this disease are prosthetic crown placement which is a more expensive and complicated technique and extraction of a severely defective tooth (Holmstrom, 2013; Lobprise, 2019). The prognosis for the tooth is good to fair, depending on the severity of lesion and root involvement (Lobprise, 2012).

Although, there are few reports of enamel hypoplasia, veterinarians should not overlook this condition because enamel cannot be repaired or regenerated after eruption (Boy *et al.*, 2016). Precise diagnosis can result in appropriate treatment and management, that can reduce the risk of periodontal disease and tooth fracture which is a more severe dental problem in the future (Gorrel, 2008). Therefore, the purpose of this case report was to describe the clinical presentation, diagnostic method, treatment options and outcome of enamel hypoplasia in a dog treated with composite restoration.

Case presentation

A 1-year-old, spayed female Welsh Corgi, weighing 10.2 kg, was referred to the Dental and Oral Clinic in Prasu-Arthorn Animal Hospital, Faculty of Veterinary Science, Mahidol University with the chief complaint of pitted, rough teeth surfaces and staining of a tan to dark brown color. No sign of discomfort or pain was detected by owner. From history taking, the dog had a record of severe infection at the age of 2 months. Previous illnesses included Parvo viral, Corona viral infection and severe respiratory problem (with PCR test of canine distemper virus negative). At that time, many antimicrobial drugs were used such as betalactam, fluroquinolone, and doxycycline. The dog recovered after a month of intensive treatment.

On physical examination, the dog was bright, alert and responsive; its body condition score was 3 from 5 with a normal appetite. No abnormality was detected with respiration, heart rhythm, heart sound and pulse quality. Oral examination showed evidence of an enamel defect in the many teeth. It revealed diffuse lesion of pits, rough surfaces and many plaque and calculus accumulations on the crowns especially the pre-molars and molars both maxilla and mandible. There was mild gingivitis but no ulceration of gingiva or sublingual area (Figure 1 A, B).

Regional lymph node examination was within normal limits. Following clinical examination, radiographic examination was performed to rule out endodontic disease or root malformation; however, there was no evidence of such (Figure 2).

Diagnosis of this case was based on case history and clinical signs that were related to diffused enamel hypoplasia. The roughness of the teeth increased plaque and calculus retention and the thin enamel was prone to tooth fracture and pulp exposure. In order to treat this condition, a placement of bonded composite restoration was decided upon.

A blood sample was collected before anesthesia and dental restoration, for hematological and biochemical evaluation (Table 1).

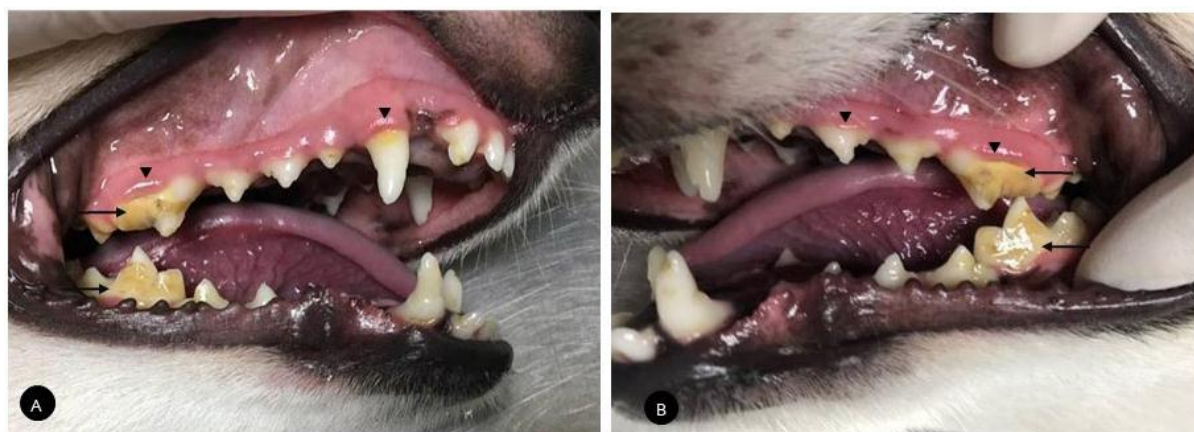

Figure 1 Patient's oral examination A) from the left lateral recumbency position showing diffuse lesion of pits, irregular surface and many plaque and accumulation on the crowns (arrow). Gingival hyperemia was appeared (arrow head) indicating of gingivitis but no sign of ulceration B) From the right lateral recumbency position showing clinical appearance similar to the other side.

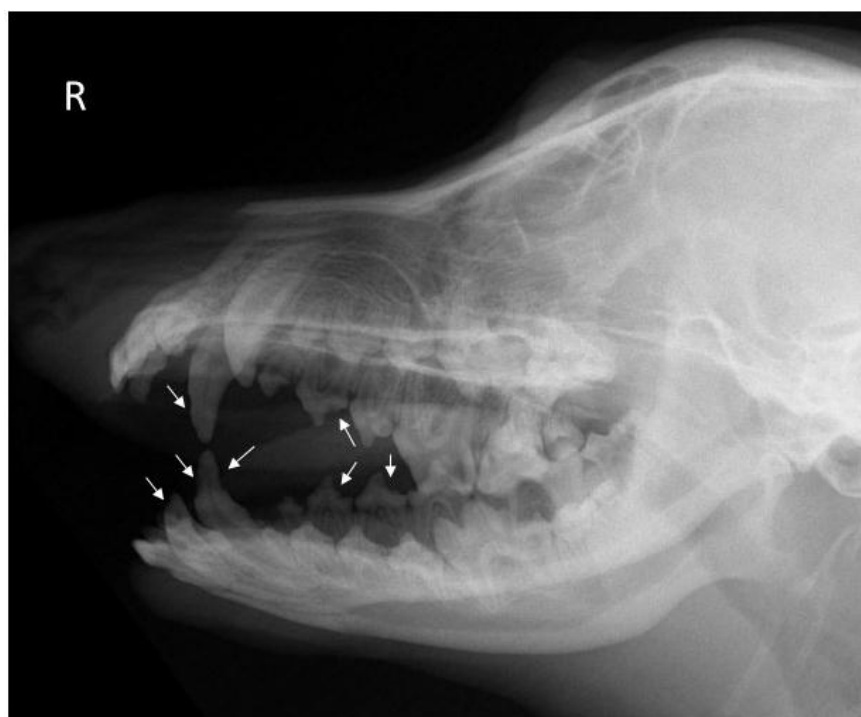

Figure 2 Radiographic examination result. Right lateral oblique view; found irregular of outer teeth surface (Enamel hypoplasia; arrow) and no evidence of root malformation or endodontic disease and no evidence of bone fracture or lysis.

Table 1 Hematologic test and serum biochemistry results.

Parameter	Result	Reference interval
Erythrocytes x 10 ⁶ (cell/mm ³)	7.11	5-9
Hemoglobin (g/dL)	16.5	10-18
Hematocrit (%)	45	35-55
Total Leukocytes (cell/mm ³)	8,100	4,000-17,600
Monocyte	0	0-1,400
Neutrophil	5,589	2,500-14,300
Lymphocyte	2,268	300-3,900
Eosinophil	243	0-1,300
Basophil	0	0-100
Band neutrophil	0	0-200
Platelets x10 ³ (cell/ μ L)	225	200-500
Alanine aminotransferase (U/L)	39	10-100
Creatinine (mg/dL)	1.5	0.5-1.8

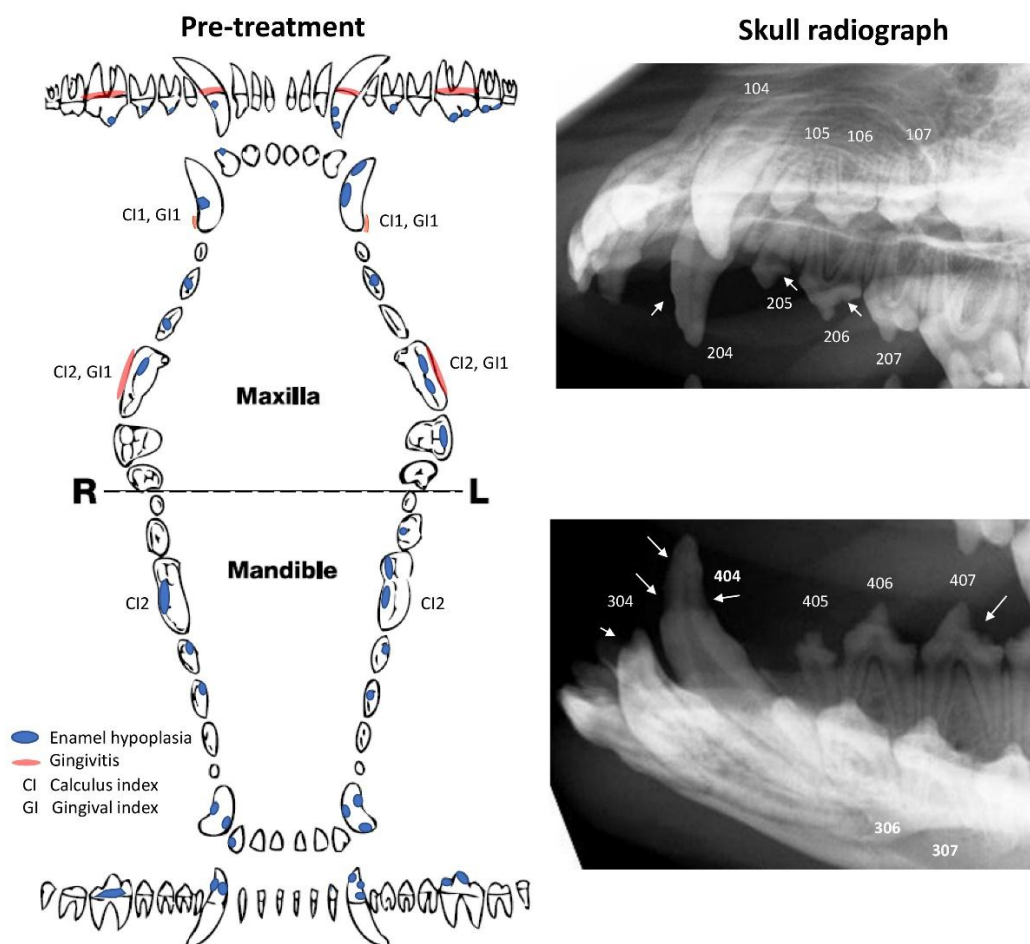
Treatment

The dog was premedicated with acepromazine 0.03 mg/kg via the intramuscular route and propofol 4 mg/kg by the intravenous route was used for induction, then anesthetic maintenance was obtained by isoflurane. Acetate Ringer's solution was administered intravenously at a flow rate of 10 ml/kg/hr in the first hour then decreased to 5 ml/kg/hr until the surgical procedure was completed. Prophylactic antimicrobial was applied with 8.75 mg/kg amoxicillin-clavulanic acid via the subcutaneous route. Carprofen was prescribed for anti-inflammation at a dosage of 4.4 mg/kg via the subcutaneous route.

Once the dog was placed in lateral recumbency, a comprehensive oral examination with periodontal probing was performed. There was mild gingivitis and dental tartar but no evidence of ulceration, tooth mobility, missing teeth or furcation exposure. Severe lesions of the pitted and the rough surface of teeth 103, 104, 106, 108, 204, 206, 208, 209, 304, 307, 308, 309, 404 and 409 were found as described in the dental chart (Figure 3 and Table 2). Before the surgical procedure started, the pharynx was packed with gauze to prevent the entering of debris and fluid into the air way. Lidocaine hydrochloride (2%) at the dose of 1 mg/kg mixed with bupivacaine (0.5%) at a ratio 1:4 was used for local blocking of the right and left caudal maxillary nerve. and right and left caudal mandibular nerves.

Canine dental chart

Animal information: Canine	Breed: Corgi	Sex: Male	Age: 1 year old
Occlusion: Normal	Previous oral and dental home care: None		
Type of diet: Dry pellet			



Oral Exam: mild calculus accumulation and mild gingivitis, normal periodontal pocket depth when probing, Generalized enamel hypoplasia (EH) (severe lesion of the pit and the rough surface of teeth 103, 104, 106, 108, 204, 206, 208, 209, 304, 307, 308, 309, 404 and 409)

Radiography: EH but no dental root or others defect was seen.

Treatment: Dental scaling and polishing then restorative treatment for EH

Recommended re-visit schedule: 6 months

Figure 3 Pre-treatment dental chart and skull radiograph. Pathological lesions were noted in the dental chart during anesthesia oral and dental examination before dental treatment.

Table 2 Clinical parameters* (Figure 3)

Parameters	Grades
Calculus index (CI)	0 No observable calculus 1 Calculus cover less than one-third of buccal surface 2 Calculus cover between one-third and two-third of buccal surface with minimal subgingival extension 3 Calculus cover more than two-third of buccal surface and extends subgingivally
Gingival index (GI)	0 Normal healthy gingivae with sharp non-inflamed edges 1 Marginal gingivitis; minimal inflammation at free margin 2 Moderate gingivitis; wider band of inflammation; bleeding on probing 3 Advance gingivitis; inflammation clinically reaching mucogingival junction; spontaneous bleeding sometime present

*Heidi B Lobprise (2012), Blackwell's Five-Minute Veterinary Consult Clinical Companion: Small Animal Dentistry, 2nd Edition, Blackwell, Australia

The first procedure was the removal of supragingival calculus by Magnetostrictive Ultrasonic scaler (Rhinoceros TOP, Mid-west dental group), followed by hand scaling and curette to ensure that supragingival and subgingival calculi had been completely removal. Scaling was performed for less than 15 seconds per tooth and only on the side and tip (Figure 4A). After that, subgingival scaling was applied to remove calculus and plaque from the tooth using a subgingival curette. The curette was inserted into the pocket to remove the calculus gently, as the gingival was delicate (Figure 4B) (Holmstrom, 2013). Staining the teeth with 6% erythrosine was done to recheck the remains of calculus (Figure 4C). Next, the teeth were polished to smooth the surface with a prophy cup with a slow-speed hand piece; phosphate fluoride was used as a prophylactic agent (Figure 4D). Then a stream of water and air was blown into the pocket to rinse and allow visualization of the root surface and evaluate the adequacy of cleaning.

The restoration process was initiated by delimitation of the tooth irregularities with a high-speed dental handpiece using a round diamond bur to avoid exposing the pulp (Figure 5A). Etching was performed after the tooth surface dried with 37% phosphoric acid etchant gel (Super etch, SDI Limited, Victoria AUS) being applied to the dental surface for 20 seconds (Figure 5B), removed with a dry gauze then rinsed with water and dried by air blowing. This step was used to demineralize the enamel and promote the surface area where bonding agents had been applied. A single component adhesive system was used on the dentin and the enamel (Stae, SDI Limited) (Figure 5C), air blown and light cured for 20 seconds. Following the bonding agent, a nano-hybrid composite shade A2 (ICE, SDI Limited) was used to fill the defect tooth using a dental wax carver to decorate the shape and light cured for 20 seconds (Figure 5D, E). In cases of deep defect, the defect was filled again as each layer of composite could not be more than 2 mm before being light cured. The contour was refined using a sanding

disc and a final polishing was performed again (Figure 5F).

After restoration treatment had been finished, the dog recovered from anesthesia well with normal vital signs. Carprofen was prescribed for anti-inflammation at a dosage of 4.4 mg/kg for 3 days. Client education for dental home care and management was performed to ensure that the owner brush the dog's teeth daily and prevented the dog from chewing any hard objects.

Outcome and Follow up

A day after the restoration, the owner found a small amount of blood after teeth brushing but there was no evidence of pain and discomfort. The dog had a normal appetite and thirst. A week after restoration, according to oral examination, the restorative material was still in the appropriated composition and no halitosis or gingivitis were detected (Figure 6A, B). Somehow, when the teeth were stained with 6% erythrosine, little plaque at teeth 108, 204 and 208 was seen. Radiographic examination found that the restoration had covered the previous defect and there were no remarkable lesions on tooth root (Figure 7A).

Six months after the restorative treatment most of the restorative material was in place except at 106, 203 and 304. Even though the owner brushed the dog teeth's every day and fed it with dry food, there was dental tartar accumulation with mild gingivitis but no halitosis (Figure 6C, D). Skull radiography revealed a narrowing of the pulp chamber compared to previous radiography and missing restoration material at 106 and 304 that did not involve dental pulp. (Figure 7 B)

Twenty months after the restorative treatment, there was dental tartar accumulation with mild gingivitis and mild halitosis. The owner allowed the dog to undergo anesthesia again for dental scaling and polishing but no skull radiography was taken. Most of the restorative material had stayed in place (Figure 6E, F).

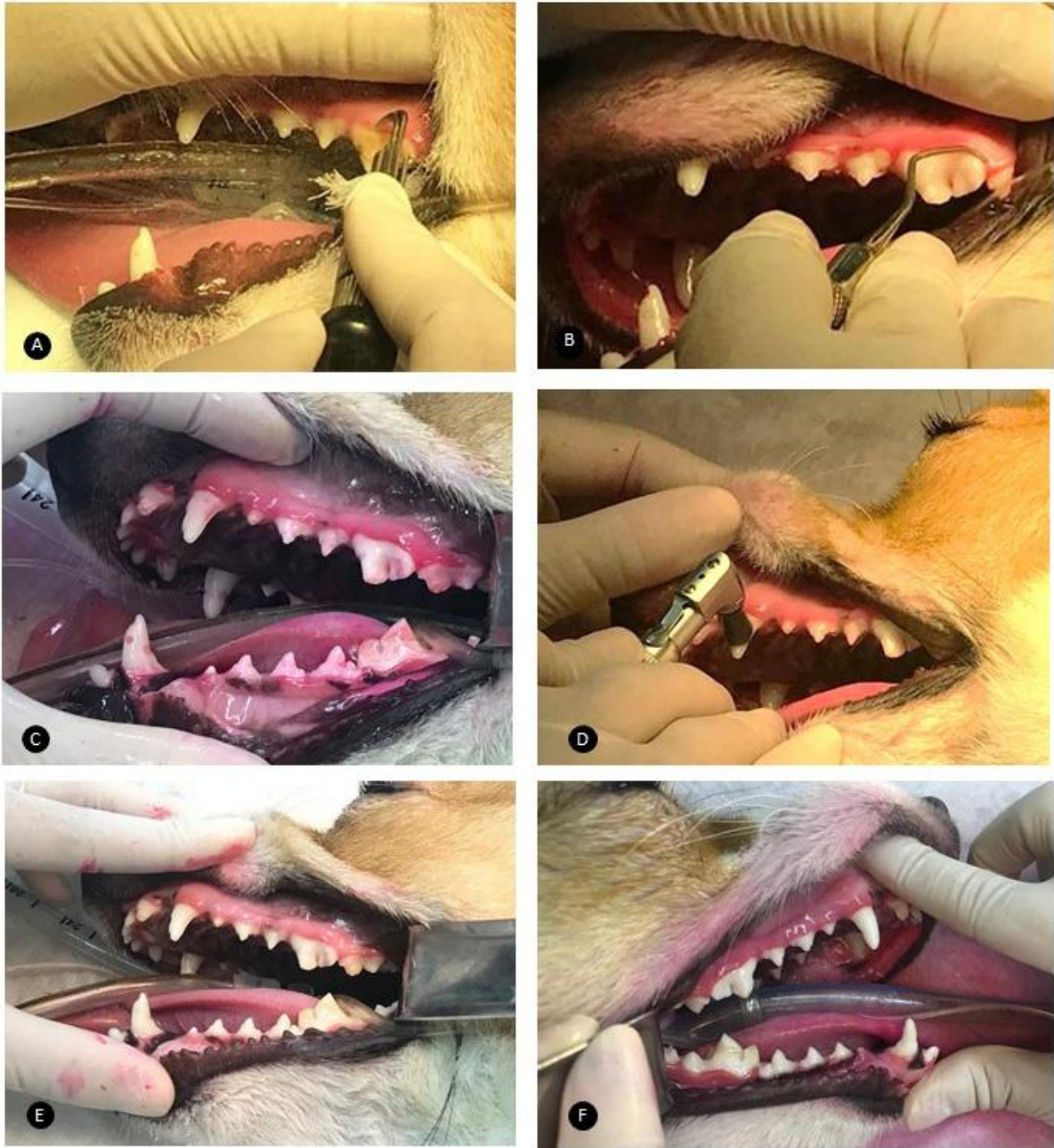

Figure 4 Dental scaling and polishing methods A) Supragingival scaling B) Subgingival scaling C) Staining the teeth with 6% erythrosine D) Polished the teeth E) and F) Results after dental scaling procedure (Hale, 2005).

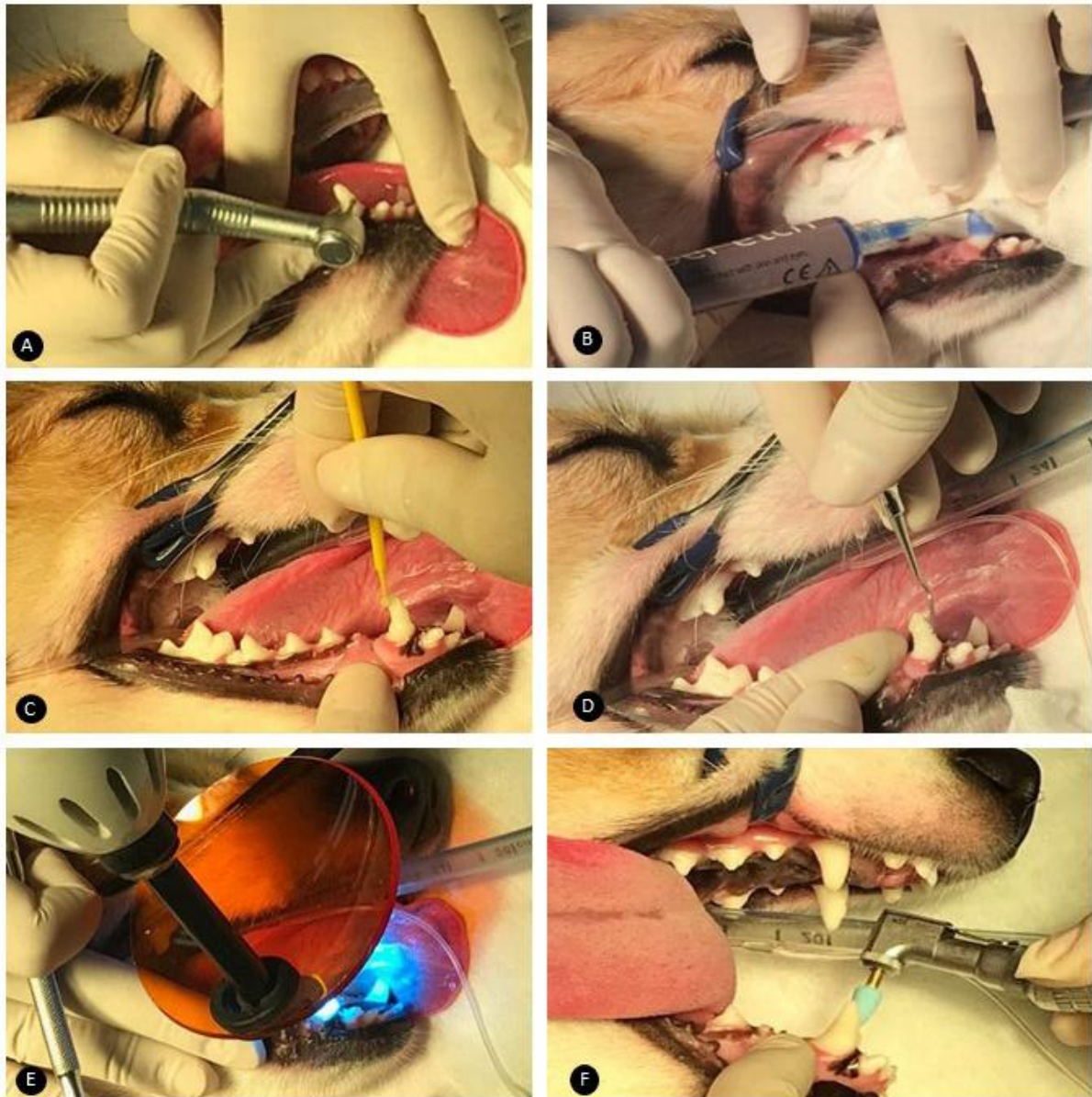


Figure 5 Composite restoration technique A) Removing the tooth roughness surface B) Acid etching the enamel C) Applying the bonding agent D) Placing the composite resin E) Initiation of polymerisation F) Final shaping and polishing.

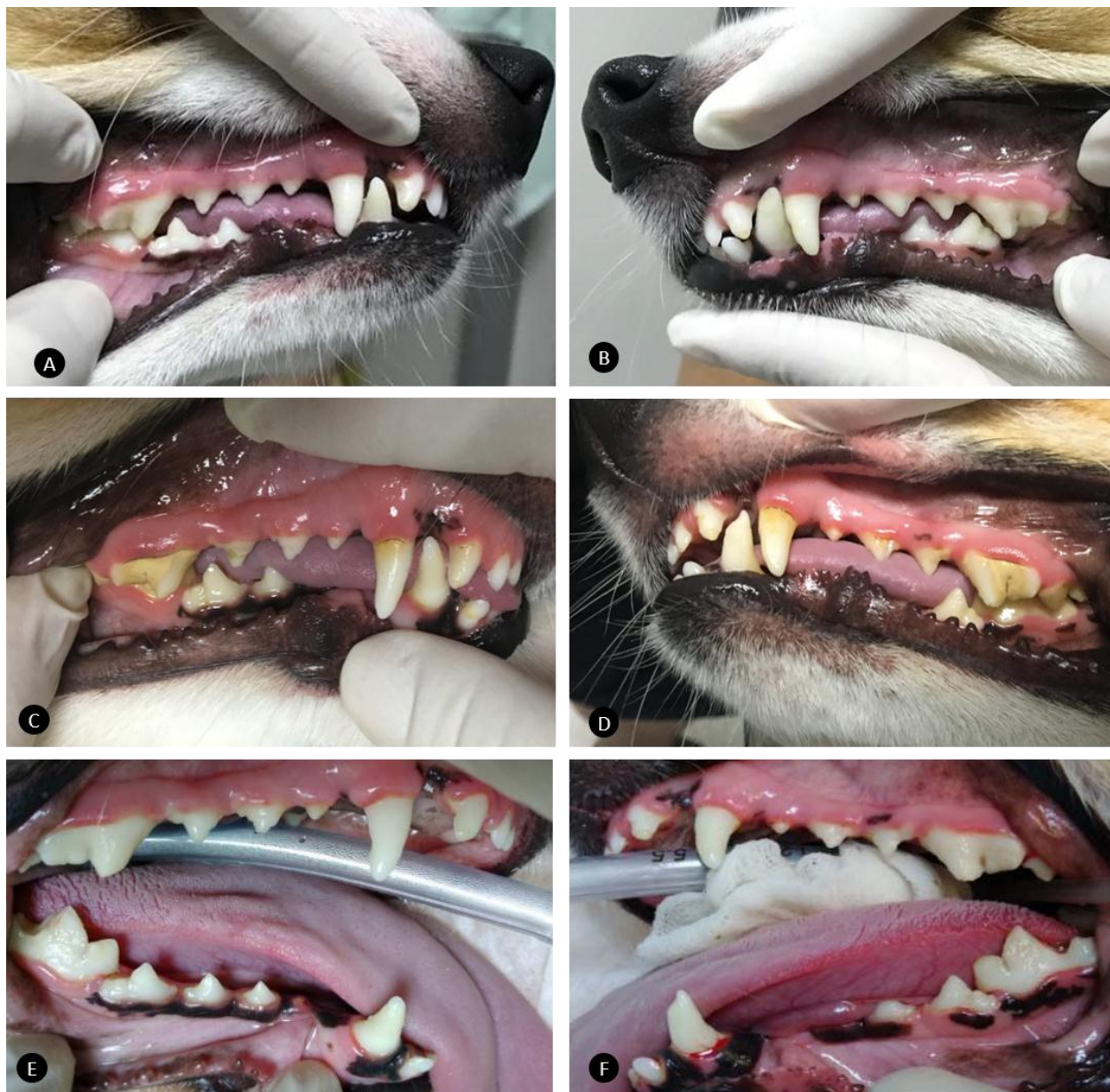


Figure 6 A-B) A week after treatment A) From the right side of the mouth, the patient's oral examination after restoration found more smooth of the teeth surface. B) The left side of the mouth showing results similar to the other side. C-D) Patient's oral examination 6 months after the restoration treatment C) From the right side of the mouth found smooth of teeth surface and some dental tartar accumulation and gingivitis D) from the left side of the mouth found missing material at 304 E-F) Patient's oral examination 1 year and 8 months after the restoration treatment and after dental scaling and polishing. Most of the restorative material remains intact.

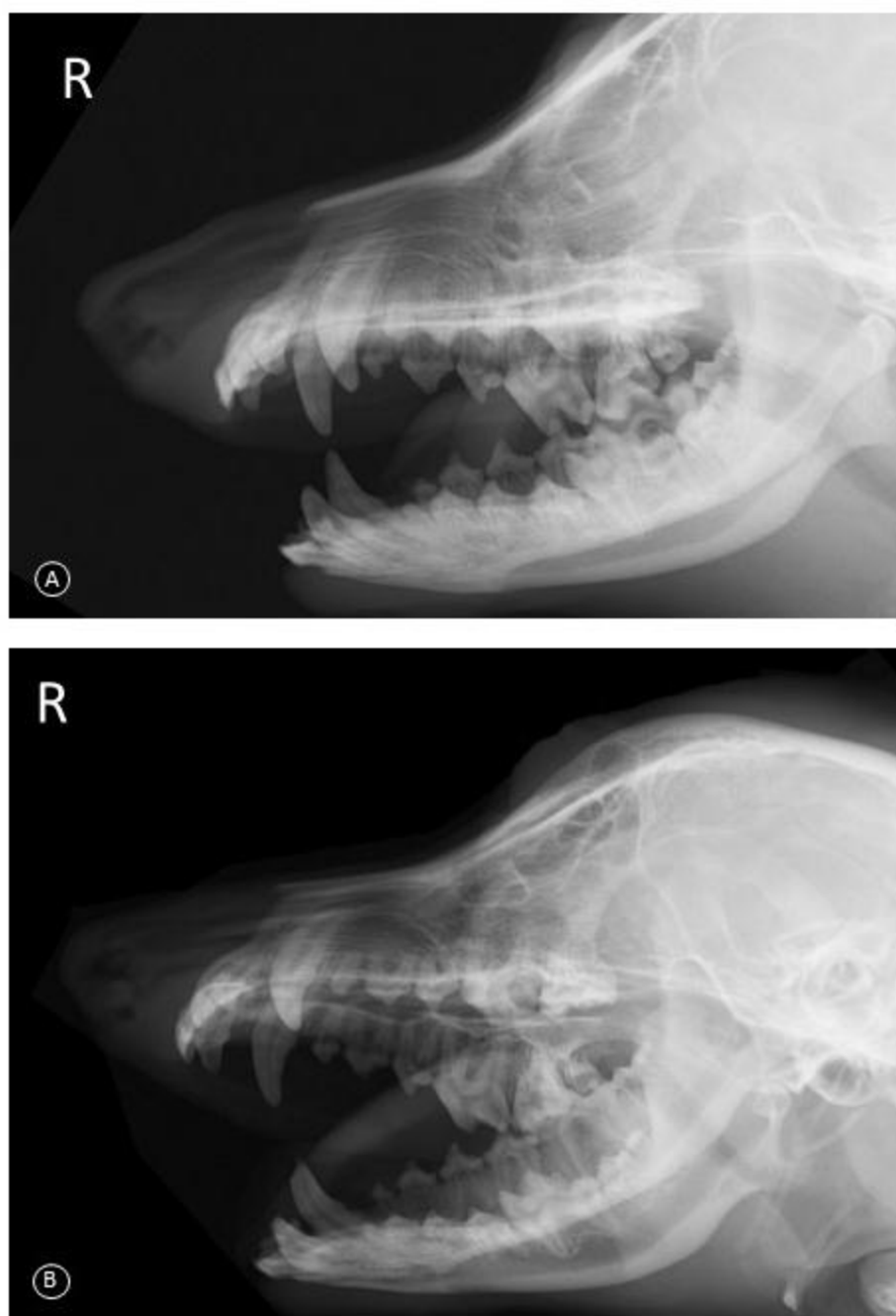


Figure 7 Radiographic examination result after A) a week of treatment and B) 6 months after treatment. A) Composite resin replace covered the defect without radiolucent area between material and teeth, unremarkable lesion of tooth root.

Discussion

Enamel, produced by ameloblasts during tooth development, acts as a barrier that protects the tooth pulp (Lobprise, 2019; Seow, 2014). However, it is not able to remodel after enamel formation is completed (Boy *et al.*, 2016). The etiology of enamel hypoplasia in dogs is divided into two categories consisting of hereditary factors including genetic and environmental influences. The reported breeds predisposed and with genetic defects for enamel hypoplasia were Standard Poodles, Italian Greyhounds and Samoyeds (Gandolfi B, 2013; Mannerfelt and Lindgren, 2009; Pedersen *et al.*, 2017). Ameloblasts are extremely sensitive to external stimuli (Boy *et al.*, 2016). There are many environmental

aspects causing enamel hypoplasia consisting of nutritional deficiencies, systemic diseases, epitheliotropic viral infections, pyrexia of any origins, disturbances of the metabolism, trauma and chemicals that are toxic to ameloblasts (Boy *et al.*, 2016; Niemiec, 2010; Wong, 2014). There are a small number of studies and no reports of Welsh Corgis as the breed predisposed or genetically at risk; in this dog, enamel hypoplasia, then, possibly occurs from environmental factors due to the patient's history.

The most likely environment factors causing enamel hypoplasia in our case were viral infections from parvovirus and coronavirus and pneumonia at 2 months of age. Both canine parvovirus and coronavirus are enteropathogens that generate gastrointestinal problems in canine species (Ettinger,

2017). In humans, severity of gastrointestinal disturbance can induce enamel hypoplasia from malabsorption and interference with calcium metabolism that affects enamel formation (Giro, 1947). Induced parasitism, *Trichostrongylus* spp. and *Ostertagia circumcincta*, in sheep reviewed hypoplastic lesions of the enamel suggested that gastrointestinal disturbance was the reason for disintegration of the ameloblast layer prior completed mineralization (Suckling G, 1983). Also, pneumonia has been reported in seriously ill children with ailments related to enamel defect (Grace W and Euan I, 1983). There have been studies suggesting that respiratory distress influences oxygen delivery causing interference during the mineralization of the enamel matrix (VE *et al.*, 2002; Wong, 2014). However, the exact pathophysiology of viral infection and respiratory problems inducing canine enamel hypoplasia is unclear. The other environmental factor which possibly caused enamel hypoplasia in this dog was pyrexia. It is well known that pyrexia during enamel development can cause enamel hypoplasia. In an experimental induced-fever, rats, incubated at 102-105 °F for 24 hours, reported histopathological changes consisting of: abnormal secretion of enamel matrix, vacuolization of ameloblasts, complete cystic destruction of ameloblasts and notch-like defects (Kreshover, 1944; Kreshover and Clough, 1952).

Other environmental factors such as nutritional deficiencies and medication were unlikely to have caused enamel hypoplasia in this case due to the dog being fed a proper commercial diet and never receiving any drug that induced enamel defect. A study in rats showed that the lack of vitamin A and D can cause enamel hypoplasia (JT *et al.*, 1984). In a previous treatment, our patient had been receiving doxycycline during illness. Tetracycline antimicrobial drug reacts with the teeth due to its chelated effect. This drug can bind irreversibly with calcium orthophosphate and generate a complex that affects the teeth during the formation stage and causes discoloration of the teeth (Boy *et al.*, 2016). Doxycycline has been classified as a derivative of tetracycline, nonetheless some studies have shown no effect on enamel structure when using this drug in either animals or humans (Schulz *et al.*, 2011; SR *et al.*, 2015).

Practically, enamel hypoplasia was mainly diagnosed by clinical appearance and history taking. We performed a full oral examination using dental explorer probing. In addition, radiography should be performed to evaluate root status and detect other lesions including pulp and periapical problem, which might affect treatment plans (Niemic, 2010). Once the clinical signs are noted, finding the etiologies might be difficult and sometimes unnecessary because the enamel lesion was similar regardless of the primary cause (Wong, 2014). Moreover, the management and treatment were not different. The environmental etiology of this disease could be prevented by suitable caring, vaccination, hygiene, proper diet and dental management (Holmtsrom, 2013).

Enamel is responsible for protecting the dentin by covering the outer layer of the tooth (Lobprise, 2019). Once defective enamel occurs, its structure becomes weak followed by shedding off which makes the

irregular surface and dentin become easily exposed (Niemic, 2010). Therefore, the goals in treating enamel hypoplasia are smoothing the tooth surface to reduce plaque accumulation and eradicating sensitivity areas to prevent endodontic infection, by sealing the dentin (Niemic, 2010; Tutt, 2006). In our patient, we used a restoration technique. This technique was suggested as the most accomplished and the treatment of choice for managing enamel hypoplasia in dogs (Niemic, 2010). Composite restoration also resolves esthetic problems and can be performed in practice by specialist veterinarians (Holmtsrom, 2013). There are many types of composite resin used in dentistry. The type of composite resin depends on the filler particle or combination of size. Nanohybrid composite resin material, a universal composite resin, was selected in this case. The advantage of material that we used is high strength, high modulus and high polish (Lobprise, 2019). However, composite restoration can be delicate in high stress-bearing areas, therefore alternative methods are prosthetic crown placement and extraction (Lobprise, 2012, 2019). The indications for prosthetic crown placement are; 1) high stress area such as premolar teeth; 2) covering large lesions; 3) a high chance of tooth fracture such as working dogs (Lobprise, 2012). The limitations of prosthetic crown placement are it is more expensive and needs more advanced skill (Holmtsrom, 2013; Lobprise, 2012). Extraction technique is one of the methods that can be applied for enamel hypoplasia but veterinarians should bear in mind the first rule of dentistry surgery is to preserve the natural tooth structure (Lobprise, 2019). This method is recommended for localized (single tooth) enamel hypoplasia with severe tooth root abnormality to prevent endodontic disease (Niemic, 2010).

The composite resin material was clinical efficient for over 8 years in humans (R *et al.*, 2014). There was no study of the durability of the composite material in dogs because there are many factors that can decrease the lifetime of the material. Therefore, prognosis for the teeth is dependent on the dog's behavior; it should avoid biting on hard objects and avoid inappropriate chewing and practice routine oral management. Veterinarians should recheck oral examinations every 6 to 18 months, to evaluate the management of the owner and the persistence of material, and perform radiography to check the root status or other problems (Gorrel, 2008; Holmtsrom, 2013). This monitoring should be done to prevent the development of more severe further problems.

In conclusion, even though enamel hypoplasia is rare, this condition remains an important problem that can lead to severe problems in dental status in the future. To diagnosis this condition veterinary surgeons should be aware of the abnormalities including clinical appearance, pathogenesis and etiologic factors that may lead to an accurate diagnosis. Early diagnosis results in appropriate treatment. An effective treatment of this condition is restoration technique, which aims to remove sensitivity areas, avoid endodontic infection and decrease plaque and dental calculus accumulation. After treatment, routine follow up should be performed to evaluated pulp and root health. Client education is a main factor for successful

understanding of the condition and home care management and regular examination by the owner will provide important information of any abnormality and composite material status.

Conflict of interests: The authors declare that there is no conflict of interests.

Acknowledgements

The authors are most grateful to the owner for information and permission. The authors are very grateful to Prasu-Arthorn Animal Hospital, Faculty of Veterinary Science, Mahidol University for providing patient information, anesthesia and dental facilities and equipment. Thanks are due to Dr. Panutda Darapong from Ladkrabang Animal Hospital, Thailand for the patient follow up at 20 months, information and photos.

References

- Boy, S., Crossley, D., Steenkamp, G., 2016. Developmental Structural Tooth Defects in Dogs – experience From veterinary Dental Referral Practice and Review of the Literature. *Frontiers in Veterinary Science* 3: 9, 1-13.
- Boy, S., Crossley, D., Steenkamp, G., 2016. Developmental Structural Tooth Defects in Dogs – experience From veterinary Dental Referral Practice and Review of the Literature. *Frontiers in Veterinary Science* 3: 9, 1-13.
- Dubielzig, R.R., Higgins, R.J., Krakowka, S., 1981. Lesions of the Enamel Organ of Developing Dog Teeth Following Experimental Inoculation of Gnotobiotic Puppies with Canine Distemper Virus. *Vet. Pathol* 18(5), 684-689.
- Ettinger, S.J., 2017. *Textbook of Veterinary Internal Medicine: disease of the dog and cat*, In: Infectious disease, 8th ed. Elsevier, Inc, pp. 2456-2488.
- Gandolfi B, L.H., Griffioen L, Pedersen NC, 2013. Simple recessive mutation in ENAM is associated with amelogenesis imperfecta in Italian Greyhounds. *Animal genetics* 44(5), 569-578.
- Giro, C.M., 1947. Enamel hypoplasia in human teeth an examination of its cause. *J.D.D.A* 34, 310-317.
- Gorrel, C., 2008. *Saunders Solutions in Veterinary Practice: Small Animal Dentistry*, In: Enamel dysplasia. Saunderson Elsevier, UK, pp. 620-632.
- Grace W, S., Euan I, F., Pearce, 1983. Developmental defects of enamel in a group of New Zealand children: their prevalence and some associated etiological factors. *Oral Epidemiology*, 177-184.
- Hale, F.A., 2005. Juvenile Veterinary Dentistry. *Veterinary Clinic Small Animal Practice* 35, 789-817.
- Holmstrom, S.E., 2013. Veterinary Dentistry: A team approach, In: *Advance Veterinary Dental Procedure*, 2nd ed. Elsevier Saunders, Missouri, pp. 326-331.
- JT, P., S, H., SS, H., JM, N., 1984. Effects of vitamin A deficiency on rat incisor formation. *J Oral Pathol* 13, 40-51.
- Kanchan, T., Machado, M., Rao, A., Krishan, K., Garg, A.K., 2015. Enamel hypoplasia and its role in identification of individuals: A review of literature. *Indian Journal of Dentistry* 6, 99-102.
- Kreshover, S.J., 1944. The Pathogenesis of Enamel Hypoplasia: An experimental study. *Journal of Dental Research* 23 (4), 231-238.
- Kreshover, S.J., Clough, O.W., 1952. Prenatal Influences on Tooth Development. *Journal of Dental Research* 32(4), 565-577.
- Kyllar, M., Witter, K., 2005. Prevalence of dental disorders in pet dogs. *VETERINARNI MEDICINA-PRAHA* 50(11), 496-505.
- Lobprise, H.B., 2012. *Blackwell's Five-Minute Veterinary Consult Clinical Companion Small Animal Dentistry*, In: *Oral/Dental Disease (Developmental Oral/Dental Problems)*, Wiley-Blackwell ed. Wiley-Blackwell, Texas, pp. 152-157.
- Lobprise, H.B., 2019. *Wiggs's veterinary dentistry : principles and practice*, 2nd ed. Wiley Blackwell, John Wiley & Sons, Inc.
- Mannerfelt, T., Lindgren, I., 2009. Enamel Defects in Standard Poodle Dogs in Sweden. *Journal of Veterinary Dentistry* 26(4), 213-215.
- Niemiec, B.A., 2010. Small Animal Dental, Oral & Maxillofacial Disease, In: *Pathology in the Pediatric Patient*, softcover ed. Manson Publishing Ltd, UK, pp. 122-124.
- P, Z., E, A., P, M.B., 2016. Prevalence of oral diseases in dogs in Tirana urban area. *Indian Journal of Animal Research* 50(5).
- Pedersen, N.C., Shope, B., Liu, H., 2017. An autosomal recessive mutation in SCL24A4 causing enamel hypoplasia in Samoyed and its relationship to breed-wide genetic diversity. *Canine Genetics and Epidemiology*, 1-20.
- R, F., C, R., N., K., 2014. Nanohybrid vs. fine hybrid composite in extended class II cavities: 8-year results. *Clinical oral investigations* 18(1), 125-137.
- Schulz, B.S., Hupfauer, S., Ammer, H., Sauter-Louis, C., Hartmann, K., 2011. Suspected side effects of doxycycline use in dogs – a retrospective study of 386 cases. *Veterinary Record*, 1-4.
- Seow, W., 2014. Developmental defects of enamel and dentine: challenges for basic science research and clinical management. *Australian Dental Journal* 59(1), 143-154.
- SR, T., FS, D., MS, T., ED, B.-A., DW, M., C, H., JH, M., JJ., R., 2015. No visible dental staining in children treated with doxycycline for suspected Rocky Mountain spotted fever. *The Journal of pediatrics* 166(5), 1246-1251.
- Suckling G, E.D., Thurley DC, 1983. The production of developmental defects of enamel in the incisor teeth of penned sheep resulting from induced parasitism. *Archives of Oral Biology* 28(5), 393-399.
- Tutt, C., 2006. *Small Animal Dentistry A manual of technique*. Blackwell Publishing Ltd, - VE, B., KL, W., HJ, G., 2002. Factors involved in the aetiology of molar-incisor hypomineralisation (MIH). *European Journal of Paediatric Dentistry* Mar;3, 9-13.
- Wong, H.M., 2014. Aetiological Factors for Developmental Defects of Enamel. *Austin Journal of Anatomy* 1, 1-9.