

# The use of human suprapubic bladder catheter to manage obstructive urolithiasis in a Saanen Buck

Nurul Hayah Khairuddin<sup>1\*</sup> Mark Wen Han Hiew<sup>2</sup> Syahirah Ahmad Affandi<sup>1</sup>

Azim Salahudin Muhamad<sup>1</sup> Nur Asyikin Haron<sup>1</sup> Rozanaliza Radzi<sup>2</sup>

Chen Hui Cheng<sup>3</sup> Ganesh Vythilingam<sup>4</sup>

## *Abstract*

A three-year-old Saanen buck presented with a complaint of stranguria for 24 hours. A physical examination revealed that the perineal urethra was turgid, swollen, and tender, and the urinary bladder was distended. The goat was diagnosed with obstructive urolithiasis. A percutaneous tube cystotomy technique was performed to relieve progressive urinary bladder distension. Using a human suprapubic urinary bladder catheter system, the technique was performed twice due to the recurrence of the blocked urethra. Following drainage of the urine, all vital parameters returned to normal. After surgical cystotomy, an intraoperative observation revealed the urinary bladder was filled with white sandy urolith, which was removed through the surgical tube cystotomy technique. A preoperative urethrogram and cystourethrogram were performed to assess the presence of urolith along the urinary tract. The case outcome supports using a human suprapubic urinary bladder catheter as a rapid method for immediate relief of a distended urinary bladder in a goat.

---

**Keywords:** Goat, obstructive urolithiasis, suprapubic bladder catheter, cystourethrogram

<sup>1</sup>Department of Medicine and Surgery of Farm and Exotic Animals, Faculty of Veterinary Medicine, Universiti Putra Malaysia, 43400 UPM Serdang, Selangor, Malaysia

<sup>2</sup>Department of Veterinary Clinical Studies, Faculty of Veterinary Medicine, Universiti Putra Malaysia, 43400 UPM Serdang, Selangor, Malaysia

<sup>3</sup>Department of Companion Animal Medicine and Surgery, Faculty of Veterinary Medicine, Universiti Putra Malaysia, 43400 UPM Serdang, Selangor, Malaysia

<sup>4</sup>Department of Surgery, Faculty of Medicine University Malaya Jalan Universiti, 50603 Kuala Lumpur, Wilayah Persekutuan Kuala Lumpur, Malaysia

\*Correspondence: nurulhayah@upm.edu.my, nurul.leman82@gmail.com (N. H. Khairuddin)

Received: August 20, 2020.

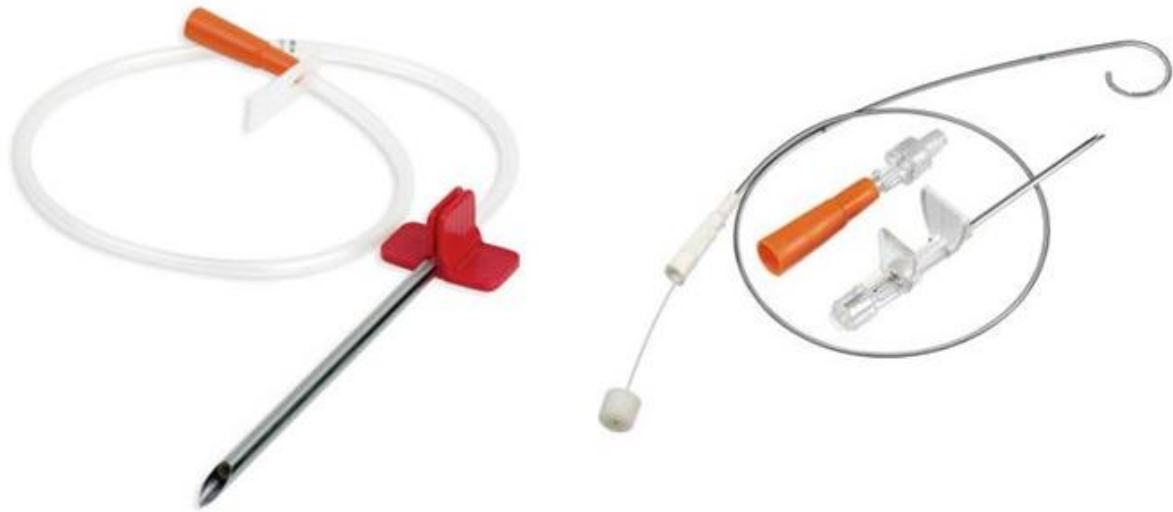
Accepted: February 17, 2021.

doi: <https://doi.org/10.14456/tjvm.2021.48>

## Introduction

Obstructive urolithiasis in male goats is a challenging condition to treat as it possesses a high recurrence rate. The most common site for obstruction is at the sigmoid flexure of the urethra and the urethral process (Ewoldt *et al.*, 2008; Jones *et al.*, 2012; Khairuddin *et al.*, 2016; Videla and Van Amstel, 2016). Without surgical intervention, a completely blocked urethra will result in progressive urinary bladder distension and bladder rupture leading to septicaemia and death (Tan *et al.*, 2017). Previous studies have described several procedures, including amputation of the urethral process, urethral catheterisation, retrograde and normograde urohydropropulsion, urethrography, cystourethrography, urinary bladder tube cystotomy, percutaneous bladder cystotomy, and perineal urethrostomy. These procedures are among the diagnostic and treatment options available to help

resolve and manage urinary obstruction in this species to relieve distended urinary bladder, prevent systemic imbalances that lead to azotaemia, and retaining breeding capacity (Fortier *et al.*, 2004; Haven *et al.*, 1993; Khairuddin *et al.*, 2016; Rakestraw *et al.*, 1995; Van Metre and Fubini, 2006). In humans, a suprapubic catheter is used to place a drainage tube into the urinary bladder above the pubic symphysis when urethral access is not possible or advisable (Goyal and Sankhwar, 2012; Corder and LaGrange, 2020). This is an experience-sharing report on the ready to use catheter set, which is human suprapubic percutaneous urine catheterisation known as Cystofix® puncture set by B. Braun to manage obstructive urolithiasis in an intact male goat. The catheters are made of polyurethane with curled pigtail (J) tip and depth markings to facilitate percutaneous insertion of the catheter into the urinary bladder (Figure 1).



**Figure 1** Different sizes of the suprapubic bladder catheter system; Adult Cystofix® system- left; Neonatal Cystofix® system- right. The catheters are made of polyurethane with curled pigtail (J) tip and depth markings to facilitate percutaneous insertion of the catheter into the urinary bladder.

## Case Details

**History:** A three-year-old Saanen male goat was brought to the University Veterinary Hospital (UVH) after being unable to pass urine for 24 hours. The goat was managed semi intensively and serves as breeding stock. The goat was fed with a commercial goat pellet in the morning and has access to grass paddock daily. The goat owner reported that the goat experienced a similar problem four months ago, and a veterinarian has been consulted. A urethral process amputation is believed to have been performed on the goat. The problem was resolved but then recurred for a second time.

**Clinical Findings:** Upon physical examination, the animal was in a dull state and is straining to urinate. The body condition score is 4 out of 5, the body temperature is within a normal range, but with increase respiratory and heart rates. On physical

examination showed that the urethra in the perineal region was turgid, swollen, and tender upon palpation. The urinary bladder was noted to be distended on deep palpation, and this was confirmed by ultrasonography.

**Diagnostic Workup:** A blood sample was sent for a complete haemogram and serum biochemistry testing. A blood smear result showed neutrophilia with left shift and monocytosis, indicating infection and inflammation. Biochemistry results revealed hyperproteinaemia, sodium, and chloride at high normal, potassium level at low normal, and hypocalcaemia, suggesting urine retention in the bladder. Urinalysis showed that the urine was turbid, exhibiting acidic pH and erythrocytes, indicating urinary tract disease. A detailed examination of the penis necessitated sedation (Diazepam 0.1 mg/kg bolus, IV, top-up 0.05 mg/kg, IV). Upon examination, the urethral process seemed to have been amputated, and bits of stones could be palpated proximal to the

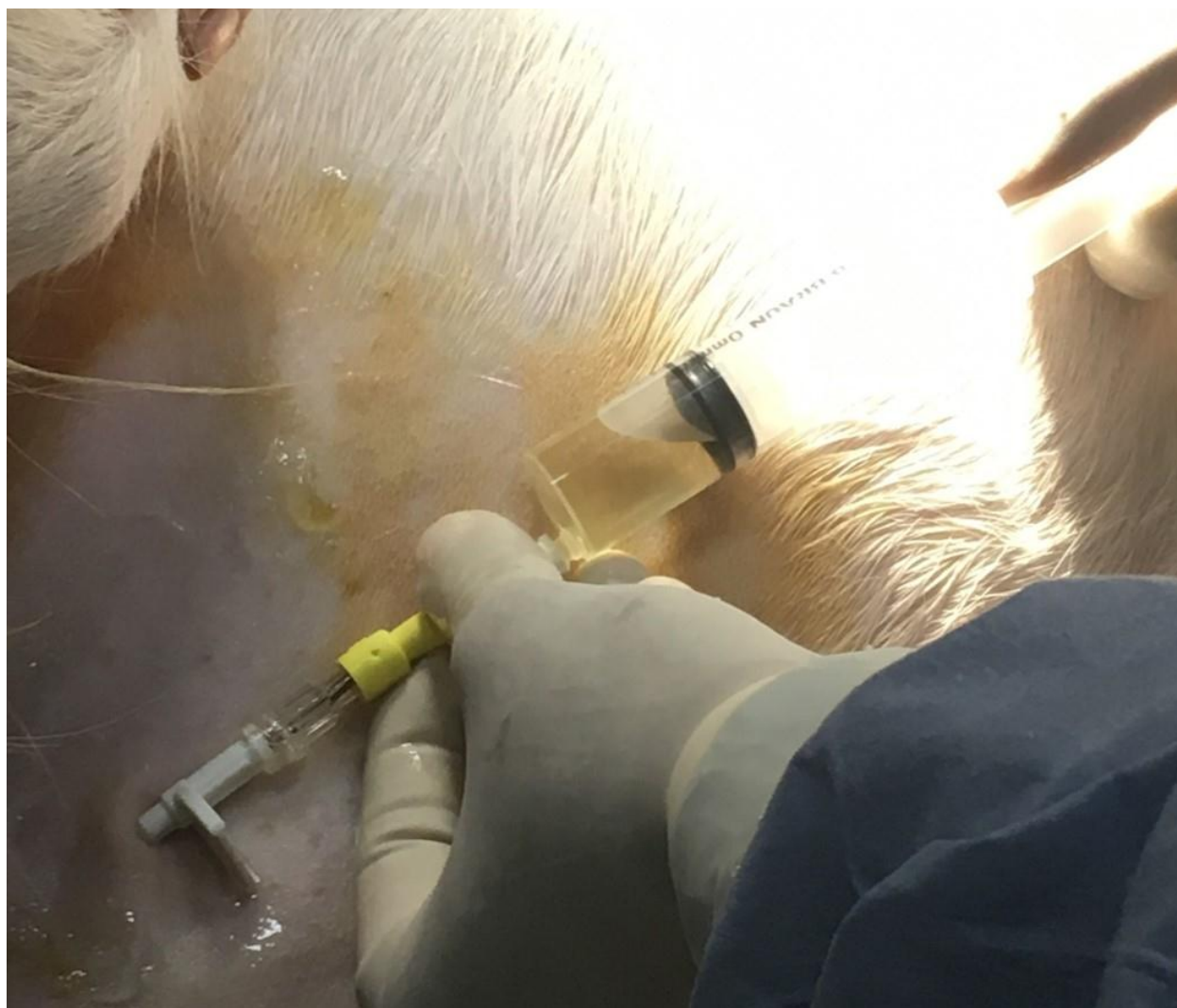urethral process. An attempt was failed to milk out the stone through the urethral opening. Therefore, a small incision was made on the urethral wall in which the stone was situated to ease the stone's evacuation process. Multiple white stones of about 2 mm in size were evacuated, and the incision was closed with 7-0 absorbable suture material using an interrupted suture pattern (7-0 Vicryl).

**Percutaneous tube cystotomy technique:** In order to relieve the progressive bladder distension, a percutaneous tube cystotomy technique was performed using a human suprapubic bladder catheter (Neonatal Cystofix® 5Fr-B. Braun) with ultrasonographic guidance under infiltrative local anaesthesia at the site of puncture at the abdominal region. The goat was sedated (Diazepam 0.1 mg/kg bolus, IV, top-up 0.05 mg/kg, IV) and placed on lateral recumbency with one hindleg was extended to allow approach to the caudoventral region of the abdomen. The condition of the fully distended bladder made the insertion of the Cystofix® system easy. The correct placement of the tip of the catheter at intrabladder was confirmed by ultrasonography. The stylet of the

system was fixed to the abdominals' skin wall (Figure 2), and 400 ml of clear urine was removed from the stylet of the bladder catheter. The Elizabethan collar was placed on the goat to prevent it from chewing the catheter tube, and the goat was taken into the pen.

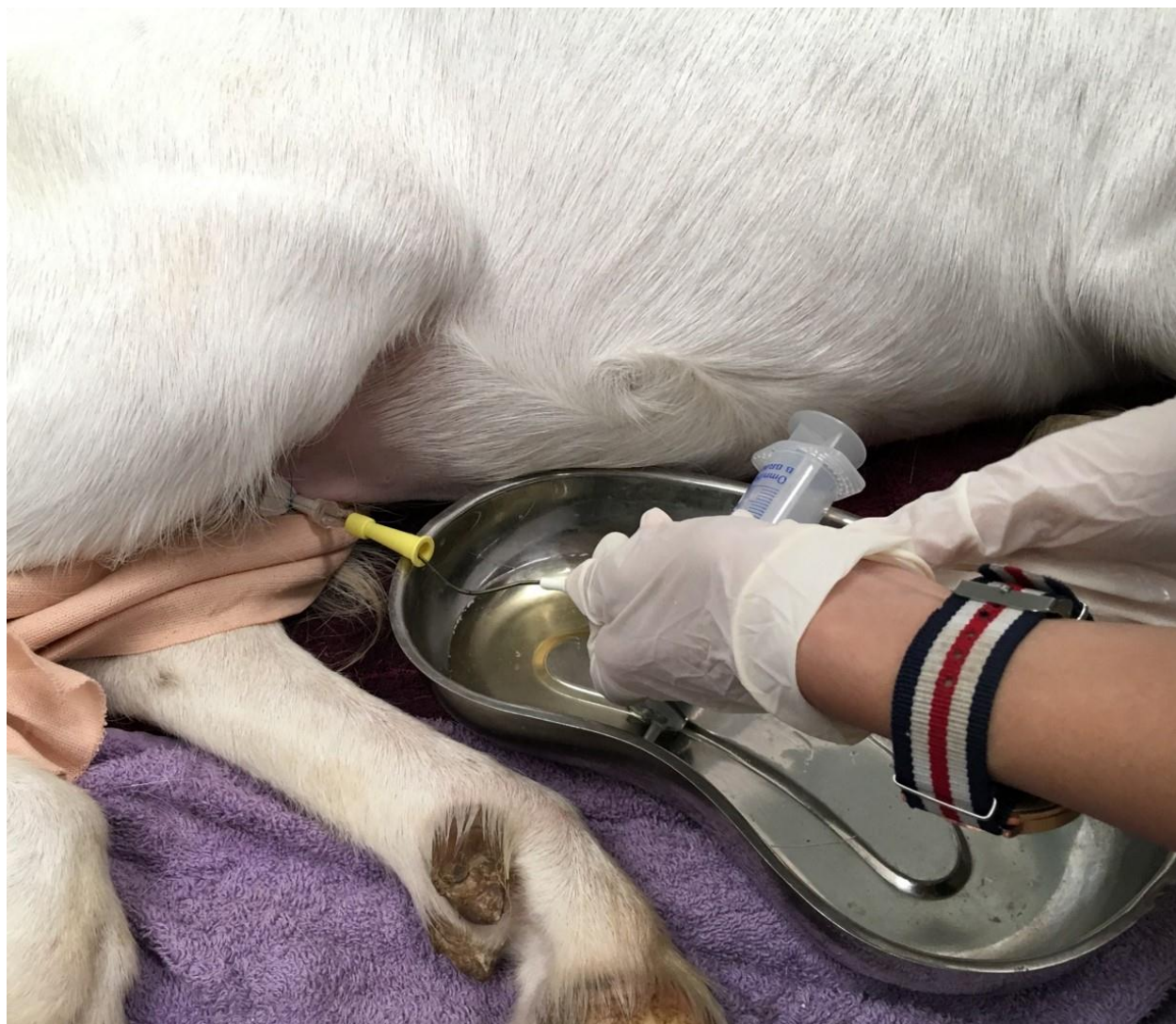The bladder catheter was kept open, and the bladder catheter's urine aspiration was performed hourly for the first 4 hours (Figure 3). Around 500 ml of urine were removed every hour, and dribbled urine was collected in a kidney bowl.

**Progress:** Upon insertion of the bladder catheter system and every hour of urine aspiration, the goat was finally urinating from the urethra. Urinalysis of the first day of hospitalisation revealed that the urine was acidic (pH5). The next day of hospitalisation showed an improvement on the goat with bright and alert, urinating from the urethra, and all parameters were improved. The swelling of the urethra at the incision site was markedly reduced with neutral pH urine. The urinary bladder catheter was closed periodically following 48 hours of normal urethral patency.



**Figure 2** A percutaneous urinary bladder tube fixation using a Cystofix® system on the abdominal wall of the goat.





**Figure 3** Periodic withdrawal of urine from the Cystofix® system in a goat.

The goat was given Lactated Ringer's solution at a replacement rate of 50 ml/kg/day. Enrofloxacin antibiotic (5 mg/kg, SID, Baytril 5%) was administered intravenously for five days. Flunixin meglumin (2.2 mg/kg, intramuscularly, once), tramadol (5 mg/kg, subcutaneously), and meloxicam (0.2 mg/kg, subcutaneously) as analgesic and anti-inflammatory were given twice a day for 3 days and once daily for another 3 days.

The goat remained stable with an intact catheter in the bladder with patency of urethral flow for several days. However, on the 7<sup>th</sup> day, the goat managed to remove the catheter and was not urinating for 10 hours. The goat tried to urinate and had a distended bladder on ultrasound examination. Due to urinary blockage recurrence, a plan for a cystotomy procedure was scheduled for the next day.

A bladder catheter using the Cystofix® system was inserted percutaneously (Adult Cystofix®, B. Braun, 3.6 mm diameter). A different size was used due to the unavailability of the neonatal size system. The stylet was kept open to allow for continuous urinary drainage overnight. The aspiration of urine from the Cystofix® stylet was achieved with resistance, and urine flow from the urinary bladder has also reduced.

The goat has to fast to prepare for the next day's cystotomy procedure.

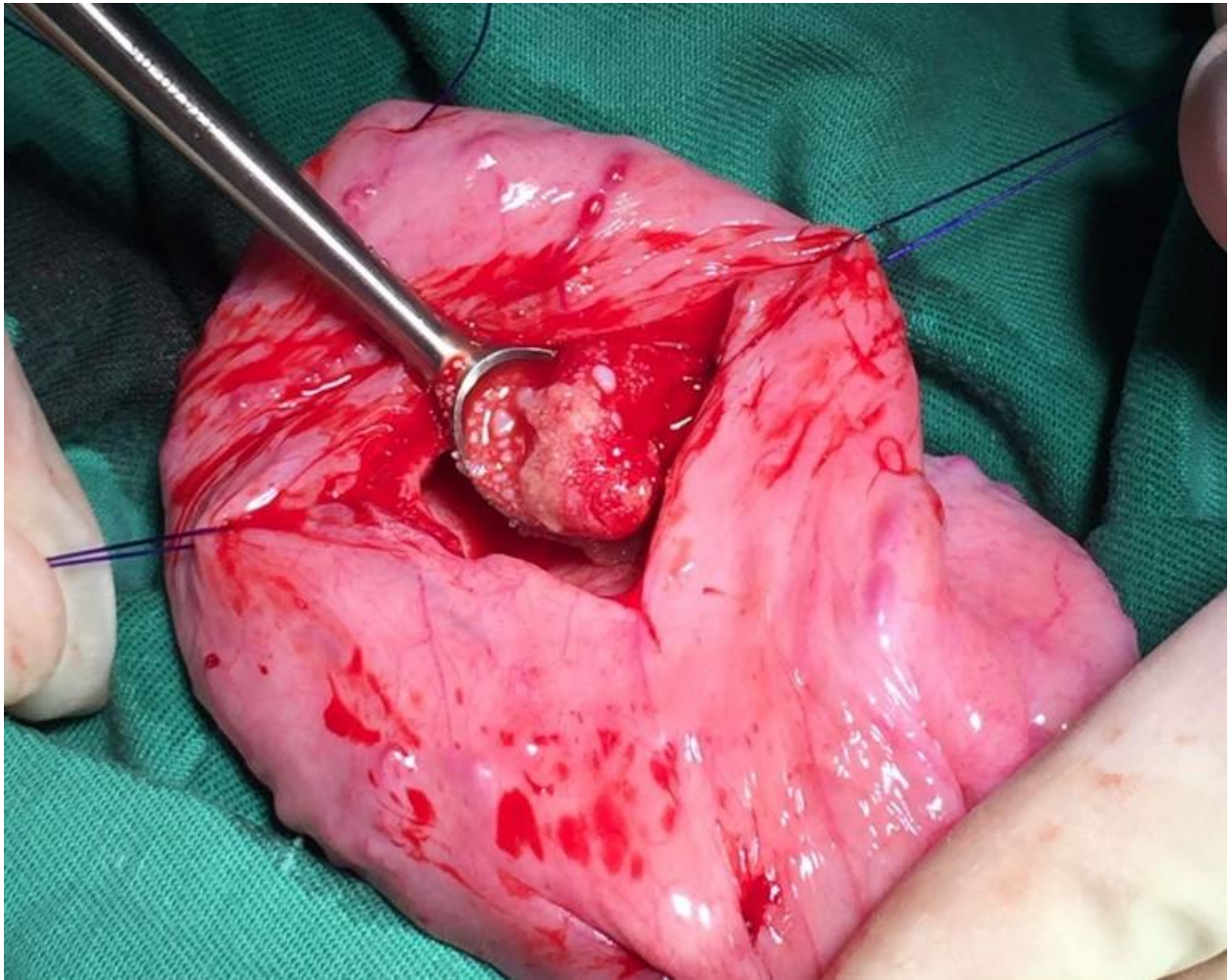
### *Surgical Procedures*

The goat was induced with a combination of ketamine hydrochloride (2.2 mg/kg) and diazepam (0.05 mg/kg) intravenously. Anaesthesia was maintained with 3-5% isoflurane via an endotracheal tube (size 10.5). Before cystotomy, the goat was catheterised using a dog Buster urinary catheter (2 mm × 70cm). A retrograde urohydropropulsion was performed to flush the urethroliths into the urinary bladder. The use of a more rigid plastic dog Buster urethral catheter used intraoperatively was able to pass the sigmoid flexure as the goat retractor penile muscle was fully relaxed under general anaesthesia.

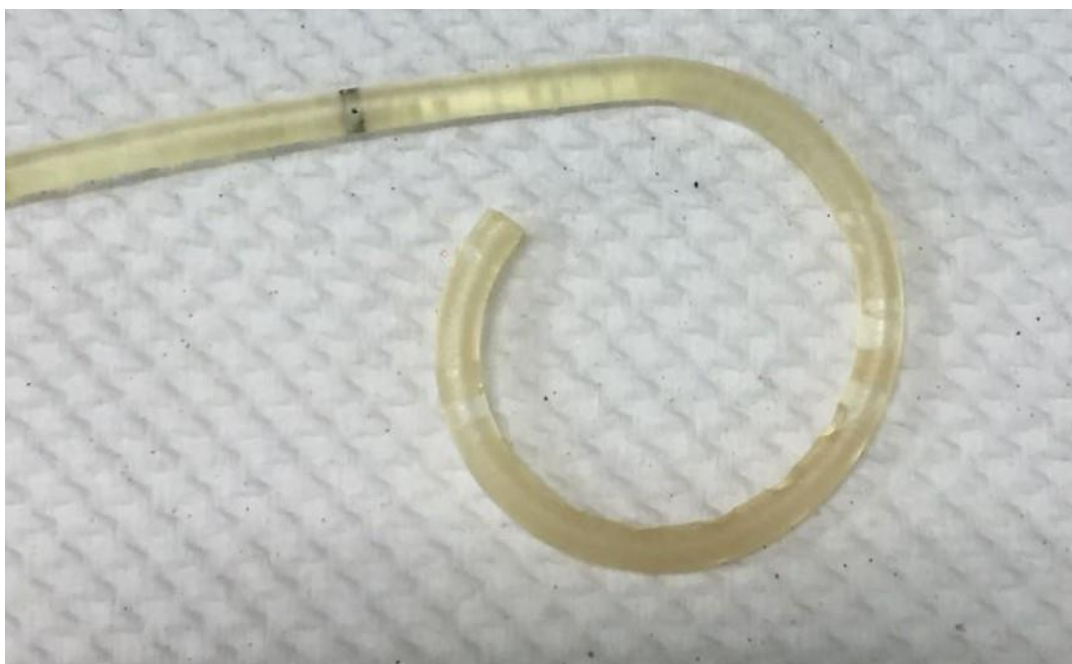A caudal paramedian skin incision was followed by entry into the abdominal cavity. Stay sutures were placed on the urinary bladder's ventral aspect, and a 1cm stab incision was made followed by suction to remove the urine. Then the cystotomy incision was extended, and in situ observation revealed that the bladder was filled with white sandy urolith that was successfully removed (Figure 4).

The intrabladder was then lavaged with warm sterile saline. A 10Fr Foley catheter (Pharmaniaga) was introduced into the bladder via the cystotomy site and sutured routinely with a 2-layer closure using Vicryl 4/0 (Ethicon, USA) and inflated. The distal end of the

Foley catheter exited through the paramedian skin incision and was secured on the abdominal skin. The Cystofix® tube was then removed (blocked with abundant white sandy uroliths) (Figure 5), and the celiotomy was then closed routinely.



**Figure 4** Urinary bladder was filled with white sandy urolith and was removed with a bladder spoon.



**Figure 5** The lumen of the Cystofix® tube was blocked with white sandy uroliths.



### Progress Post Surgery

The goat was maintained with analgesia and anti-inflammatory of flunixin meglumine (2.2 mg/kg, intramuscularly) and continued on enrofloxacin antibiotic (5 mg/kg, SID, Baytril 5%). The use of fluoroquinolone drug was justified since the goat is a pet, not a food-producing animal. The goat was monitored for urine output and flow from the Foley catheter and the urethral catheter.

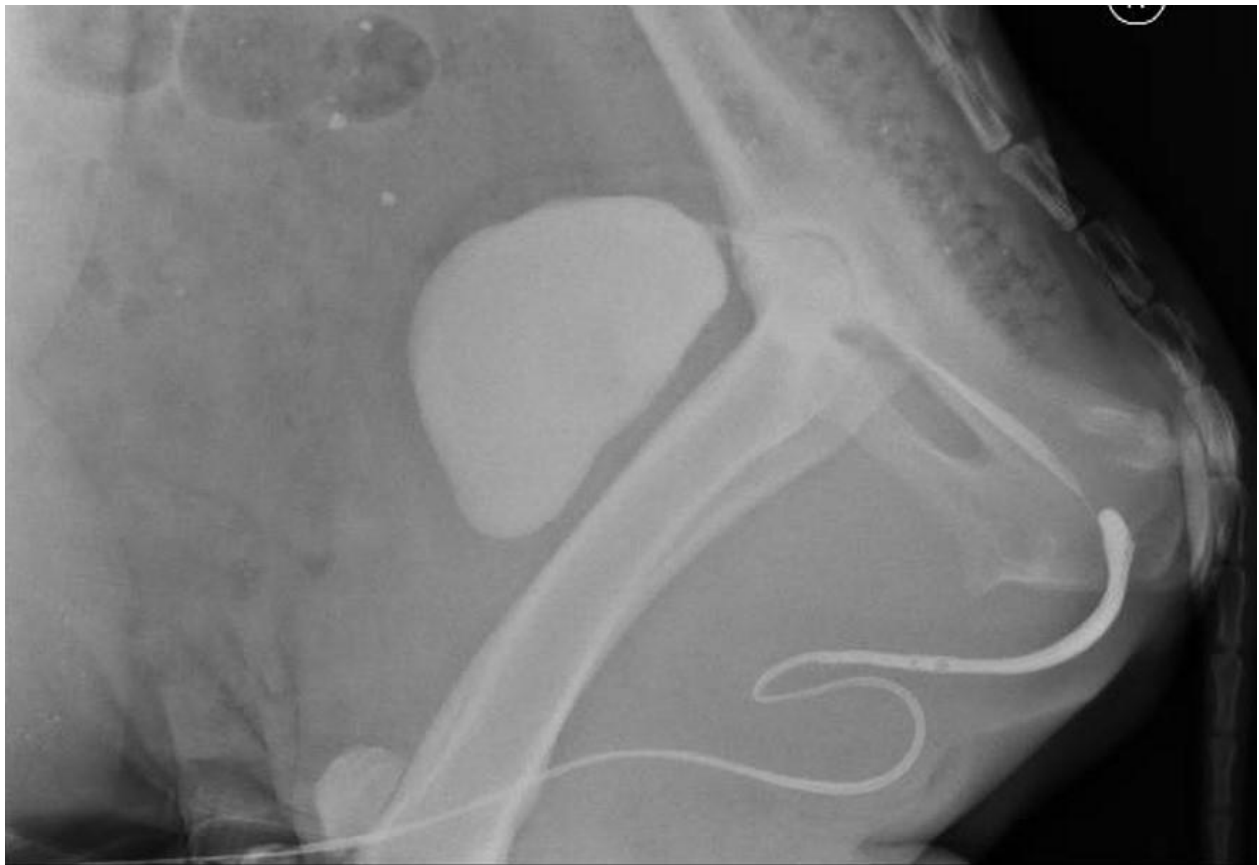The third day after the surgery, the goat underwent a urethrogram and cystourethrogram. A contrast material calculated at 0.5 ml/kg (Omnipaque Iohexol, GE Healthcare) was first injected into the bladder via a Foley catheter, and the bladder was then compressed to eject the contrast material into the urethra. The contrast material's calculated dosage was based on the dosage used for a large dog with a similar procedure. Due to the abdomen's broad size, this technique was not efficient on the goat. The contrast material was increased and injected into the bladder until it began to flow to the neck of the bladder and urethra. The contrast material was also injected into the urethral catheter. The contrast material flow was smooth except

when the contrast reaches the part of the urethra inside the pelvic inlet, which was believed to be near the diverticulum of the urethra. About 25-30 ml of the contrast material was injected via the Foley catheter to fill the bladder of a 40 kg goat. Another 10-12 ml of contrast material was injected through the urethral catheter; however, there was a resistance.

Based on a series of radiographic images, few uroliths in the urethra and the flow of contrast were obstructed at the pelvic region level. This blockage could be attributed to urolith in the urethra, as well as urethral stricture and stenosis at the level of the pelvic region (Figure 6).

A recurrent blockage is to be expected upon removal of the urethral and bladder catheters based on the radiographic images. A final decision was made to conduct humane euthanasia to end the goat's suffering.

The urolith samples were sent to Minnesota Urolith Centre, under the Minnesota Urolith Programme, to diagnose the type of the urolith collected from the urethra and the bladder of the goat. The result showed that all uroliths were magnesium calcium phosphate apatite form.



**Figure 6** Cystourethrography and urethrography revealed the presence of urolith and stenotic urethra at the level of the pelvic inlet.

### Discussion

In male goats, the urolith is the most common obstruction site at the sigmoid flexure of the urethra and the urethral process (Ewoldt *et al.*, 2008; Haven *et al.*, 1993; Jones *et al.*, 2012). Catheterisation of the urethra was difficult due to the sigmoid flexure in the urethra of goats (Khairuddin *et al.*, 2016). Furthermore, male goats have a urethral diverticulum or recess that

communicates with the urethra and contains bulbourethral glands' ducts (Jones *et al.*, 2012). Although the urethral catheter passed the sigmoid flexure, the urethral diverticulum will prevent the catheter from entering the urinary bladder. Therefore, to achieve urinary drainage, there is an indication for bladder catheterisation. A suprapubic bladder catheter is common in humans when urethral catheterisation is

not feasible due to traumatic urethral catheterisation or urethral stricture (Goyal and Sankhwar, 2012).

Suprapubic catheter placement varies depending on the techniques. Open and percutaneous techniques with Foley catheters are commonly used as draining catheters. The open technique requires direct access to the bladder with a small cystotomy. The drainage tube is placed and secured onto the bladder wall with purse-string sutures, and the other parts of the catheter were secured to the abdominal skin (Goyal and Sankhwar, 2012; Corder and LaGrange, 2020). This technique is similar to the urinary bladder tube cystotomy technique described in veterinary field (Haven *et.al.*, 1993; Rakestraw *et. al.*, 1995; Fortier *et.al.*, 2004; Ewoldt *et al.*, 2006; Van Metre *etal.*, 2006; Khairuddin *et.al.*, 2016).

In humans, the percutaneous (Seldinger) technique can be performed with ultrasonographic guidance or visualisation with cystoscopy. This technique is commonly performed under local infiltrative anaesthesia, usually at the bedside. In this report, the experience in using a human suprapubic urinary bladder catheter (Cystofix®, by B. Braun) in a goat was shared. The catheter use was easy and did not require general anaesthesia or an abdominal incision compared to the bladder tube cystotomy technique. The catheter design within the cannula facilitates and shortens the preparatory procedure, hence reducing the risk of sharp injury (B. Braun Group, 2020).

The Cystofix® system's percutaneous placement, under ultrasonographic guidance, allows an immediate relief of the distended bladder so the urethra can heal as the urine outflow is diverted through the catheter. The second Cystofix® (adult size) placed in the goat was occluded by small stones, which were dislodged within the lumen of the tube as the lumen was larger than the neonatal system. Therefore, using a neonatal Cystofix® system for percutaneous bladder catheter in goats with the blocked urethra is suggested.

Fortier *et al.* (2004) suggested that the use of Stamey percutaneous urinary bladder catheter in goat resulted in the displacement of the catheter from the urinary bladder. However, this was not seen in our technique. The Cystofix® system was secured inside the urinary bladder for many days, but it was displaced because the goat managed to remove the catheter. The Cystofix® system was reliable and allowed more time to reverse the goat's systemic imbalances before performing cystotomy to remove urinary bladder stones.

The urolith gathered from the goat was diagnosed to be of magnesium calcium phosphate apatite form. Many factors influence calculus formation along the urinary tract of goats, including the genotype, mineral content of the diet, mucoprotein matrix, urinary volume, and urinary pH (Hay, 1990). The most likely predisposing factors are the feeding materials/grains high in phosphorus and magnesium, low grass, and calcium diet. Naturally, in response to a rise in high dietary phosphorus intake, the phosphorus will be excreted in the ruminant saliva, re-swallowed, and either reabsorbed or lost in the faeces. However, low dietary roughages would result in less chewing, which leads to less phosphorus are excreted via the saliva.

The solution would be to remove the phosphorus via the kidney and excrete it in the urine. With high phosphorus and magnesium feed materials and low roughage for the goats, this will cause the phosphorus and magnesium to consolidate. The apatite form of uroliths tends to develop at a urine pH of 6.5-7.5 (Jones *et al.*, 2012), which contributes to the formation of consolidated calculus apatite.

The contrast study performed here showed that the obstructive urolith had dislodged at the level of the urethra at the diverticulum and was obstructing the urethra. There was urethral stricture at the level of sigmoid flexure and stenosis of the urethra at the pelvic inlet; thus, urethral patency could not be restored. In the face of urethral blockage at the level of the pelvic urethra, a perineal urethrostomy procedure was no longer an option. A bladder marsupialisation would bypass the urethra (Fortier *et al.*, 2004) with a risk of cystitis and the abdominal wall's urine scalding. The owner was made aware of these complications.

The use of fluoroquinolone drug on the goat is justifiable since the goat is a pet for the owner, and the chronicity of the urinary tract infection further supports this drug's use. However, in the UK, guidelines have been developed to help the veterinarian be responsible for using antibiotics in farm animals and the effect of antibiotic resistance and why it is vital to human and animal health. These guidelines are published by the Responsible Use of Medicines in Agriculture (RUMA) Alliance, covering the topics of responsible use of antibiotics in veterinary practice on farm animals, cattle, sheep, pig, poultry, and fish productions, dry cow management, and avoiding antibiotic milk residue. These guidelines are downloadable from the RUMA official website. The British Equine Veterinary Association also developed a guideline known as Protect Me to help and educate equine veterinarians to limit further spread of antibiotic resistance in equine patients.

In summary, this case's outcome supports the percutaneous cystotomy technique using a human suprapubic bladder catheter as a rapid method to relieve the distended urinary bladder in a goat. The novelty of this case highlighted the use of human suprapubic bladder catheter (paediatric and adult size catheters) in the management of obstructive urolithiasis in an intact male goat. Based on this case study, it is recommended to use a paediatric size suprapubic bladder catheter to rapidly resolve progressive bladder distension in goats.

### Acknowledgements

The authors would like to acknowledge the help of Dr. Syed Hasanul-Hadi bin Syed Mohsin, from the Faculty of Medicine and Health Sciences, Universiti Putra Malaysia for the adult size human suprapubic bladder catheter system, and Dr. Ganesh Vythilingam from Pusat Perubatan Universiti Malaya for the neonatal size human suprapubic bladder catheter system. Further acknowledgment also goes to the Radiology Unit staff, Mr. Mior and Mr. Farid, for their excellent assistance during the cysto-urography. Huge gratitude also goes to the staff of the Department of Medicine and Surgery of Farm and Exotic Animals,

Faculty of Veterinary Medicine, Universiti Putra Malaysia, as well as veterinary students involved in this case. Special thanks to Prof. James L. Carmalt for his kind opinion on this case report.

### References

- B. Braun Group. 2020 . Cystofix® the new reference in suprapubic catheterization [Online]. Available: <https://www.bbraun.com.my/content/dam/catalog/bbraun/bbraunProductCatalog/S/AEM2015/en-my/b/cystofix-brochure>.
- Corder, C.J. and LaGrange, C.A. 2020. Suprapubic bladder catheterization. In: StatPearls [Online]. Treasure Island (FL): StatPearls Publishing. Available: <https://www.ncbi.nlm.nih.gov/books/NBK482179>.
- Ewoldt, J.M., Jones, M.L. and Miesner, M.D. 2008. Surgery of obstructive urolithiasis in ruminants. *Veterinary Clinics of North America: Food Animal Practice*. 24:455-465.
- Fortier, L.A., Gregg, A.J., Erb, H.N., et al. 2004. Caprine obstructive urolithiasis: requirement for 2nd surgical intervention and mortality after percutaneous tube cystostomy, surgical tube cystostomy, or urinary bladder marsupialization. *Veterinary Surgery*. 33:661-667.
- Goyal, N.K., Goel, A. and Sankhwar S.N. 2012. Safe percutaneous suprapubic catheterisation. *Annals of Royal College Surgeons of England*. 94:597-600.
- Haven, M.L., Bowman, K.F., Engelbert, T.A., Blikslager, A. T. 1993. Surgical management of urolithiasis in small ruminants. *The Cornell Veterinary*. 83:47-55.
- Hay, L. 1990. Prevention and treatment of urolithiasis in sheep. *In Practice*. 12:87-91.
- Jones, M., Miesner, M.D., Baird, A.N., et al. 2012. Diseases of the urinary system. In: *Sheep and Goat Medicine* (D. G. Pugh and A. N. Baird eds). 2nd ed. Saunders. Missouri, USA. 325-342.
- Khairuddin, N.H., Mansor R., Radzi R., et al. 2016. Management of lower urinary tract obstructive disease using bladder tube cystotomy in a Saanen buck. *Pertanika Journal of Tropical Agricultural Sciences*. 39:1127-136.
- Rakestraw, P., Fubini, S.L., Gilbert, R. et al. 1995. Tube cystotomy for treatment of obstructive urolithiasis in small ruminants. *Veterinary Surgery*. 24:498-505.
- Tan, Y.K., Khairuddin, N.H., Hiew, M.W.H. et al. 2017. Urinary bladder rupture secondary to obstructive urolithiasis in a Jamnapari goat. *Jurnal Veterinar Malaysia*. 29:20-24.
- Van Metre, D.C. and Fubini, S.L. 2006. Ovine and caprine urolithiasis: another piece of the puzzle. *Veterinary Surgery*. 35:413-416.
- Videla, R. and Vam Amstel, S. 2016. Urolithiasis. *Veterinary Clinics of North America: Food Animal Practice*. 32:687-700.