

Therapeutic effect of *Tarantula cubensis* extract on indomethacin induced gastric ulcers in rats

Mustafa Makav^{1*} Volkan GELEN¹ Semin GEDİKLİ² Gözde ATILA USLU¹

Hamit USLU³ Hüseyin Avni EROĞLU⁴

Abstract

Non-steroid anti-inflammatory drugs (NSAIDs) have widely been used in patients but side-effects associated with NSAID are also common. *Tarantula cubensis* extract (TCE) is an antiphlogistic, demarcative, homeopathic and necrotizing drug with wound healing effects in farm animals. However, the therapeutic effects of TCE on gastric ulcers has not been investigated. The aim of this study was to investigate the gastroprotective effects of TCE against indomethacin-induced gastric injury in rats.

A total of 28 female, Wistar albino rats were divided into four groups: (i) the control group, (ii) the indomethacin (Indo) group, (iii) the TCE + Indo group, and (iv) the ranitidine + Indo group. We measured total antioxidant capacity, total oxidant capacity and oxidative stress index in the blood serum. We also measured tumor necrosis factor- α (TNF- α), interleukin-1 β (IL-1 β), IL-6, IL-8, and cyclooxygenase-2 (COX-2) activity level in the stomach tissue of rats. Finally, histopathology of the tissue of all groups was assessed. Immunostaining of 8-hydroxydeoxyguanosine (8-OHdG) and nuclear factor kappa B (NF-kB) was performed in the gastric tissue of all animals studied.

Application of the TCE significantly decreased IL-1 β and IL-6 levels were markedly lower than ranitidine. Thus, notable Indo-induced alterations in cytokines (IL-1 β , IL-6) in rat gastric tissue were alleviated by TCE. Moreover, the gastric mucosal tissues of the TCE treated group exhibited a regular and uninterrupted mucosal layer and epithelial layer. Immunohistochemical results revealed that Indo increased 8-OHdG and NF-kB expression when compared to the control groups and treatment by TCE decreased the expression. The results obtained showed that the group receiving TCE exhibited lower gastric erosion and better efficiency than with ranitidine.

These results have demonstrated that TCE provides a therapeutic effect in Indo-induced gastric ulcers in rats.

Keywords: indomethacin-induced gastric ulcer, NF-kB, 8-OHdG, Rat, *Tarantula Cubensis* extract

¹Kafkas University, Faculty of Veterinary Medicine, Department of Physiology, Kars Turkey

²Atatürk University, Faculty of Veterinary Medicine, Department of Histology-Embryology, Erzurum Turkey

³Kafkas University, Atatürk Health Vocational School, Department of Health Care Services, Kars Turkey

⁴Çanakkale Onsekiz Mart University, Faculty of Medicine, Department of Physiology, Çanakkale, Turkey

*Correspondence: mustafamakav@gmail.com (M. Makav)

Received April 20, 2020.

Accepted September 21, 2020.

Introduction

Non-steroid anti-inflammatory drugs (NSAIDs) have been widely used in the management of pain and inflammation (Pal et al., 2010). Accordingly, complications associated with NSAIDs are also common. The most common side-effects are gastrointestinal complications such as mucosal erosion, mucosal haemorrhagia and ulceration due to impaired perfusion and apoptosis (Wallace, 2000; Lanas et al., 2005; Musumba et al., 2009; Pal et al., 2010; Bindu et al., 2013). NSAIDs cause this adverse-effect by inhibiting prostaglandin production as a result of the inhibition of cyclooxygenase (COX) enzymes, and increased production of reactive oxygen species (ROS) (Pal et al., 2010). Indomethacin (Indo), an NSAID, plays a role in gastric mucosal damage by activating ROS (Chatterjee et al., 2007). Oxidative stress initiated by Indo results in the impairment of mitochondria functions and it thus causes production of pro-inflammatory cytokines (Pal et al., 2010; Bindu et al., 2013). Previous studies have proved that inflammatory processes take part in gastric mucosal damage associated with the use of Indo (Musumba et al., 2009; Uc et al., 2012). Many drugs exhibiting anti-oxidant, anti-inflammatory and anti-apoptotic effects have been used to alleviate Indo associated gastric mucosal injury (Emin and Volkan, 2019; Uslu and Uslu, 2019).

The anti-inflammatory, antiphlogistic, demarcative, homeopathic and necrotizing actions of *Tarantula cubensis* extract (TCE) have been previously reported. (Stampa, 1986; Gültiken and Vural, 2007). However, the therapeutic effects of TCE on the gastric ulcer has not been investigated.

The aim of the present study was to investigate the gastroprotective effects of TCE against Indo-induced gastric injury in rats.

Materials and Methods

Animals: A total of 28 female, Wistar albino rats, weighing 180–190g, were obtained from the Experimental Animal Laboratory of Kafkas University. The animals were randomly assigned to four groups of seven animals each and all the rats were maintained under standard conditions till the study started. Animal experiments were performed in accordance with the national Animal Experiments Ethical Guidelines.

The study was initiated following approval from the Kafkas University Ethics Committee for Animal Experiments (KAÜ-HADYK 2019-054).

Experimental design: The experiment consisted of four groups: (i) the control group, (ii) the Indo group, (iii) the TCE + Indo group, and (iv) the ranitidine + Indo group. Saline was orally provided to the control group for 7 days during the experiment. A single dose of Indo (100 mg/kg body weight) (Emin and Volkan, 2019) was administered by oral gavage on the 8th day to all animals in the Indo group after a daily dose of saline for a week. A single dose of Indo (100 mg/kg body weight) was administered by oral gavage on the 8th day to all animals in the TCE + Indo group after 7 days in addition to a single dose 0.3mg/kg (Ghasemi-Dizgah et al., 2017) of TCE. Finally, a single dose of Indo (100

mg/kg body weight) was similarly administered to all the animals in the ranitidine + Indo group on the 8th day after a 5mg/kg (Emin and Volkan, 2019) daily dose of ranitidine for seven days. Anesthetic (Ketamine hydrochloride: 75mg/kg and xylazine: 15 mg/kg im) was applied to all the animals and they were subsequently sacrificed by cervical dislocation 6 h after the Indo administration (Dengiz et al., 2007). The blood and tissue samples (stomach) were obtained from all animals. The stomachs were detached, opened and washed with serum physiological solution (0.9% NaCl).

Biochemical Parameters from Blood and Tissue: We measured total antioxidant capacity (TAC) and total oxidant capacity (TOC) of all the animals in the study from the blood serum using commercially available kits (Rel Assay Diagnostics kit, Mega Tip, Gaziantep, Turkey) based on the method reported by Erel (Erel, 2004, 2005).

We subsequently calculated the oxidative stress index (OSI) using the ratio of TOC/TAC.

The tissue specimens were used to determine the tissue protein levels of tumor necrosis factor- α (TNF- α), interleukin-1 β (IL-1 β), IL-6, IL-8, and COX-2. The TNF- α , IL-1 β , IL-6 and IL-8 concentrations were assessed by ELISA kit (Immunotech, Hamburg, Germany) using a sandwich type assay along with the procedures suggested by the manufacturer and according to an earlier report (Ranganathan et al., 2006). We also measured COX-2 inhibitory assay using the COX Inhibitor Screening Assay Kit (Cayman Chemicals, Ann Arbor, MI) described previously (Shukla et al., 2008).

Histopathological Examination: For histopathological analyses, the stomach tissues were fixed in 10% formalin. After 72 h of fixing, the tissue samples were dehydrated, cleared and embedded in paraffin. Paraffin blocks were cut at 5 μ m thickness using a Leica RM2125RT microtome (Leica Microsystems, Wetzlar, Germany) and stained by Mallory's triple stain modified with Crossman for assessment of architectural damage and inflammatory process. The stained specimens were examined under a light microscope (Nikon eclipse i50, Tokyo, Japan) and photo images were taken for histopathological evaluation.

Immunohistochemical examination: From the tissues embedded in paraffin blocks, cross-sections were put on to adhesive-containing slides. The sections were passed through gradients of xylol and alcohol, and deparaffinization and dehydration were performed. The tissues were washed with phosphate-buffered saline (PBS), kept for 10 mins. in the 3% H₂O₂ solution. To prevent the antigens in the tissues from being masked, the samples were microwave-treated for 2x5 mins. with an antigen retrieval solution. After this process, primary antibodies 8-hydroxylo-2'-deoxyguanosine (8-OHdG) (catalog no. sc66036, dilution 1/300; Santa Cruz, USA) and nuclear factor kappa B (NF- κ B) (catalog no. sc8414, dilution 1/300; Santa Cruz, USA) were added. Afterwards, 3-3'Diaminobensidine was used as chromogen. The sections that were counterstained by hematoxylin were

observed under a light microscope. The pathologists counted the number of positive cells in each high-power field and calculated the average number of positive cells to reflect the intensity of positive expression. The sections were evaluated as none (-), mild (+), moderate (++), and severe (+++) according to their immunity positivity (Geyikoglu et al., 2019; Temel et al., 2020).

Statistical Analyses: Analysis of variance (ANOVA) was conducted for all the biochemical parameters to test if there was a difference among the four groups. The mean separation among groups was performed utilizing Tukey's test. An experiment-wise p-value of ≤ 0.05 was deemed to be statistically significant throughout the study. All the analyses were conducted using GraphPad 8.1 (San Diego, CA, USA).

Results

Gastroprotective effect of TCE on Indo induced gastric damage: We compared the TOC, TAC and OSI levels of the four groups to deduce the therapeutic effect of TCE on the Indo-induced ulcers. Results revealed that the overall model was not significant for TAC (Figure 1A), TOC (Figure 1B) and OSI (Figure 1C) values ($p > 0.05$).

We also compared the levels of pro-inflammatory cytokines IL-1 β , IL-6, and IL-8 and TNF- α among groups. The results revealed that the IL-1 β levels differed significantly among groups ($p < 0.05$). The IL-1 β level of Indo group was significantly higher than the Control group and the TCE + Indo group ($p < 0.05$, Figure 1D).

When IL-6 was considered, the overall model was significant ($p < 0.05$) implying a notable difference among groups. The IL-6 levels of the Indo group were markedly higher than those of the Control group and the TCE + Indo group ($p < 0.05$, Figure 1E).

The IL-8 levels also differed significantly among groups ($p < 0.05$). The IL-8 level of the Indo group, the TCE + Indo and the Ranitidine + Indo group were markedly higher than the control group ($p < 0.05$, Figure 1F).

The ANOVA for TNF- α indicated a significant difference among groups ($p < 0.05$). The TNF- α level of the Indo group was significantly higher than the TCE + Indo and the control group ($p < 0.05$, Figure 1G).

We finally evaluated COX-2 inhibition level and observed that the overall model was significant ($p < 0.05$). COX-2 values of control animals were significantly different from those of the Indo, ranitidine + Indo and TCE + Indo groups ($p < 0.05$).

Histopathological findings: The photomicrographs of stomachs for each group are demonstrated in Figure 2A-D, providing a better comparison of the gastric lesion and subsequent healing. When the stomach sections were examined, it was observed that the gastric sections of the control group had a normal histological structure (Figure 2A). Indo intake stimulated serious and widespread macroscopic gastric mucosal damage, characterized by injury in the epithelial layer of the mucosa. Common mononuclear inflammatory cells were observed in the lamina propria and submucosa in the Indo group. Also,

widespread necrosis with loss of surface epithelium and submucosal edema were seen in the Indo group (Figure 2B). The disruption in the gastric mucosa was partially restored after using TCE + Indo but mononuclear cell infiltration was still observed in the mucosal layer (Figure 2C). However, the gastric mucosal tissues of the ranitidine group (Figure 2D) indicated closer to normal and uninterrupted mucosal layers and the formation of an epithelial layer. The results obtained showed that the group receiving TCE exhibited lower gastric erosion and better efficiency than ranitidine + Indo groups (Figure 2C, D).

Immunohistochemical findings: The representative images of 8-OHdG and NF- κ B immunoreactivity are depicted in Figure 3. Immunohistochemistry revealed that 8-OHdG and NF- κ B immunoreactive products presenting as brown-reddish fine granules, located in the nucleus. The oxidative DNA damage markers (8-OHdG and NF κ B) expressions were significantly increased in the Indo group compared to the control group. Also, immunopositivities of 8-OHdG and NF- κ B were notably decreased in the TCE + Indo and ranitidine + Indo groups compared with the Indo group. Moreover, immunopositivities of 8-OHdG and NF- κ B in the Ranitidine + Indo group was lower than TCE + Indo group (Figure 3). The positive cell intensity of 8-OHdG and NF- κ B in the groups is shown in Table 1.

Discussion

The damage in gastric tissues can be expressed in the form of a gastric ulcer and poses a risk around the globe (Bauer and Meyer, 2011). Indo, an NSAID drug triggers ROS production. The ulceration and healing processes stimulate various processes in the body including the production of ROS (Heibashy et al., 2014). In the present study, we induced gastric ulcers in rats using Indo and tested the therapeutic potential of TCE in comparison to ranitidine. The first parameter set tested in our study was blood serum TAC, TOC levels and calculated OSI. While no difference among groups was observed in TAC and OSI, TOC varied significantly among groups, indicating an elevated oxidant level in the Indo induced groups. Both serum TAC and TOC levels were found to differ in the gastric ulcer group and treated groups in a previous study testing various herbs (Heibashy et al., 2014). We found that the mean TAC value was higher in the control group with no significant difference. The reason that we could not detect a significant difference might be the relatively small sample size. In the current study we used 7 animals in each group but a higher number of experimental units might have had a better resolution among groups.

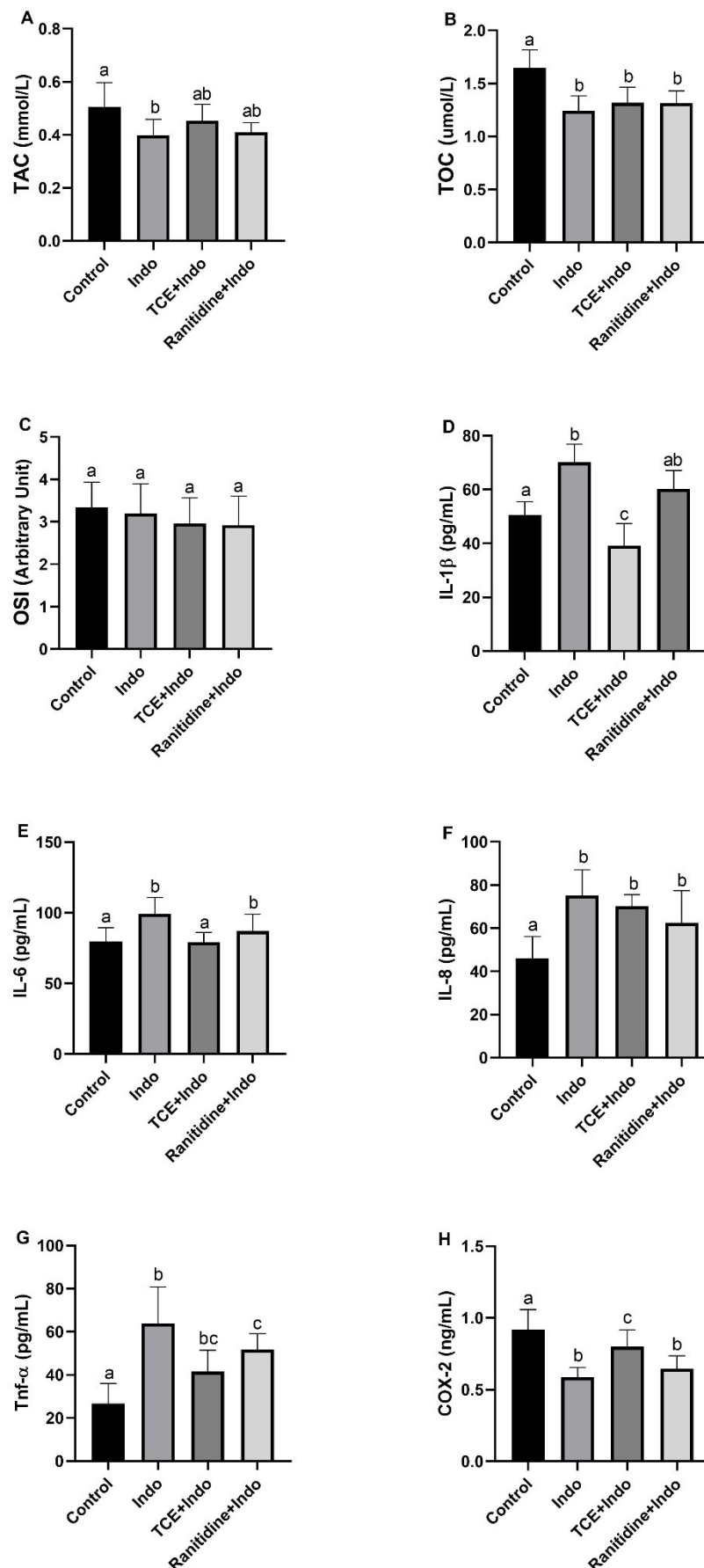


Figure 1 Estimating the effects of TCE on the Indo induced gastric ulcer in rats while comparing its effect to control, Indo and Ranitidine + Indo on changes in (A) Total Antioxidant Capacity (TAC), (B) Total Oxidant Capacity (TOC), (C) Oxidative Stress Index (OSI), (D) Interleukin-1 β (IL-1 β), (E) Interleukin-6 (IL-6), (F) Interleukin-8 (IL-8), (G) Tumor necrosis factor- α (TNF- α), and (H) cyclooxygenase-2 (COX-2).

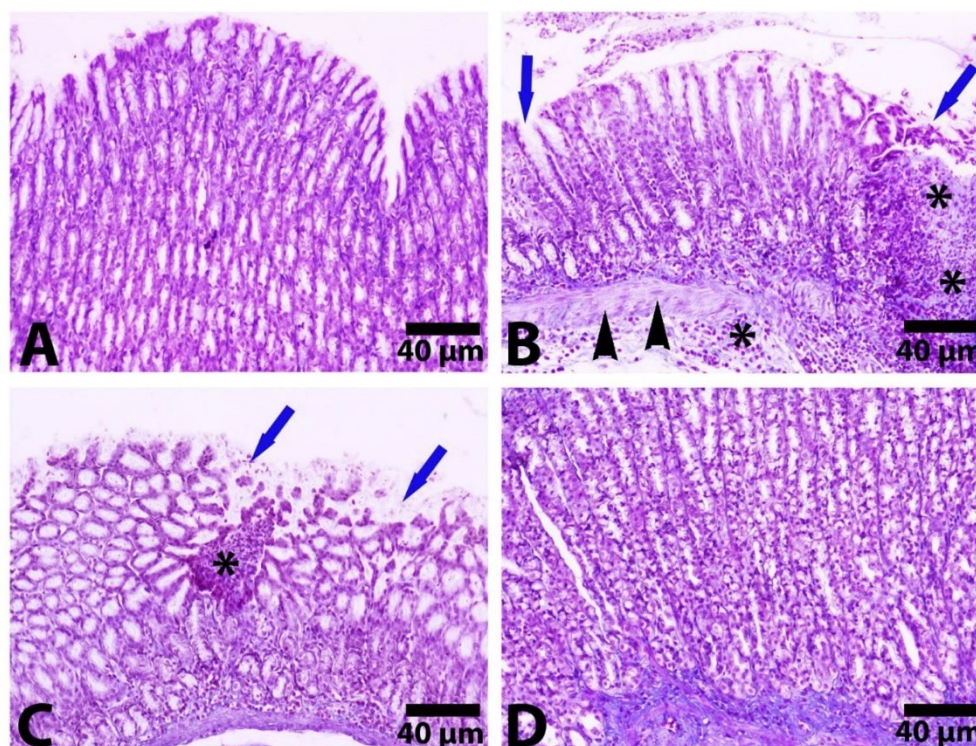


Figure 2 Photomicrograph of stomach section of the Control (A), Indo (B), TCE + Indo (C), and Ranitidine + Indo (D) groups. asterisks: Mononuclear inflammatory cells; blue arrows: Widespread necrosis with loss of surface epithelium; arrowheads: Mucosal and submucosal edema. Stain: Crossman's modified Mallory triple staining.

Table 1 Immunohistochemical findings and their scores in stomach tissue

Groups	8-OHdG	NF-kB
Control Group	-	-
Indo Group	+++	+++
TCE + Indo Group	++	++
Ranitidine + Indo Group	+	+

According to immunohistochemical findings: none (-), mild (+), moderate (++) and severe (+++)

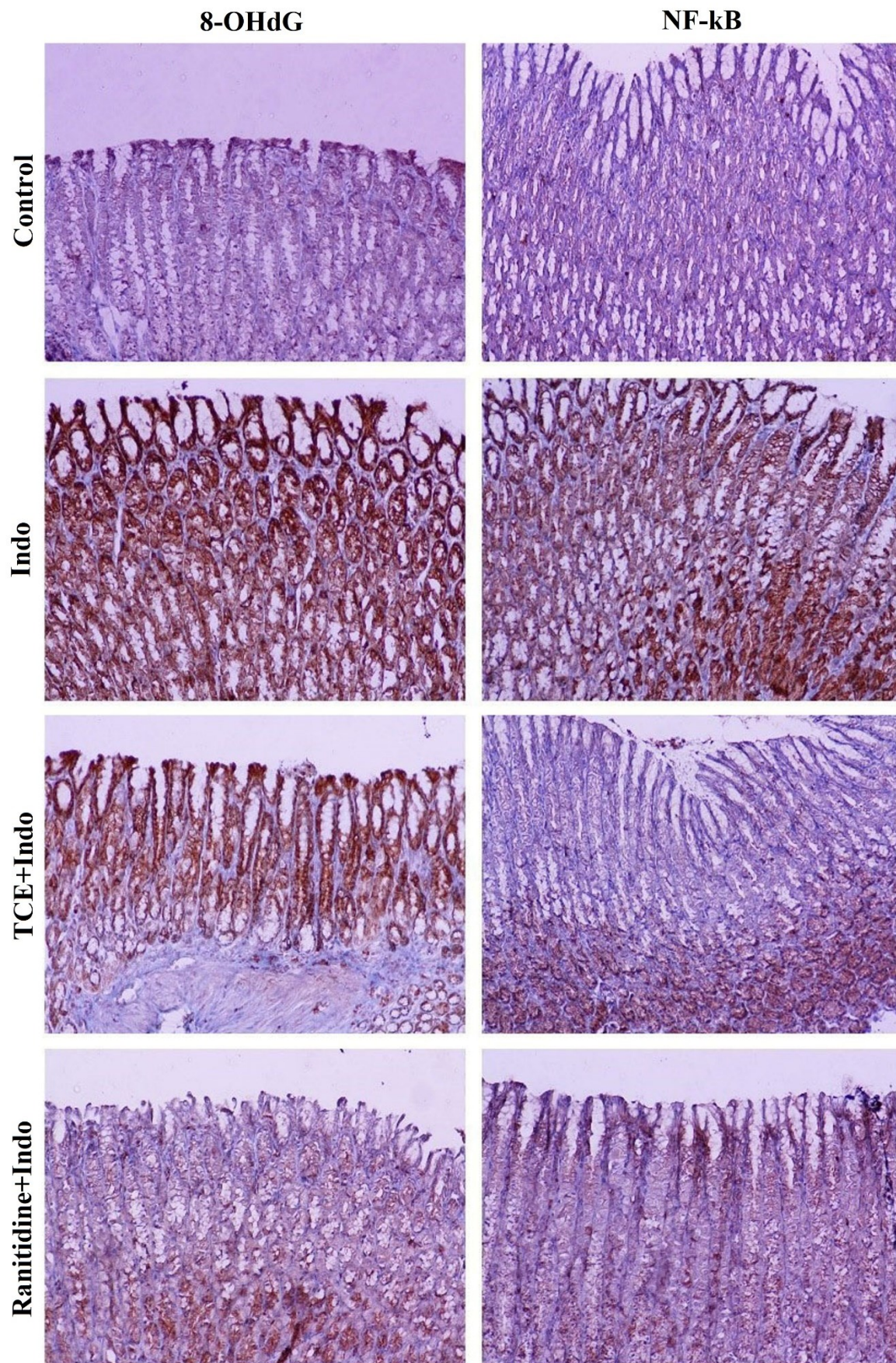


Figure 3 Immunohistochemical staining for the 8-OHdG and NF-kB for the Control, Indo, TCE + Indo and Ranitidine + Indo groups. Streptavidin-biotin peroxidase staining.

It has been observed that wound healing demonstrates a common pattern of coagulation, inflammation, epithelialization, formation of granulation tissue and matrix and tissue remodeling. Cytokines are a group of polypeptides or glycoproteins that mediate and regulate immunity, inflammation and hematopoiesis (Al-Waili and Butler, 2006). The role of cytokines such as IL-1, IL-6, IL-8 and TNF- α as well as the COX-2 in healing the gastric tissue in ulcer cases has been indicated before (Dengiz et al., 2007). COX-2 is an enzyme involved in the biological process of cutaneous inflammation, cell proliferation and skin tumor promotion (Prescott and Fitzpatrick, 2000). Here, we used these tissue proteins to test the protective effect of TCE against the Indo induced gastric ulcer. We found that the control group had lower activity levels and the Indo group always had the highest activity level implying wounds in the rat stomach. The common therapeutic drug ranitidine decreased the cytokine levels but the difference in all four was not significant. Application of the TCE significantly decreased TNF- α , IL-1 β , IL-6 levels in all four cases and the mean value was significantly lower than ranitidine. Thus, significant Indo-induced alterations in cytokines in rat gastric tissue were alleviated by TCE. Harsch et al., (2003) and Mehmet et al., (2004) reported a marked increase in TNF- α , and IL-1 β in rats with gastric ulcers as was the case in our study. TCE was of help in alleviating the side effects of Indo as TNF- α and IL-1 β levels were lower in the TCE + Indo group when compared to the Indo group. The extract of *Cissus quadrangularis* was shown to possess a gastroprotective effect by Jainu and Devi, (2006) where animals receiving the extract had lower levels of TNF- α and IL-1 β than the gastric ulcer group, as in our study.

Immunohistochemical and histopathological evaluations were also performed in all four groups and similar results were observed. The oxidative DNA damage marker expressions were elevated significantly in the Indo group compared to the control group and decreased compared to the TCE + Indo and the ranitidine + Indo. However, in the ranitidine + Indo groups the decrease was more dramatic compared to the TCE + Indo. Similarly, severe and extensive macroscopic gastric mucosal damage, manifested by damage in the epithelial layer of the mucosa due to Indo intake was partially restored in the TCE + Indo groups and almost completely healed in the ranitidine + Indo. Both immunohistochemical and histopathological findings also confirm that TCE is an effective drug for recuperation from gastritis.

TCE has antiphlogistic, demarcation, homeopathic and necrotizing actions against various injuries (Stampa, 1986). Indo reduced the mucosal prostaglandin E2 content and stimulated serious and widespread macroscopic gastric mucosal damage. On the other hand, the normal and uninterrupted mucosal layer and formation of the epithelial layer after the co-administration of TCE also revealed that the restoration of the gastric mucosa was achieved with the Indo induced ulcer model.

In conclusion, these results demonstrate that TCE provides a therapeutic effect in Indo-induced gastric ulcers in rats. This further suggests that the use of TCE

as a therapeutic agent in ulcer cases should be considered and, specifically, tests might be performed in humans.

Abbreviations: TNF- α : Tumor necrosis factor- α ; IL-1 β : interleukin-1 β ; IL-6: interleukin-6; IL-8: interleukin-8; COX-2: Cyclooxygenase-2; TAC: Total antioxidant capacity; TOC: Total oxidant capacity; OSI: Oxidative stress index; 8-OHdG: 8-hydroxydeoxyguanosine; NF- κ B: nuclear factor kappa B; ROS: Reactive oxygen species; TCE: *Tarantula cubensis* extract; NSAIDs: Non-steroidal anti-inflammatory drugs.

References

- Al-Waili NS, Butler GJ (2006) Effects of hyperbaric oxygen on inflammatory response to wound and trauma: possible mechanism of action. *Sci World J* 6: 425-441.
- Bauer B, Meyer TF (2011) The human gastric pathogen *Helicobacter pylori* and its association with gastric cancer and ulcer disease. *Ulcers* 2011.
- Bindu S, Mazumder S, Dey S, Pal C, Goyal M, Alam A, Iqbal MS, Sarkar S, Siddiqui AA, Banerjee C (2013) Nonsteroidal anti-inflammatory drug induces proinflammatory damage in gastric mucosa through NF- κ B activation and neutrophil infiltration: Anti-inflammatory role of heme oxygenase-1 against nonsteroidal anti-inflammatory drug. *Free Radic Biol Med* 65: 456-467.
- Chatterjee M, Saluja R, Kanneganti S, Chinta S, Dikshit M (2007) Biochemical and molecular evaluation of neutrophil NOS in spontaneously hypertensive rats. *Cell Mol Biol Noisy--Gd Fr* 53(1): 84-93.
- Dengiz GO, Odabasoglu F, Halici Z, Cadirci E, Suleyman H (2007) Gastroprotective and antioxidant effects of montelukast on indomethacin-induced gastric ulcer in rats. *J Pharmacol Sci* 105(1): 94-102.
- Emin S, Volkan G (2019) Protective effects of naringin in indomethacin-induced gastric ulcer in rats. *GSC Biol Pharm Sci* 8(2): 006-014.
- Erel O (2004) A novel automated direct measurement method for total antioxidant capacity using a new generation, more stable ABTS radical cation. *Clin Biochem* 37(4): 277-285.
- Erel O (2005) A new automated colorimetric method for measuring total oxidant status. *Clin Biochem* 38(12): 1103-1111.
- Geyikoglu F, Koc K, Colak S, Erol HS, Cerig S, Yardimci BK, Cakmak O, Dortbudak MB, Eser G, Aysin F (2019) Propolis and its combination with boric acid protect against ischemia/reperfusion-induced acute kidney injury by inhibiting oxidative stress, inflammation, DNA damage, and apoptosis in rats. *Biol Trace Elem Res* 192(2): 214-221.
- Ghasemi-Dizgah A, Nami B, Amirmozafari N (2017) *Tarantula cubensis* venom (theranekron®) selectively destroys human cancer cells via activating caspase-3-mediated apoptosis. *Acta Medica Int* 4(1): 74.
- Gültekin N, Vural MR (2007) The effect of *Tarantula cubensis* extract applied in pre and postoperative

- period of canine mammary tumours. *J Istanbul Vet Sci* (2): 13–23.
- Harsch IA, Brzozowski T, Bazela K, Konturek SJ, Kukharsky V, Pawlik T, Pawlowski E, Hahn EG, Konturek PC (2003) Impaired gastric ulcer healing in diabetic rats: role of heat shock protein, growth factors, prostaglandins and proinflammatory cytokines. *Eur J Pharmacol* 481(2): 249–260.
- Heibashy MIA, Mazen GMA, Ibrahim MA (2014) Efficacy and Safety of some Medical Herbs on Gastric Ulcer Induced by Aspirin in Rats.
- Jainu M, Devi CSS (2006) Gastroprotective action of *Cissus quadrangularis* extract against NSAID induced gastric ulcer: Role of proinflammatory cytokines and oxidative damage. *Chem Biol Interact* 161(3): 262–270.
- Lanas A, Perez-Aisa MA, Feu F, Ponce J, Saperas E, Santolaria S, Rodrigo L, Balanzo J, Bajador E, Almela P (2005) A nationwide study of mortality associated with hospital admission due to severe gastrointestinal events and those associated with nonsteroidal antiinflammatory drug use. *Am J Gastroenterol* 100(8): 1685–1693.
- Mehmet N, Refik M, Harputluoglu M, Ersoy Y, Aydin NE, Yildirim B (2004) Serum and gastric fluid levels of cytokines and nitrates in gastric diseases infected with *Helicobacter pylori*. *New Microbiol* 27(2): 139–148.
- Musumba C, Pritchard DM, Pirmohamed M (2009) cellular and molecular mechanisms of NSAID-induced peptic ulcers. *Aliment Pharmacol Ther* 30(6): 517–531.
- Pal C, Bindu S, Dey S, Alam A, Goyal M, Iqbal MS, Maity P, Adhikari SS, Bandyopadhyay U (2010) Gallic acid prevents nonsteroidal anti-inflammatory drug-induced gastropathy in rats by blocking oxidative stress and apoptosis. *Free Radic Biol Med* 49(2): 258–267.
- Prescott SM, Fitzpatrick FA (2000) Cyclooxygenase-2 and carcinogenesis. *Biochim Biophys Acta* 1470(2): M69–78.
- Ranganathan SS, Sathiadhas MG, Sumanasena S, Fernandopulle M, Lamabadusuriya SP, Fernandopulle BMR (2006) Fulminant hepatic failure and paracetamol overuse with therapeutic intent in febrile children. *Indian J Pediatr* 73(10): 871–875.
- Shukla M, Gupta K, Rasheed Z, Khan KA, Haqqi TM (2008) Bioavailable constituents/metabolites of pomegranate (*Punica granatum* L) preferentially inhibit COX2 activity ex vivo and IL-1 β -induced PGE 2 production in human chondrocytes in vitro. *J Inflamm* 5(1): 9.
- Stampa S (1986) A field trial comparing the efficacy of sulphamonomethoxine, penicillin, and tarantula poison in the treatment of pododermatitis circumspecta of cattle. *J S Afr Vet Assoc* 57(2): 91–93.
- Temel Y, Kucukler S, Yildirim S, Caglayan C, Kandemir FM (2020) Protective effect of chrysin on cyclophosphamide-induced hepatotoxicity and nephrotoxicity via the inhibition of oxidative stress, inflammation, and apoptosis. *Naunyn Schmiedeberg Arch Pharmacol* 393(3): 325–337.
- Uc A, Zhu X, Wagner BA, Buettner GR, Berg DJ (2012) Heme oxygenase-1 is protective against nonsteroidal anti-inflammatory drug-induced gastric ulcers. *J Pediatr Gastroenterol Nutr* 54(4): 471–476.
- Uslu GA, Uslu H (2019) Protective Effects of Chromium Picolinate on Indomethacin-Induced Stomach Ulcer in the Rat. *Gümüşhane University Journal of Health Sciences*. 8(3) : 237–244.
- Wallace JL (2000) How do NSAIDs cause ulcer disease? *Best Pract Res Clin Gastroenterol* 14(1): 147–159.