

## Rubber band syndrome in a dyspneic dog

Nithida Boonwittaya<sup>1\*</sup> Saroch Kaewmanee<sup>2</sup>

### *Abstract*

The rubber band syndrome has been reported in both human and animal patients but the number of cases shows it is an uncommon condition. Most cases live in communities where a rubber band is commonly used for a wide variety of purposes. Here we report a case of a dyspneic dog with a linear constricting scar and a discharging sinus on the ventral neck. The radiography showed constructive signs. Surgical exploration found a colored rubber band burrowing into the tracheal lumen. Following surgery, the dog recovered without any complications in the postoperative follow-up period. This case emphasized that rubber band syndrome in a dog can cause severe adverse effects; this was the first case of canine rubber band syndrome that penetrated the trachea and led to a life-threatening condition.

---

**Keywords:** dog, dyspnea, rubber band, trachea

<sup>1</sup>*Surgery Unit, Kasetsart University Veterinary Teaching Hospital, Faculty of Veterinary Medicine, Kasetsart University, Phahon Yothin Road, Chatuchak, Bangkok 10900, Thailand*

<sup>2</sup>*Department of Animal Science, Faculty of Agriculture, Kasetsart University, Phahon Yothin Road, Chatuchak, Bangkok 10900, Thailand*

\**Correspondence:* nithidaboonwittaya@gmail.com (N. Boonwittaya)

## Introduction

Rubber bands or elastic bands have been used for various purposes by humans, including in packaging for food production and daily consumed products, decorations, religious items, in therapeutic medicine for gastrointestinal disease, emergency hemostasis tourniquet, rehabilitation, orthodontic treatment, umbilical cord clamping and other innovative utilizations. Rubber band syndrome has been described in the human-related literature as a very rare condition with the forgotten rubber band placed circumferentially around various parts of the body over a long period (Meier *et al.*, 2019; Whitaker *et al.*, 2013). Under tension, the band can penetrate the skin gradually into the underlying soft tissue with causing exceptional pain. Due to the rapid growth of most cases in children, the band is invisible by the re-epithelialization of the chronic superficial wound and the draining sinus tract is presented on the lesion. The embedded band can damage structures leading to complications.

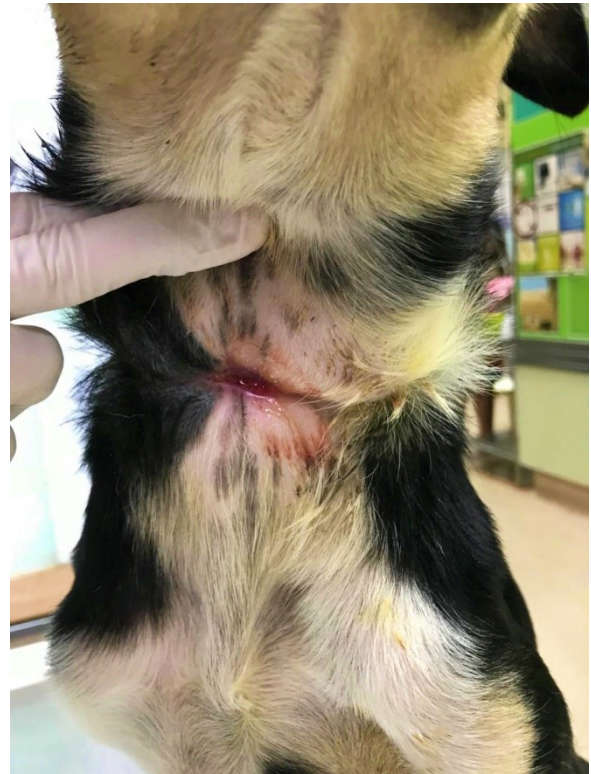There have been few reports describing rubber band syndrome in the veterinary literature, with all cases presented with a chronic discharging sinus or contracting wound. Most of them have no neuromuscular deficits or any severe complication. Surgical treatment involved the simple removal of the band without an aggressive approach into the deep essential structures (Brisson and Théoret, 2008; Hoffer and Estrin, 2006; Stelmach *et al.*, 2014). Two documents reported respiratory compromise due to external tracheal compression by the band and in one case included external esophageal compression (De Armond *et al.*, 2017; Sadler and Wisner, 2000). Tracheal resection and anastomosis were performed to reconstruct the tracheal constriction in one canine patient (De Armond *et al.*, 2017). In all previous reports, the band was found in the superficial soft tissue or extraluminal structures.

In contrast, the current report is the first of canine rubber band syndrome with fatal complications caused by the breached band into the cervical tracheal lumen. The excessive fibrous tissue caused by the second intention healing led to tracheal deformity and hid the foreign body as unknown etiology.

## Case Description

A 6-month-old intact female crossbred dog was presented at the emergency unit of the Kasetsart University Veterinary Teaching Hospital (KUVTH), Bangkaen campus, Bangkok, Thailand because of a 5-day history of respiratory distress and limited exercise tolerance. The owner reported neither history of external trauma nor previous abnormal signs. Physical examination revealed signs of upper airway obstruction with inspiratory dyspnea, stridor, open mouth breathing and slightly cyanotic mucous membranes. Initial stabilization was provided with oxygen-flow supplementation. The physical examination was continued when the dog was stable. A 7 cm linear constricting wound was found on the ventral neck with the draining sinus at the middle area (Fig. 1). The results of the remainder of the physical examination were unremarkable. Complete blood

count and biochemical profile values were within the normal limits.



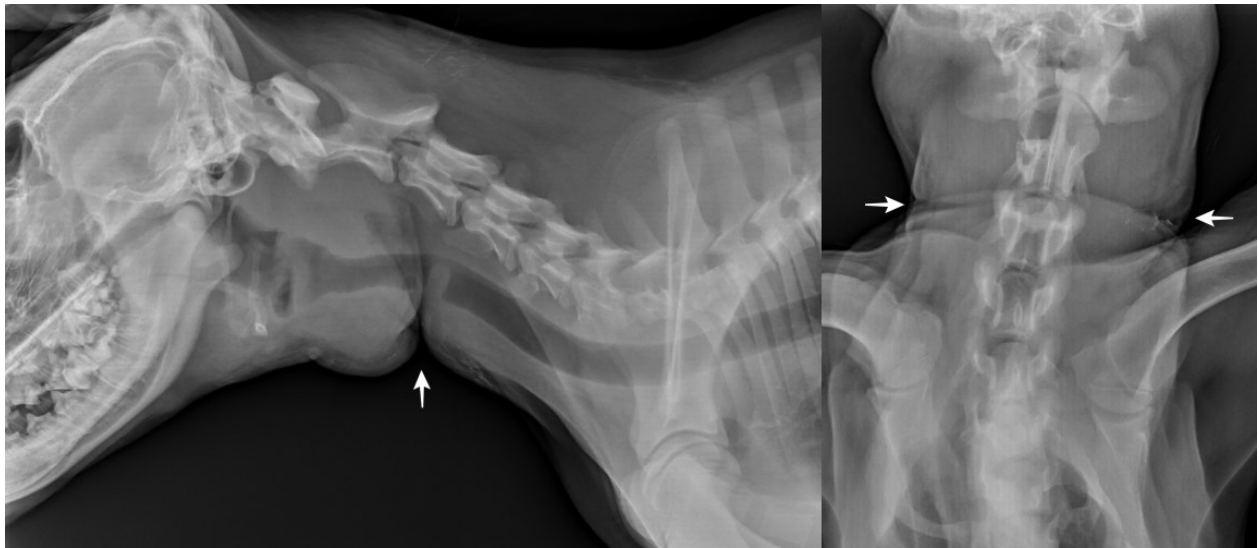
**Figure 1** Linear scar with discharging sinus at the ventral neck of a dyspneic dog.

The plain lateral radiographic views of the cervical area revealed a soft tissue compression from the superficial wound connecting to an increased soft tissue opacity invasive to the ventral of the tracheal lumen and almost reaching to the dorsal tracheal wall (Fig. 2). Tracheal luminal stenosis was suspected. The owner refused endoscopy and computed tomography to investigate the specific affected area, the underlying cause and the other organ involvement. To determine the etiology and reconstruct the narrowing area with the severity of urgent clinical signs, immediate exploratory surgery was chosen.

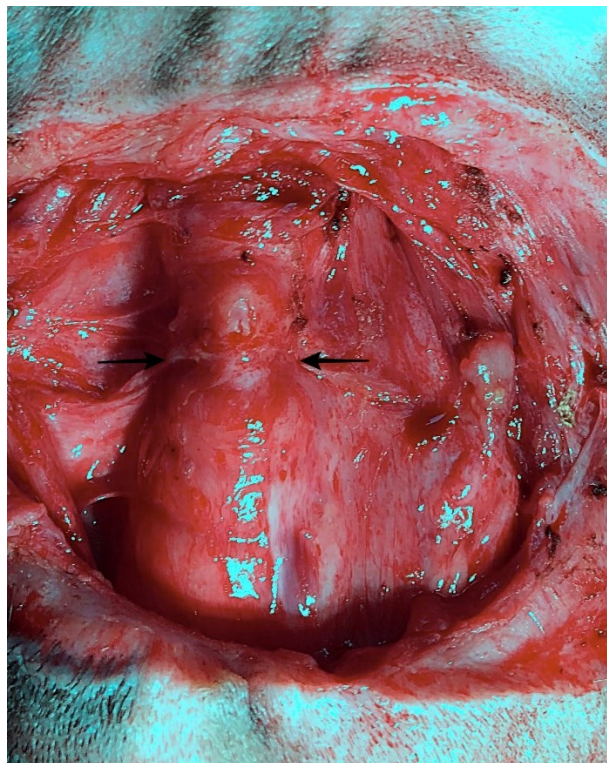
The dog was anesthetized and a small-diameter endotracheal tube was selected to intubate during the induction. The tube could not pass the affected area but was placed cranial to the obstruction. Surgical exploration of the wound and the cervical trachea was performed. An elliptical incision was made around the linear scar. The en bloc resection was continued and tracked down along the underlying fibrous tissue. On the affected trachea, firm fibrous tissue was found covering and compressing two cartilage rings and the middle annular ligament. With the 1.3 cm constricting part at the middle, the cervical trachea was divided into two segments (Fig. 3). Two stay sutures were placed around cartilages cranially and caudally to the narrowing area. The tracheotomy was performed at the constricting annular ligament. A colored rubber band (2 mm in width) was found in the tracheal lumen (Fig. 4A). Manual traction was initially attempted, but the other side of the band was struck protruding through the dorsal tracheal wall which was suspected hooking on vertebrae (Fig. 4B). The band was cut and removed

by pulling one side slowly to prevent tearing it off. The removed band was carefully examined to ensure its complete removal (Fig. 4C). The dorsal wall of the tracheal lumen was examined quickly and no abnormality was identified. The endotracheal tube was removed and replaced with a larger-size tube which matched to the dog's tracheal lumen. The tube was intubated from the mouth passing to the narrowing area into the distal segment. The cuff was inflated and positive pressure ventilation was provided. Before the tracheal resection was initiated, the endotracheal tube was withdrawn proximally to the resection site. The surrounding soft tissue was dissected, and the affected tracheal segment was freed circumferentially. The excision was started on the midpoint of normal

adjacent tracheal cartilages at each end of the constricting part as a split-cartilage technique. The trachea was resected at the fibrous affected part which was the constricting annular ligament, one cranial ring and one caudal ring. The tracheal anastomosis was performed using a 3-0 monofilament nonabsorbable suture in a simple interrupted pattern starting at the dorsal tracheal membrane. Then, the split cartilages were apposed by encircling with a simple interrupted suture pattern. The retention sutures were placed encircling the cartilage rings cranially and caudally to the rings adjacent to the anastomosis as a tension-relieving technique. The wound was thoroughly lavaged before closure.

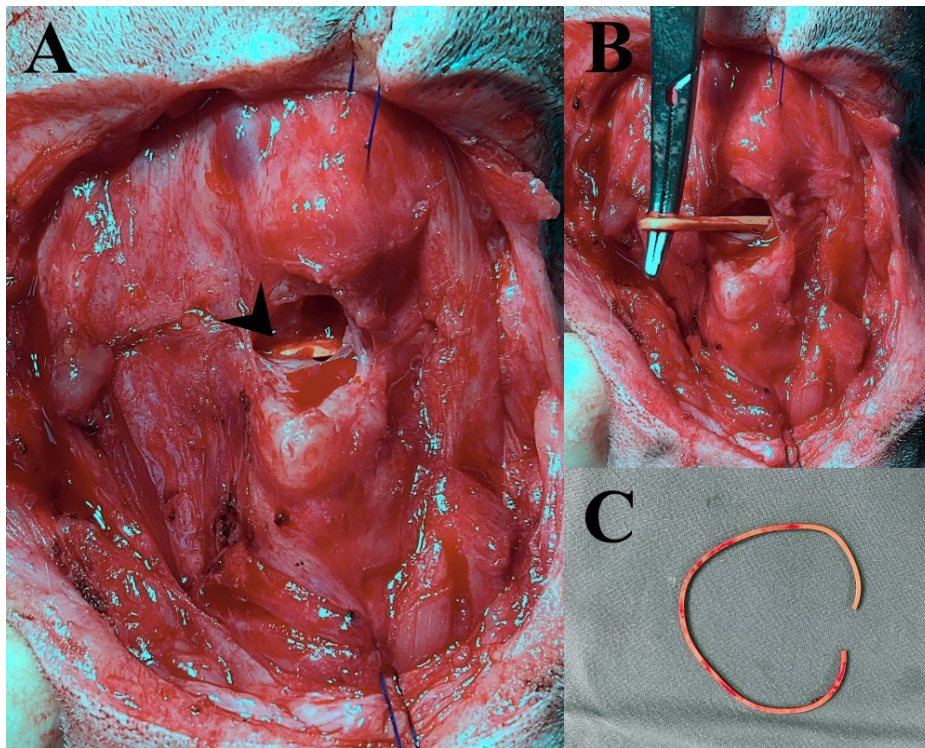


**Figure 2** Lateral and dorsoventral cervical radiographic views of a dyspneic dog, demonstrating 1.3 mm soft tissue opacity in the tracheal lumen with the constricting superficial tissue (white arrows) at the 3<sup>rd</sup> cervical vertebrae.



**Figure 3** Intraoperative view of cervical trachea. Compression area (black arrow) was found dividing the trachea into cranial and caudal segments.





**Figure 4** Intraoperative view of cervical trachea.  
 (A) Tracheotomy was performed and the rubber band (arrowhead) was found.  
 (B) Rubber band was attached through the dorsal tracheal wall and manual traction failed.  
 (C) Foreign body after removal.

The dog had an excellent recovery and was treated in the KUVTH Critical Care Unit over the next 72 hours. No postoperative complications were found, including wound dehiscence, wound infection, subcutaneous emphysema or respiratory distress. The owner was asked to enquire with other household members for any details to help avoid repetition of the injury. They recalled an incident when their child had put a rubber band around the dog's neck as a makeshift collar some 3 months earlier.

Follow-up information was obtained by telephone contact with the owner 3 months postoperatively and it was confirmed that the puppy was able to return to normal activity with no signs of respiratory obstruction. The last telephone contact with the owner was at 1.5 years after surgery and it was reported that the animal was breathing normally without any complications.

### Discussion

Forgotten circumferential application of a rubber band to any part of an animal's body is rare but can cause serious consequences. In the veterinary literature, previous reports described the edematous constriction of the left distal thoracic limb in a cat and of bilateral distal thoracic limbs in a dog. No neurologic complications were reported in both cases (Brisson and Théoret, 2008; Hoffer and Estrin, 2006). The other report documented a dog presenting only chronic discharging from a wound at the ventral cervical area without any complications (Stelmach *et al.*, 2014). Whereas, Sadler *et al.* (2000) and De Armond *et al.* (2017) reported on respiratory distress signs as a complication of cervical rubber band application in

young animals and one of them included regurgitation due to esophageal compression (De Armond *et al.*, 2017). In humans, the rubber band syndrome is similarly uncommon and has been reported occurring at the wrist, leg, neck, tongue, penis and fingers, mostly in the young-aged patients. An old person with less ability, a consciousness disorder or with people who misuse the band could also be patients with this syndrome. The common presenting symptoms are associated with distal soft tissue edema, a chronic constricting scar, loss of function of the affected area, and neurovascular compromise (Agarwal *et al.*, 2013; Aggarwal *et al.*, 2010; Al-hamzawi and Al-Khanfar, 2018; Glew, 1967; Maher *et al.*, 2011; Meier *et al.*, 2019; Whitaker *et al.*, 2013). The consequent complications depend upon the depth, location, position, and organ association.

Our case presented with the similar clinical finding of a chronic draining tract. The lesion was at the ventral neck, and there was shrinkage of the soft tissue around the wound. Moreover, respiratory distress can be markedly apparent with the other clinical symptoms of an upper respiratory obstruction as an urgent condition and should be included in the initial problem list. Unlike in the previous reported cases where the forgotten circumferential application of a rubber band occurred at the superficial soft tissue or caused external organ compression, in our current case the cervical rubber band embedded into the tracheal lumen and was invisible. Without surgical exploration, the underlying etiology would be unknown. Tracheal narrowing is a consequence of the traumatic tracheal open wound caused by the band penetration and the second intention healing effect without retrieving

previous treatment led to the deformity of the tracheal lumen.

Rubber bands are made from organic rubber or latex, which provides the good elasticity. The thermodynamics of a rubber band are interesting; stretching causes the rubber band to release heat but relaxing the stretch band causes its surroundings to be cooled (Brown, 1963). With thermal highly stretched energy, the band can penetrate the skin imperceptibly on a day-by-day basis. When the band is forgotten and left in place for a long period, especially in cases with a young patient with rapid healing ability, the band can be invisible after breaching into the deep tissue and re-epithelialization happens to heal the wound rapidly leading to the band becoming embedded. As a result, the clinical signs can be hidden for long period and not be apparent when adverse effects occur. Dyspnea signs in our case were not only caused by the rubber band lodged in the trachea, but also by the telescoping excessive healing of fibrous tissue into the tracheal lumen and the constricting effect leading to deformation of the tracheal ring, with the result of luminal narrowing.

An acute airway obstruction is an emergency situation, in which early intervention is necessary for the best outcomes. Although tracheal obstruction with foreign bodies and tracheal stenosis because of prior wounding in small animal patients are uncommon, if untreated, complete obstruction will lead to death rapidly while a partially obstructive trachea with a solid object can cause severe edema and pressure necrosis onto the local tissue. The acquired tracheal stenosis is usually secondary to the trauma such as the intubation, prior tracheal surgery and the external traumatic event. And evaluation commenced with obtaining the history and a clinical examination initially (Merck and Miller, 2013; Roach and Krahwinkel, 2009; Tivers and Moore, 2006; Smith *et al.*, 1990). Westermeyer *et al.* (2009) described a dyspneic case with a cervical circumferential scar, which diminished the blood flow and the function of the underlying soft tissue. The head was noted as having severe edema and the radiographic view revealed a similar problem. In our present case, although the history did not offer any specific clues, a linear scar with the constricting encircling soft tissue was found at the ventral mid-cervical area in our case, which was suspected to be related to the increased respiratory effort.

Radiography is a non-invasive technique for the initial diagnosis, providing the location, position, shape, and approximate size of the problem area. However, detecting the intraluminal foreign body by radiography depends on the opacity of the object (Roach and Krahwinkel, 2009), and one veterinary study reported that typical thoracic radiographic findings cannot exclude an airway foreign body (Tenwolde *et al.*, 2010). Computed tomography (CT) is effective modality for more accurate identification of the location, surrounding soft tissue and other adjacent organ abnormalities, especially in cases of an intrathoracic tracheal migrating foreign body (Schultz and Zwingerberger, 2008). Respiratory endoscopy is also a useful tool to obtain diagnostic information and the treatment for both of foreign body and obstruction

cases. The previous report of acquired tracheal stenosis in two dogs using tracheoscopy resulted in a diagnosis of tracheal intussusception by the intraluminal gross appearance (Kim *et al.*, 2012; Lebreton *et al.*, 2017). The success rate for the removal of a foreign body in the airway has been reported as 86% in dogs and 40% in cats using a bronchoscopy (Tenwolde 2010). Nonetheless, some characteristics of a foreign body in an airway make this approach difficult such as with a slippery round object (Somrup *et al.*, 2017). Instead, if such non-invasive procedures are or likely to be unsuccessful, surgical intervention is preferred (Goodnight *et al.*, 2010; Nutt *et al.*, 2014).

The diagnostic tools for human patients presenting with rubber band syndrome consist of radiography, ultrasonography, and magnetic resonance imaging (Agarwal *et al.*, 2013; Aggarwal *et al.*, 2013; Meier *et al.*, 2019). In the veterinary field, osteolysis at the distal forelimb and a radiopaque circumferential foreign body with tracheal compression were revealed by radiographic evidence which were determined as the cause of traumatic pressure by a band in two cats, respectively (Brisson and Théoret, 2008; Sadler and Wisner, 2000). Another case was diagnosed using CT which determined the circumferential rubber band and the fistula tract on the ventral neck to the scapular in a canine patient (Stelmach *et al.*, 2014). Moreover, in a recent reported case, radiography with endoscopy on a puppy revealed the extraluminal compression of both cervical tracheal and esophageal lumens (De Armond *et al.*, 2017).

An exploratory approach was selected over other non-invasive techniques in our case. The decision was made based on the emergency condition detailed by the radiographic result and clinical presentation. Various time-consuming diagnostic procedures during anesthesia were not considered appropriate. Moreover, the owner had limited financial means and was unwilling to risk multiple methods which postponed the treatment period without ensuring a positive result. In addition, the narrowing luminal silhouettes indicated a tracheal wall deformity, for which surgical reconstruction is strongly recommended.

In minor tracheal stenosis cases, balloon catheter dilation or bougienage with endoscopic or fluoroscopic guidance can be effective, but resection and anastomosis would provide a better outcome in a severe case. Tracheal stenosis secondary to the previous external trauma has been recently reported in two dogs and one horse (Barnett *et al.*, 2015; Mutlu *et al.*, 2003; Smith *et al.*, 1990), all of which were treated with surgery involving tracheal resection and anastomosis. In addition, this surgical procedure was also done in a report on a puppy with a compressive deformity of the trachea caused by a cervical extratracheal band (De Armond *et al.*, 2017). In general, the trachea can be resected up to 20 to 50% of the total length in adult dogs depending on elasticity and tension. Less than 14 tracheal rings can be removed safely in puppies aged 12 to 18 weeks. With limited resection of the tracheal length, the anastomosis site will not encounter high tension and ischemic necrosis (MacPhail, 2013; Nelson, 2003).

Our case involved a tracheal resection of 6% which was intra-operatively measured and compared to the total length of the trachea using the radiographic view. Different techniques have been compared for tracheal anastomosis. In one study, continuous suturing was time-effective and provided the least variability in pullout strength (Demetriou *et al.*, 2006). In addition, simple interrupted suturing reinforced with horizontal mattress suture patterns as performed in our case provided biomechanical superiority over a simple interrupted pattern alone in the same study. Postoperative tracheal stenosis can result in a case of excessive tension at the anastomosis site at which dehiscence and second intention healing occur (MacPhail, 2013). Furthermore, a chronic constriction wound should be completely debrided and reconstructed to prevent tracheal compression in the future as has been reported (Westermeyer *et al.*, 2009). The postoperative complications mentioned above did not occur in the current case based on a 1.5 year follow-up period.

In conclusion, this study highlights the significant impact of a forgotten rubber band which penetrated the trachea and the resultant excessive fibrous scarring caused narrowing lumen leading to a fatal complication. The surgical treatment was accomplished with a good outcome based on a long follow-up period.

For public awareness, we encourage all owners to be careful in using rubber bands on their animal's body to avoid tragic consequences. In particular, people should realize the miserable consequences for the animal from the forgotten event. For clinicians, the rubber band syndrome should be listed as a differential diagnosis in every case involving the key feature of a chronic linear draining constricting wound. Especially in young animals, where rapid tissue healing is common, early investigation and intervention could decrease the severity, prevent adverse consequences, and improve patient survival.

### Acknowledgements

The radiography result was interpreted by Dr. Piyatip Choochalernporn, DVM, from the Kasetsart Veterinary Imaging and Radiotherapy Center, Kasetsart University Veterinary Teaching Hospital, Bangkok, Thailand.

### References

- Agarwal A, Kant KS and Verma I 2013. The rubber band syndrome: the forgotten rubber band in the wrist. *Hand Surg.* 18(3): 407-410.
- Aggarwal AN, Kini SG, Arora A, Gupta S and Gulati D 2010. Rubber band syndrome – high accuracy of clinical diagnosis. *J Pediatr Orthop.* 30(7): e1-4.
- Al-hamzawi NK and Al-Khanfar DD 2018. Rubber band wrapped circumferentially beneath the skin of the penis. *Int J Case Rep Images.* 9. [Online]. Available: [www.ijcasereportsandimages.com](http://www.ijcasereportsandimages.com). Accessed June 21, 2018.
- Arora A and Agarwal A 2004. Dhaga syndrome: a previously undescribed entity. *J Bone Joint Surg Br.* 86(6): 282-284.
- Barnett TP, Hawkes CS and Dixon PM 2015. Tracheal resection and anastomosis after traumatic tracheal stenosis in a horse. *Vet Surg.* 44(2): 265-269.
- Brisson BA and Théoret MC 2008. Osteolysis of the radius and ulna induced by a circumferential foreign body in a cat. *J Am Vet Med Assoc.* 233(7): 1117-1120.
- Brown JB 1963. Thermodynamics of a rubber band. *Am J Phys.* 31(5): 397.
- De Armond C, Nilmura Del Barrio MC, Rosati T, McAllister H and Ryan J 2017. Tracheal constriction in a growing dog. *Vet Rec Case Rep* 5(1). [Online]. Available: <https://vetrecordcasereports.bmj.com>. Accessed March 7, 2017.
- Demetriou JL, Hughes R and Sissener TR 2006. Pullout strength for three suture patterns used for canine tracheal anastomosis. *Vet Surg.* 35(3): 278-283.
- Glew G 1967. Elastic band injuries. *Br Med J.* 4(5577): 488.
- Goodnight ME, Scansen BA, Kidder AC, Cooper ES and Butler AL 2010. Use of a unique method for removal of a foreign body from the trachea of a cat. *J Am Vet Med Assoc.* 237(6): 689-694.
- Hoffer M and Estrin M 2006. Tourniquet injury: a case report and review of the literature. *Intern J Appl Res Vet Med.* 4(1): 67-73.
- Kim JH, Park C, Moon SJ, Kang MH and Park HM 2012. Incomplete tracheal intussusception in a dog. *Vet Radiol Ultrasound.* 53(3): 333-335.
- Kumar KM and Shankarappa M 2013. Rubber band syndrome of the arm. *J Hand Microsurg.* 5(2): 83.
- Lebreton M, Bosmassi E and Etchepareborde S 2017. Management of a tracheal intussusception in a dog. *Can Vet J.* 58(7): 695-698.
- MacPhail CM 2013. Surgery of the upper respiratory system. In: *Small Animal Surgery.* 4<sup>th</sup> ed. TW Fossum (ed). St. Louis: Elsevier. 906-957.
- Maher JL, Mahabir RC, Read LA 2011. Acute macroglossia in the pediatric patient: worth a look. *Pediatr Emerg Care.* 27(10): 948-949.
- Meier R, Haug L, Surke C, Mathys L and Vögelin E 2019. Acquired constriction ring: a case of rubber band syndrome. *Pediatr Emerg Care.* 35(6): e113-e115.
- Merck MD and Miller DM 2013. Asphyxia. In: *Veterinary Forensics: Animal Cruelty Investigations.* 2<sup>nd</sup> ed. MD Merck (ed). Oxford: John Wiley and Sons 169-184.
- Mutlu Z, Acar SE and Perk C 2003. Treatment of a case of tracheal stenosis in a dog with tracheal resection and anastomosis. *Vet Med Czech.* 48(11): 339-342.
- Nelson AW 2003. Disease of the trachea and bronchi. In: *Textbook of Small Animal Surgery.* 3<sup>rd</sup> ed. D Slatter (ed). Philadelphia: Saunders 858-880.
- Nutt LK, Webb JA, Prosser KJ and Defarges A 2014. Management of dogs and cats with endotracheal tube tracheal foreign bodies. *Can Vet J.* 55(6): 565-568.
- Roach W and Krahwinkel DJ 2009. Obstructive lesions and traumatic injuries of the canine and feline tracheas. *Compend Contin Educ Vet.* 31: 86-93.
- Sadler VM and Wisner ER 2000. What is your diagnosis? Circumferential foreign body within the soft tissues of the neck and pronounced tracheal

- compression. *J Am Vet Med Assoc.* 216(11): 1723-1724.
- Schultz RM and Zwingerberger A 2008. Radiographic, computed tomographic, and ultrasonographic findings with migrating intrathoracic grass awns in dogs and cats. *Vet Rad Ultrasound.* 49(3): 249-255.
- Smith MM, Gourley IM, Amis TC and Kurpershoek C 1990. Management of tracheal stenosis in a dog. *J Am Vet Med Assoc.* 196(6): 931-934.
- Somrup L, Kompach K, Srisawat W and Akatvipat A 2017. A case study: the slippery foreign body aspiration in a dog. *Chiang Mai Vet J.* 15(2): 89-97.
- Stelmach D, Sharma A, Rosselli D and Schmiedt C 2014. Circumferential cervical rubber band foreign body diagnosis in a dog using computed tomography. *Can Vet J.* 55(10): 961-964.
- Tenwolde AC, Johnson LR, Hunt GB, Vernau W and Zwingerberger AL 2010. The role of bronchoscopy in foreign body removal in dogs and cats: 37 cases (2000-2008). *J Vet Intern Med.* 24(5): 1063-1068.
- Tivers MS and Moore AH 2006. Tracheal foreign bodies in the cat and the use of fluoroscopy for removal: 12 cases. *J Small Anim Pract.* 47(3): 155-159.
- Westermeyer HD, Tobias KM and Reel DR 2009. Head and neck swelling due to a circumferential cicatricial scar in a dog. *J Am Animl Hosp Assoc.* 45(1): 48-51.
- Whitaker J, Dempsey M and Mosahebi A 2013. Elastic band, friend or foe? a case of digital amputation following accidental elastic band application and a review of the literature. *Emergency Med.* 3(4): 149. [Online]. Available: <http://dx.doi.org/10.4172/2165-7548.1000149>. Accessed August 16, 2013.