

## **Treatment of Pododemodiosis in A Geriatric Dog Using Spot – On Formulation of Moxidectin Plus Imidacloprid: Case Report**

**Piyarat Chansiripornchai<sup>1\*</sup> Niwat Chansiripornchai<sup>2</sup>**

### *Abstract*

A 9 – year – old, 6.2 kg female Shitsu dog with a repeated history of pododemodiosis was presented at the animal hospital. The dog had been previously treated with miticides such as ivermectin injections and oral milbemycin oxime, but the clinical signs recurred every time after the therapy had been stopped. Microscopic examination of skin samples from the dog revealed the presence of *Demodex canis*. A spot – on formulation composed of 2.5% moxidectin and 10% imidacloprid was applied to the dog weekly. The dog's skin lesions decreased by week 3 and the lesions completely resolved by week 6. There were no neurological abnormalities in the dog throughout the treatment.

---

**Keywords:** dog, geriatric, moxidectin, pododemodiosis

<sup>1</sup>Department of Veterinary Pharmacology, Faculty of Veterinary Science, Chulalongkorn University, Bangkok 10330, Thailand

<sup>2</sup>Department of Veterinary Medicine, Faculty of Veterinary Science, Chulalongkorn University, Bangkok 10330, Thailand

\*Correspondence: [spiyarat@hotmail.com](mailto:spiyarat@hotmail.com)

## Introduction

Canine demodicosis, a disease regularly seen in small animal practice, is caused by *Demodex canis*, which is a normal member of a dog's cutaneous ecology but can, in some situations, overpopulate, resulting in skin disease (Sischo et al., 1989). Demodicosis can be categorized into localized and generalized forms (Shipstone, 2000). Generalized demodicosis (GD) can be one of the most frustrating of skin diseases (Singh et al., 2011). Demodectic mange is regarded as GD if localized disease is present at 5 or more sites on the skin surface, if an entire body region is affected, or if it appears on 2 or more feet, a condition known as pododemodicosis (Shipstone, 2000). A common complication of GD is a secondary bacterial infection since large number of mites could damage the follicular wall and thus facilitate the development of pyoderma (Kuznetsova et al., 2012). In some dogs the pyoderma can progress to cause systemic signs such as fever, lethargy, anorexia and the potential of sepsis and death (Kuznetsova et al., 2012). The lesions seen with GD are variable and may include follicular papules, folliculitis and furunculosis with severe hemorrhagic exudation and thick crusting (Mueller, 2004). Despite recent advances in the understanding of its pathogenesis and the development of new miticides, GD remains a very challenging disease to treat effectively (Paterson et al., 2009).

Many different treatment options for demodicosis have been reported. Amitraz and macrocyclic lactones (ivermectin, milbemycin oxime, moxidectin and doramectin) have been shown to be effective in a number of case series (Mueller et al., 2012). However, adverse drug reactions (ADR) can occur. The ADRs caused by amitraz include vomiting, diarrhea, hyperglycemia, bradycardia and depression. Macrocyclic lactones can cause lethargy, tremors, mydriasis, ataxia, coma and death (in sensitive individuals) (Mueller, 2004).

Recently, there is a spot - on formulation of ectoparasiticide recommended for treatment of demodicosis (Mueller et al., 2012). It is a combination of 2.5% moxidectin and 10% imidacloprid that provides control of ectoparasites such as fleas and mites. Moxidectin has been reported as successful in treating canine demodicosis when given orally at a dosage of 0.2 - 0.5 mg/kg and topically once a week (Mueller et al., 2012). Although ADRs from oral moxidectin are similar to those observed with ivermectin, spot - on formulation of moxidectin causes only local inflammation and can, thus be safely used on geriatric dogs (Mueller et al., 2012).

This report reveals the successful treatment of pododemodicosis in a geriatric dog using a spot - on formulation of moxidectin plus imidacloprid.

## Case History and Clinical Examination

A 9 - year - old, 6.2 kg neutered female Shitsu dog with a year - long history of repeated pododemodicosis was presented at a skin clinic in Suvarnachad animal hospital, Bangkok, Thailand. The dog had been treated with both parenteral ivermectin

and oral milbemycin preparations on separate occasions but the clinical signs recurred every time after the therapy had stopped for 4 - 8 weeks. Moreover, the dog showed clinical signs of adverse neurological effects such as ataxia and drowsiness during therapy with those drugs.

Physical examination revealed deep folliculitis with hemorrhagic exudation and crust on all four legs (Fig 1a). Multiple skin scrapings were taken and examined microscopically in paraffin oil, while other portions were stained with Gram's staining. Microscopic examination revealed the presence of adult demodectic mange (Fig 1b) and a number of cocci bacteria. Hematology and blood chemistries were in normal range in the dog.

## Results and Discussion

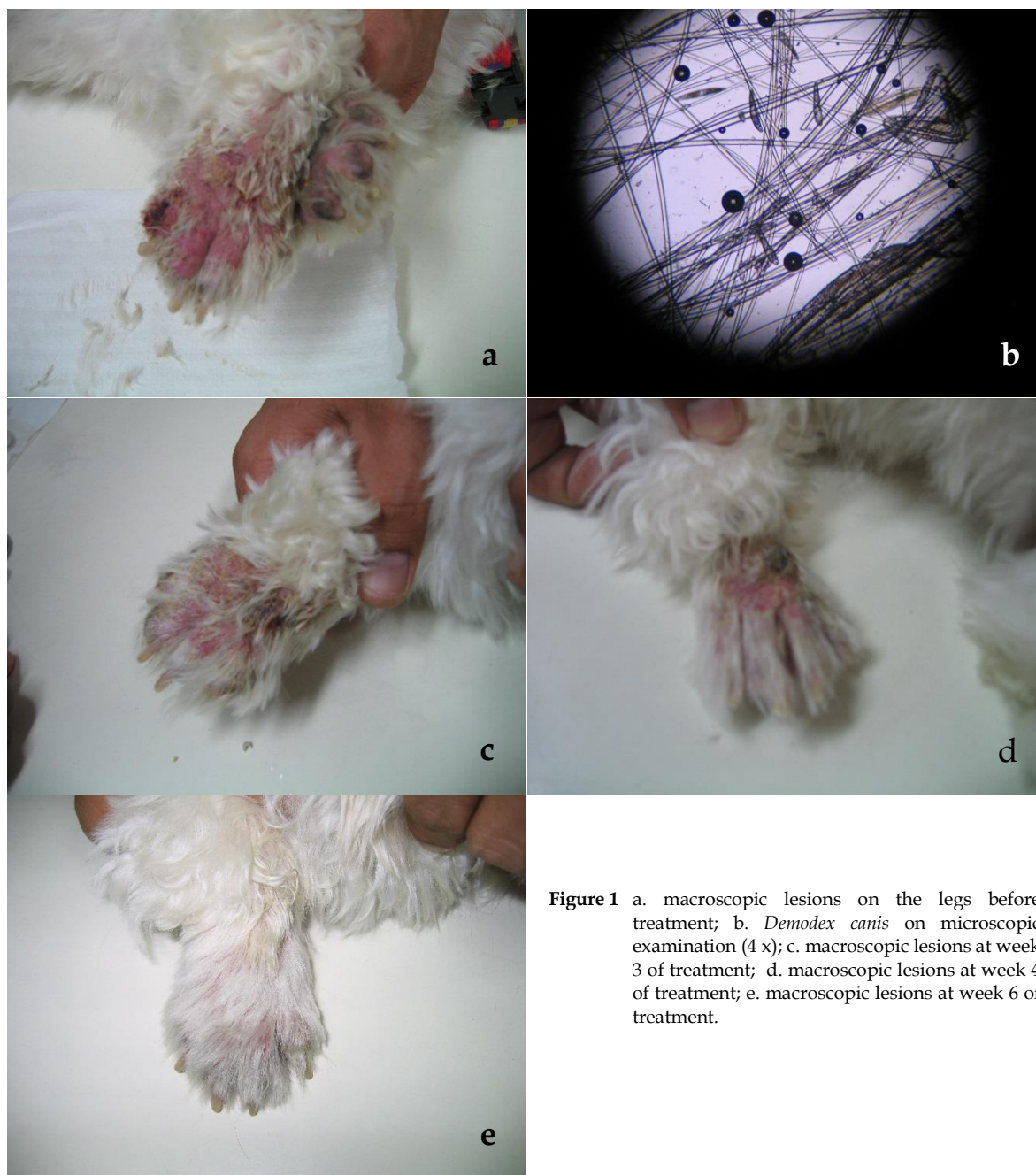
A spot - on formulation of 2.5% moxidectin and 10% imidacloprid (Advocate<sup>®</sup>, Bayer, Germany), at the proposed minimum dose rate of 2.5 mg/kg of moxidectin was applied to the skin as a single spot between the shoulder blades of the dog once a week.

Amoxicillin - clavulanic acid (Clavamox<sup>®</sup>, Zoetis, USA) at 15 mg/kg PO every 12 h, hydroxyzine (Atarax<sup>®</sup>, OLIC, Thailand) at 2 mg/kg PO every 12 h and vitamin E (Mega Life science LTD., Australia) 200 mg PO every 24 h were also prescribed for 4 weeks. Skin scrapings and the general health of the dog was monitored at intervals of 2 - 3 weeks.

A typical treatment outcome was observed after 3 weeks of treatment (Fig 1c) and hair reappeared by week 4 of the treatment. The resolution of the condition was completed after 6 weeks (Fig 1e). At week 8, no live mites or eggs were found on the dog. Parasitological cure was defined by skin scraping that were negative for evidence of any life stage on two consecutive occasions one month apart. (Paterson et al., 2009). No recurrent clinical signs of pododemodicosis were observed during the 4 month follow-up period.

It is critical to select safe miticides to use with geriatric animals since the ADRs can develop easily in such animals. A spot - on formulation of moxidectin plus imidacloprid is a broad spectrum antiparasitic drug (Paterson et al., 2009). It has been approved as a weekly treatment for canine demodicosis in Europe (Mueller et al., 2012). Currently, the drug can be recommended as a weekly treatment for dogs with mild forms of GD. However, if significant improvement is not seen within the first few weeks, other therapy may be indicated (Mueller et al., 2012).

In this report, a spot - on formulation of moxidectin plus imidacloprid was selected for use as a treatment of pododemodicosis in a geriatric dog since the ADRs from moxidectin plus imidacloprid spot - on formulation is less common than from other macrocyclic lactones and amitraz (Mueller et al., 2012). As a result, treatment with a spot - on formulation of moxidectin plus imidacloprid at the recommended dosage, once a week for 6 weeks resulted in a reduction of mites and improved clinical skin lesions. On the other hand, the frequent failure of treatment for demodicosis may result from poor pyoderma control,



**Figure 1** a. macroscopic lesions on the legs before treatment; b. *Demodex canis* on microscopic examination (4 x); c. macroscopic lesions at week 3 of treatment; d. macroscopic lesions at week 4 of treatment; e. macroscopic lesions at week 6 of treatment.

too short duration of therapy, unsuccessful control of underlying conditions, and low quality diet (Singh et al., 2011; Mueller et al., 2012). Antibiotics and antipruritics were prescribed for treatment of secondary bacterial skin infection. Vitamin E was prescribed as a skin supplement for demodicosis. As for the skin lesions, folliculitis and crusts had decreased by week 3, while hair regrowth had improved by more than 60% by week 4 (Fig 1d). There were no other clinical signs, such as neurological abnormality in the dog throughout the treatment. These findings suggest that weekly application of the drug represents a promising new approach to the treatment of pododemodicosis that is easy to administer and showed no ADRs.

Pododemodicosis in a geriatric dog was successfully treated with a spot - on formulation of moxidectin plus imidacloprid at the proposed minimum dose rate applied once a week for 6 weeks.

Resolution of the condition was complete and ADRs did not occur.

### References

- Kuznetsova E, Bettenay S, Nikolaeva L, Majzoub M and Mueller R 2012. Influence of systemic antibiotics on the treatment of dogs with generalized demodicosis. *Vet Parasitol.* 188: 148 - 155.
- Mueller RS 2004. Treatment protocols for demodicosis : an evidence - based review. *Vet Dermatol.* 15: 75-89.
- Mueller RS, Bensignor E, Ferrer L, Holm B, Lemarie S, Paradis M and Shiptone MA 2012. Treatment of demodicosis in dogs: 2011 clinical practice guidelines. *Vet Dermatol.* 23: 86-96.

- Paterson TE, Halliwell RE, Fields PJ, Louw ML, Louw JP, Ball GS, Pinckney RD and McKibben JS 2009. Treatment of canine – generalized demodicosis: a blind, randomized clinical trial comparing the efficacy of Advocate<sup>R</sup> (Bayer Animal Health) with ivermectin. *Vet Dermatol.* 20: 447-454.
- Shipstone M 2000. Generalised demodicosis in dogs, clinical perspective. *Aus Vet J.* 78: 240-242.
- Singh SK, Kumar M, Jadhav RK and Saxena SK 2011. An update on therapeutic management of canine demodicosis. *Vet World.* 4: 41-44.
- Sischo WM, Ihrke PJ and Franti CE 1989. Regional distribution of ten common skin diseases in dogs. *J. Am. Vet. Med. Assoc.* 195: 752-756.

## บทคัดย่อ

การรักษาไข้เรื้อนขุมขนที่เท้าในสุนัขอายุมากด้วยยาหยดบนผิวหนังที่ประกอบด้วย

ม็อกซีเด็กตินและอิมิดาโคลพริด: รายงานสัตว์ป่วย

ปิยะรัตน์ จันทรศิริพรชัย<sup>1\*</sup> นิวัตร จันทรศิริพรชัย<sup>2</sup>

สุนัขพันธุ์ชิทสุ เพศเมีย อายุประมาณ 9 ปี น้ำหนักตัว 6.2 กก. เข้ารับการรักษาที่โรงพยาบาลสัตว์ด้วยโรคไข้เรื้อนขุมขน บริเวณเท้าทั้งสี่ สุนัขมีประวัติการรักษาโรคดังกล่าวด้วยยากุ่มออกฤทธิ์ต้านไรเซน การฉีดยาไอเวอร์เมกตินและการกินยาอิมัลบีมัยซินซึ่งพบว่าเมื่อหยุดการให้ยาระยะหนึ่งสุนัขก็กลับเป็นโรคขึ้นใหม่ ผลการตรวจตัวอย่างผิวหนังของสุนัขพบไรซ์เรื้อนขุมขน ดีโมเด็กซ์ เคนิส ให้การรักษาสุนัขด้วยยาภายนอกที่ประกอบด้วยม็อกซีเด็กติน 2.5 % และ อิมิดาโคลพริด 10 % หยดลงบนผิวหนังสุนัขสัปดาห์ละครั้งต่อเนื่องกัน ภายหลังจากการรักษาพบว่ารอยโรคบนผิวหนังของสุนัขลดลงในสัปดาห์ที่ 3 ของการรักษาและรอยโรคบนผิวหนังหายไปทั้งหมดในประมาณสัปดาห์ที่ 6 ของการรักษา นอกจากนี้ไม่พบอาการผิดปกติของระบบประสาทในสุนัขตลอดการรักษา

---

**คำสำคัญ:** สุนัข อายุมาก ม็อกซีเด็กติน ไข้เรื้อนขุมขนที่เท้า

---

<sup>1</sup>ภาควิชาเภสัชวิทยา คณะสัตวแพทยศาสตร์ จุฬาลงกรณ์มหาวิทยาลัย ปทุมวัน กรุงเทพฯ 10330

<sup>2</sup>ภาควิชาอายุรศาสตร์ คณะสัตวแพทยศาสตร์ จุฬาลงกรณ์มหาวิทยาลัย ปทุมวัน กรุงเทพฯ 10330

\*ผู้รับผิดชอบบทความ E-mail: spiyarat@hotmail.com