

What is Your Diagnosis?

Nan Choisunirachon

Signalment

A five-year-old, female Golden Retriever.

History

The patient was presented to the Small Animal Teaching Hospital, Chulalongkorn University with the chief complaints of dyspnea and sneezing for a few weeks. The dog had been diagnosed twice and treated for blood parasitic infection.

Clinical examination

General clinical conditions, which were hydration status, mucus membrane color, heart sound and lung sound, were normal. However, the subcutaneous swelling above the left nasal bone could be detected. The swelling was soft in consistency on palpation. Laboratory data, including complete blood count and serum biochemistry were within normal limits.

Radiographic examination

Skull radiographs were obtained in both dorsoventral (DV) and right lateral views (Fig 1A and 1B) to investigate the nasal abnormalities and adjacent tissue involvement.

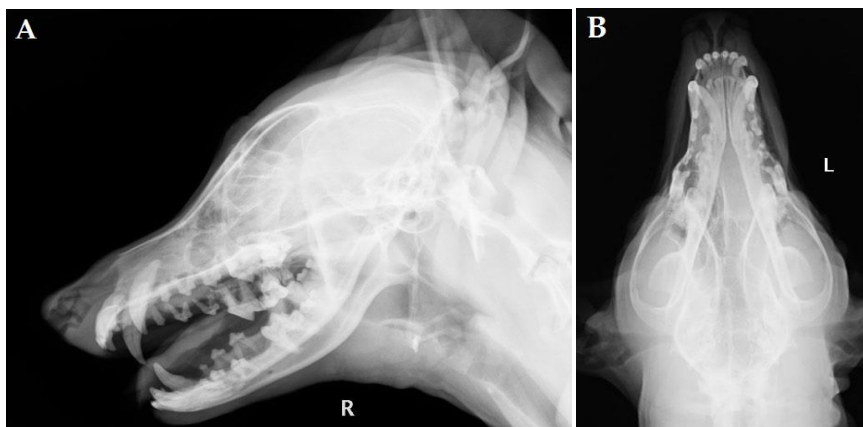


Figure 1 Skull radiographs of the right lateral view (A) and dorsoventral view (B)

What is your diagnosis?

Please turn to next page for the answer.

Department of Veterinary Surgery, Faculty of Veterinary Science, Chulalongkorn University, Bangkok 10330, Thailand

Radiographic findings

On plain radiographs of the skull (Figs 1A and 1B), an increase of soft tissue opacity at the left nasal cavity could be detected. The fainted nasal septum was unveiled at the mid nasal area on the DV view (Fig 1B). This could be caused by the osteolysis from the intranasal soft tissue mass. Other nasal bones were apparently normal. After radiographic examination, computed tomography (CT) was

performed to investigate the invasion of the mass into adjacent organs and to plan for biopsy procedure. On pre-contrast helical CT image (Fig 2A), the concha calcification and osteolytic lesions at the nasal septum and the retro bulbar nasal bone were detected. After contrast administration (Figs 2B and 3), the mass was slightly enhanced and the capsule of the invaded mass at the left retro bulbar area was distinctively revealed.

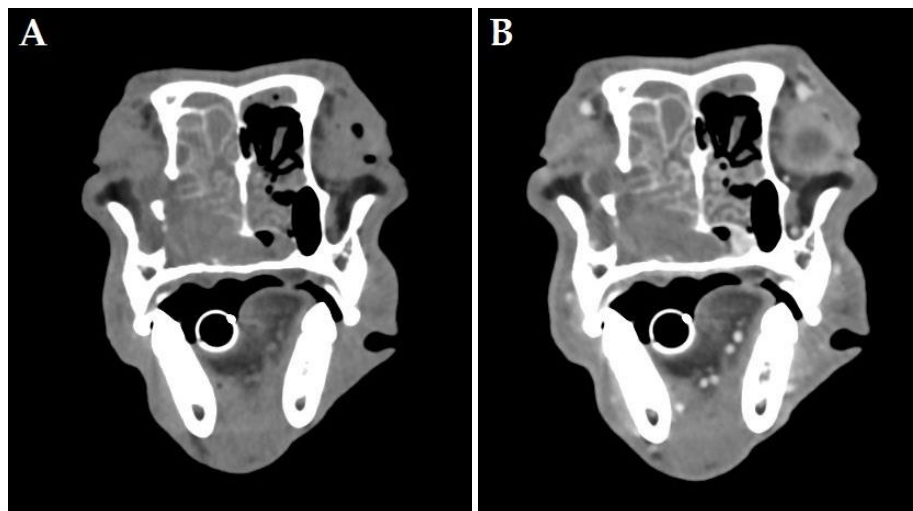


Figure 2 The helical CT images at the level of the infraorbital area. The soft tissue nasal mass revealed the concha calcification and there were bone lytic lesions at the nasal septum and nasal bone on the precontrast image (A). After contrast study, the mass was slightly enhanced. The capsule of left retrobulbar invaded mass could be detected (B).

Radiographic diagnosis

Nasal tumor (nasal chondrosarcoma).

Discussion

An increase of radio-opacity at the nasal cavity of canine patients could be caused by several factors, one of which is the nasal tumor. Nasal tumor is counting for 1-2% of tumor found in the dog (MacEwen et al., 1977). The mass could occupy in the hemi-lateral of the nasal cavity or invade into the adjacent organs such as contralateral nasal passage, frontal sinus, intracranial cavity and/or retrobulbar area that were seen in this patient. However, evaluation of the lesion details and invasion of adjacent organ for clinical staging and treatment planning by skull radiograph alone is not an ideal procedure due to the numerous superimposition bony structures. To date, CT reveals as a superior imaging modality for diseases of head and neck by displaying multiplanar reconstruction images of the interested organ that could be overcome with the disadvantage of 2-dimensional conventional radiographs (Ghirelli et al., 2013). Besides, CT could increase a diagnostic sensitivity of gray scale images to differentiate clinical lesions, such as small bony lesions, by adjustable window width and window level. Therefore, for hiding lesions on the complex structure like head and neck area, applying an advanced imaging as CT could be a superior tool for diagnostic and treatment plans in clinical usage.

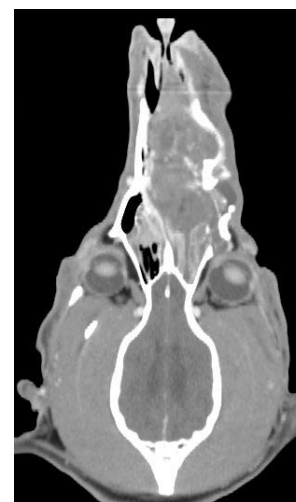

Figure 3 Coronal CT image at the lower zygomatic level revealed the soft tissue mass extended from the cranial nasal passage through the caudal sinonasal area. The mass invaded into the left retrobulbar area.

References

- Ghirelli CO, Villamizar LA and Pinto AC 2013. Comparison of standard radiograph and computed tomography in 21 dogs with maxillary masses. *J Vet Dent.* 30(2): 72-76.
- MacEwen EG, Withrow SJ and Patnaik AK 1977. Nasal tumors in the dog: retrospective evaluation of diagnosis, prognosis, and treatment. *J Am Vet Med Assoc.* 170(1): 45-48.