

Immunohistochemical staining of peroxisome proliferator-activated receptor alpha and gamma in normal, benign, and malignant canine mammary tissues

Wuthichai Klomkleaw¹ Promporn Raksaseri^{1*}

Abstract

The peroxisome proliferator-activated receptors (PPARs) belong to nuclear receptor superfamily acting as transcription factors related to lipid and glucose metabolism. There are 3 subtypes including PPAR α , PPAR γ , and PPAR δ . PPAR α and PPAR γ activations can inhibit tumor cell proliferation and differentiation in many cell types. However, the expressions of these receptors in canine mammary tissue are still unknown. This study was performed to investigate the expressions of PPAR α and PPAR γ in normal, benign, and malignant canine mammary tissues. Twenty four bitches at the age of 5-15 years old, which undergone unilateral mastectomy, were used in the study. Mammary tissues were sectioned and histologically diagnosed by H&E staining, 12 were benign and another 12 were malignant. In each dog, tissues were collected from both normal and tumor area. Immunohistochemical staining has demonstrated that both PPAR α and PPAR γ express mainly in cytoplasm, perinucleolar region, and some nuclei of glandular epithelial cells, ductal epithelial cells, and myoepithelial cells. Lower expression of the receptors were found in fibroblasts, macrophages, endothelial cells and smooth muscle cells of blood vessels. Cytoplasmic immunoreactivities of these receptors were calculated into H-score. H-score of PPAR α in benign type and PPAR γ in malignant type were significantly higher than in normal tissue ($P<0.05$). According to the expression of these receptors in normal canine mammary tissue and receptor upregulation in tumor cells suggested that PPAR α and PPAR γ may play a role in canine mammary gland function and might be related to the pathogenesis or progression of canine mammary gland tumors.

Keywords: canine, mammary glands, tumors, PPAR α , PPAR γ

¹Department of Anatomy, Faculty of Veterinary Science, Chulalongkorn University, Bangkok 10330, Thailand

*Correspondence: Promporn.R@chula.ac.th

Introduction

Peroxisome proliferator-activated receptors (PPARs) are members of the nuclear receptor superfamily. They act as transcription factors that regulate transcription of genes involving in lipid and glucose homeostasis (Lehrke and Lazar, 2005). In mammalian tissues, there are three subtypes of PPARs, which are PPAR α , PPAR γ , and PPAR β/δ (Michalik et al., 2006). PPAR α is principally expressed in tissues involving lipid catabolism, including liver, kidney, adipocytes, and heart (Reddy and Hashimoto, 2001). PPAR γ is mainly expressed in adipocytes, liver, gastrointestinal tract, kidney, brain, and vascular tissues, whereas PPAR β/δ is ubiquitously expressed in all tissues (Braissant et al., 1996; Michalik et al., 2006). PPAR γ regulates transcription of gene related to adipogenesis and adipocyte differentiation, whereas PPAR β/δ regulates genes involved in fatty acid oxidation (Wang et al., 2003; Tontonoz and Spiegelman, 2008).

PPARs play roles in mammary lipid biosynthesis and have been identified in mammary glands (Braissant et al., 1996; Jain et al., 1998; Roberts-Thomson and Snyderwine, 2000). All PPARs subtypes are expressed in adipocytes and epithelial cells of rodent mammary gland. However, PPAR α and PPAR γ are thought to be involved in lobuloalveolar development of mammary gland because the expression of PPAR α and PPAR γ decrease during pregnancy and lactation, while PPAR δ remains unchanged (Gimble et al., 1998).

PPAR α and PPAR γ have been demonstrated to relate with tumorigenesis. PPAR γ activation has been shown to inhibit tumor growth and transformation in many types of tissues, including colon, prostate gland, lung and mammary gland (Blanquicett et al., 2008; Conzen, 2008; Ban et al., 2011). Breast cancer is one of the most prevalent cancers in woman with high mortality rate. Rosiglitazone, a PPAR γ synthetic agonist, appears to inhibit proliferation and differentiation, but induces apoptosis in breast cancer cell lines (Elstner et al., 1998). PPAR γ has also shown anti-inflammatory effect, at least in part by inhibition of pro-inflammatory mediator productions, such as TNF α and IL-6, both in tissues and cell cultures (Youssef and Badr, 2011). In vivo study in mice has demonstrated that PPAR γ activation down-regulates the expression of cox-1, cox-2, and cyclin D in mammary secretory epithelial (MSE) cells, resulting in the inhibition of mammary tumor growth. Additionally, a decrease in PPAR γ expression in PPAR γ -MSE knockout mice promotes appropriate environment for breast cancer growth and this risk factor could be protected by PPAR γ activation (Apostoli et al., 2014). These data suggest that the expression of PPAR γ is related to mammary gland tumorigenesis and PPAR γ activation can suppress mammary tumor growth.

It is still controversial that PPAR α activation enhance tumorigenesis or apoptosis, which is thought to depend on species difference and type of tissues. In rodents, prolong activation of PPAR α promote hepatic proliferation and tumor growth (Gonzalez and Shah, 2008). However, recent study has shown that

fenofibrate, a PPAR α agonist, reduce the viability of myeloma and lymphoma cell line due to induction of apoptosis (Schmeel et al., 2017). The expression of PPAR α has been reported in human, rat and mouse mammary gland, including human breast cancer cell line MCF-7 and MDA-MB-231 (Roberts-Thomson and Snyderwine, 2000; Suchanek et al., 2002). Unlike PPAR γ , PPAR α activation in human breast cancer cell line enhances cell proliferation (Suchanek et al., 2002). Although the roles of PPAR γ and PPAR α activation have been widely studied in human breast cancer, little is known about their roles in canine mammary gland tumor.

Even though the sequences of PPAR α , PPAR γ , and PPAR δ/β have also been identified in canine tissues, there is still limited data about the expressions of PPARs in normal and neoplastic canine mammary tissues. Additional knowledge in this study will definitely provide useful information for future studies and lead to better treatment of canine mammary gland tumors.

Therefore, the aim of this study was to investigate the expressions and localizations of PPAR α and PPAR γ in normal canine mammary tissue and also the alteration in the expressions of PPAR subtypes in benign and malignant canine mammary tissues.

Materials and Methods

Ethics Statement: This study has been reviewed and approved by the Institutional Animal Care and Use Committee (IACUC) in accordance with university regulations and policies governing the care and use of laboratory animals (Animal Use Protocol No. 1531044). The protocol has followed the guidelines documented in Ethical Principles and Guidelines for the Use of Animals for Scientific Purposes edited by the National research Council of Thailand. The rat brain tissue samples were obtained from a project in Department of Physiology which has been approved by Animal Care and Use Committee, Faculty of Science, Mahidol University (Animal Use Protocol 57-011-306).

Tissues: Normal (non-neoplastic) and neoplastic mammary tissues were achieved from Obstetrics Unit, Chulalongkorn University Small Animal Hospital. The samples were selected from 24 female dogs aged 5-15 years old that undergone mastectomy due to mammary gland tumors. In each bitch, tissue samples were collected from 2 areas which are normal (non-neoplastic) and neoplastic areas. Mammary tissues were fixed in 4% paraformaldehyde for 24 to 72 h for immunohistochemistry and H&E staining. Fixed tissues were embedded in paraffin by routine procedures (Michel et al., 2012).

H&E staining: The paraffin-embedded tissues were sectioned to a thickness of 4.0 μ m and further stained with H&E in order to identify pathohistological forms of mammary tumors as benign or malignant type by pathologists (Department of Pathology, Faculty of Veterinary Science, Chulalongkorn University). The criteria of tumor identification, benign or malignant, was based on the Histologic Classification of

mammary tumors of the dog and the cat (Goldschmidt et al., 2011).

Immunohistochemistry staining: A standard immunoperoxidase immunohistochemical procedure was applied as previously described (Michel et al., 2012). Briefly, tissues on gelatin-coated slides were deparaffinized in xylene and rehydrated in graded ethanol. Antigen retrieval was performed using 10 mM sodium citrate buffer pH 6.0 microwave method at 550 watt for 5 min (3 times). After that, endogenous peroxidase was quenched for 30 min using 3 % (v:v) of hydrogen peroxide in methanol. Non-specific binding was blocked using 10% normal goat serum (Vector Laboratories, CA, USA) in PBS for 30 min. The sections were incubated over-night at 4°C with 1:200 dilution of rabbit polyclonal antibody against PPAR γ (ab66343, Abcam) or 1:200 dilution of rabbit polyclonal antibody against PPAR α (ab8934). After primary antibody binding, the sections were washed in PBST followed by incubation with the biotinylated goat-anti rabbit secondary antibody (Vector Laboratories, CA, USA). Immunoreactive staining of both PPAR subtypes were visualized using horseradish peroxidase avidin biotin complex (Vectastain ABC kits, vector Laboratories, CA, USA) and the 3,3' diaminobenzidine chromogen (ImmPACT DAB Peroxidase substrate kit, Vector Laboratories, CA, USA). Mayer's hematoxylin was used as a counterstain. Sections incubated without primary antibody were used as negative control, whereas rat brain tissue were used as positive control as Abcam product data sheet suggestions (Warden et al., 2016).

Evaluation of immunoreactivity of PPAR subtypes: The expressions of PPAR α and PPAR γ in canine mammary tissues were determined in three types of cells, including glandular epithelial cells, ductal

epithelial cells, and myoepithelial cells. Whole slides were digitalized using Pannoramic scan. (3DHISTECH, Budapest, Hungary) and the immunostaining were analyzed using image analysis software HistoQuant (3DHISTECH, Budapest, Hungary). The localization of PPAR subtypes in cytoplasm were evaluated by CellQuant (3DHISTECH, Budapest, Hungary) and PPAR subtypes H-score of canine mammary tissue were calculated and reported. Cytoplasmic staining of PPAR subtypes were scored according to the intensity of staining: 1+ for weak staining, 2+ for intermediate staining, and 3+ for strong staining. The results of PPAR subtypes were expressed as H-score calculated from 1 x (% of positive cells 1+ staining) + 2 x (% of positive cells 2+ staining) + 3 x (% of positive cells 3+ staining) formula (Mahmoud et al., 2017).

Statistical analysis: Results were presented as mean \pm S.E. of number of observations. The statistical differences between normal or non-neoplastic tissues (control group) and canine neoplastic tissues (benign or malignant) within each bitch were determined using paired t-test. Difference were considered statistically significant when * $P < 0.05$, compared with the control group.

Results

Differentiation of canine mammary gland tumors: The mean \pm SD age of the dogs in this study was 11.22 \pm 2.36. The identification of tumor types was performed using H&E staining. Using microscopic study, 12 out of 24 bitches were diagnosed benign canine mammary tumor and the other 12 dogs were diagnosed malignant mammary tumor, which are shown in table 1. Representative H&E staining of canine mammary tissues are presented in Figure 1.

Table 1 Differentiation of canine mammary tissues collected from 24 bitches determined by H&E staining.

Dog number	Benign type	Dog number	Malignant type
1	benign mixed mammary gland tumor	13	adenocarcinoma
2	simple tubular adenoma	14	papillary cystic mammary adenocarcinoma
3	benign mixed mammary gland tumour	15	solid tubular adenocarcinoma
4	benign mixed mammary gland tumor	16	complex adenocarcinoma grade I
5	complex adenoma with clusters of myoepithelial cells	17	malignant tubular mixed canine mammary gland tumour
6	mammary adenoma with eosinophilic lymphadinitis	18	solid mammary adenocarcinoma
7	complex mammary adenoma	19	tubular adenocarcinoma
8	ductal adenoma	20	mammary carcinoma with cyst of left axillary lymph node
9	benign mixed mammary gland tumor	21	malignant myoepithelioma
10	benign mixed adenoma	22	papillary adenocarcinoma grade I
11	benign mixed mammary gland tumour	23	papillary adenocarcinoma
12	benign mixed mammary gland tumour	24	tubulopapillary adenocarcinoma

Immunohistochemistry: Immunohistochemistry performed in rat brain tissue revealed cytoplasmic staining of rat ependymal cells and neurons indicating

the expressions of PPAR α and PPAR γ , respectively (fig. 2). These rat brain tissues were used as positive controls.

Specific signals of PPAR α and PPAR γ were detected in normal mammary tissue, benign, and malignant canine mammary tumors. The immunoexpressions of both PPAR subtypes were found in glandular epithelial cells, ductal epithelial cells, and myoepithelial cells of canine mammary tissue. PPAR α and PPAR γ positivities were expressed as brown-pigments distributed throughout cytoplasmic compartment, plasma membrane, and occasionally localized closed to the nucleus or within the nucleus of the cells. Both PPAR α and PPAR γ were also observed in endothelial cells and smooth muscle cells of blood vessels including in macrophages. However, the signals were mostly absent in connective tissue cells (fig. 3-5).

Evaluation of PPARs immunoreactivity: As shown in Fig.6, PPAR α expression evaluated using H-score of PPAR α immunoreactivity in benign mammary tissue increased significantly in comparison to normal mammary tissue (control group) ($P < 0.05$), however, there was no significant difference between malignant mammary tissue and normal tissue. In contrast, PPAR γ expression in malignant mammary tissue increased significantly compared to normal tissue ($P < 0.05$), but the expression of PPAR γ in benign mammary tissue did not change compared to normal mammary tissue (control group).

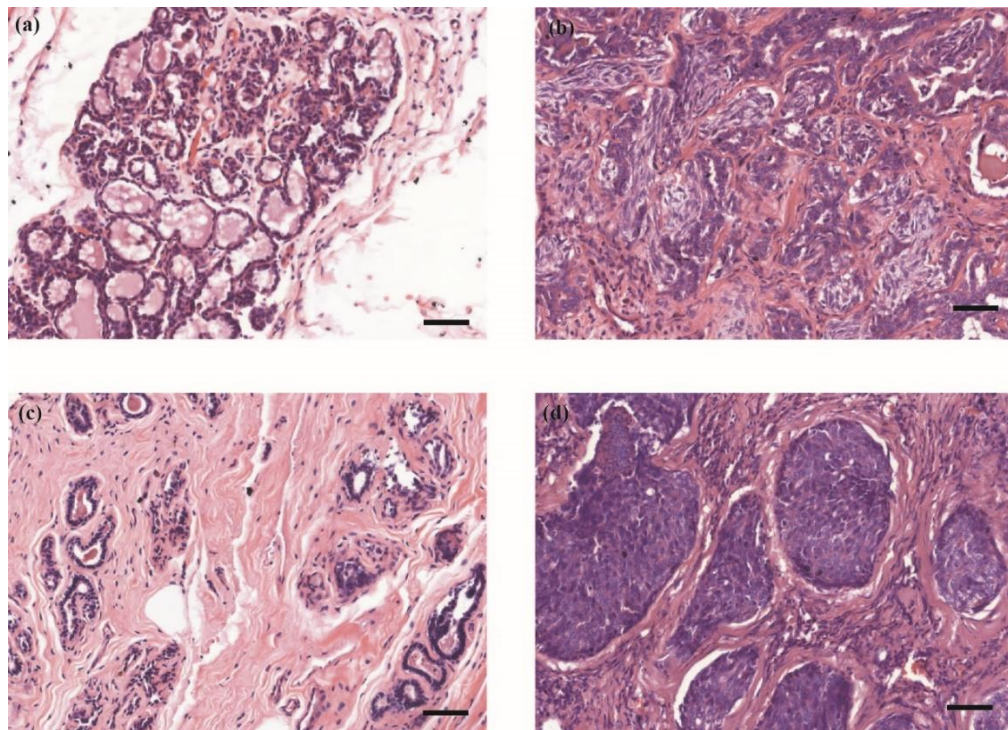


Figure 1 Hematoxylin and eosin staining of (a) normal canine mammary tissue and (b) the tissue developing benign mixed mammary gland tumor from the same bitch. H&E staining of (c) normal canine mammary tissue and (d) the tissue developing mammary adenocarcinoma from another bitch. Microscopic magnification at 20x. Bar = 50 μ m

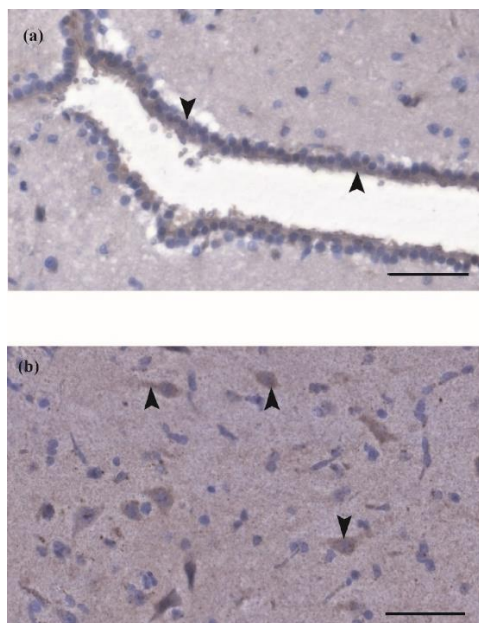


Figure 2 Immunohistochemistry of PPAR α (arrowhead) in cytoplasm of rat ependymal cells (a) and PPAR γ in neurons (b) used as positive controls. Microscopic magnification at 40x. Bar = 50 μ m.

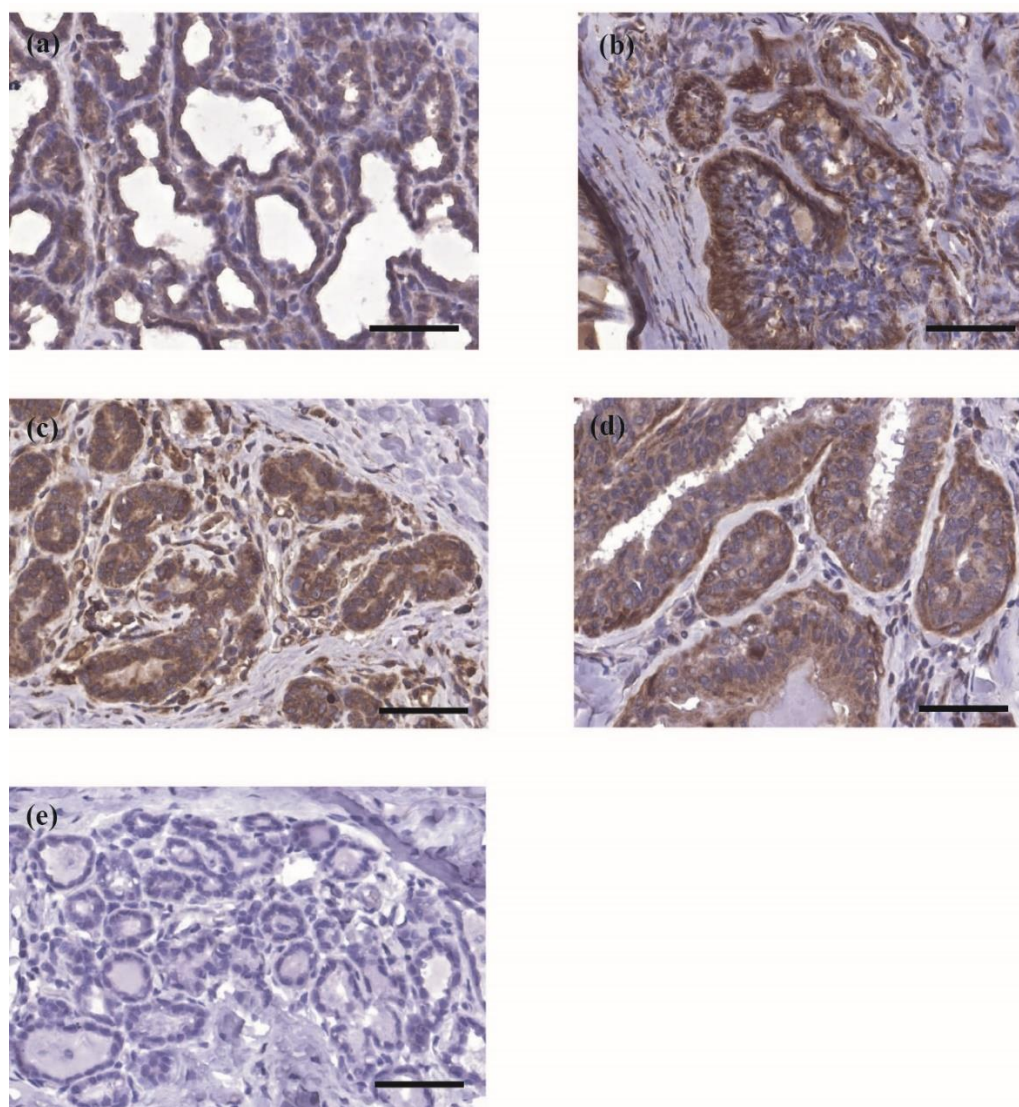


Figure 3 The immunohistochemical staining of PPAR α in canine mammary tissues. Immunoreactivity of PPAR α (brown in color) in non-neoplastic mammary tissue (control) (a) compared to benign mammary tumor tissue (b) from the same bitch. In mammary tissues from another bitch, PPAR α immunoreactivity of non-neoplastic mammary tissue (c) compared to malignant mammary tumor tissue (d). Mammary tissue staining with Mayer's hematoxylin (blue in color) was used as a negative control (e). Microscopic magnification at 40x. Bar =50 μ m.

Discussion

Our study evaluates the expressions of canine PPAR α and PPAR γ in normal canine mammary tissue compared to benign or malignant canine mammary tumors. Based on immunohistochemistry study, both PPAR α and PPAR γ diffusely express in the cytoplasm of glandular epithelium, ductal epithelium, and myoepithelial cells of normal mammary tissue and canine mammary gland tumors. In some cells, these receptors are also expressed in the plasma membrane. Moreover, the expression of both receptors were also found in the perinucleolar region and nuclei of some cells. PPARs are members of nuclear receptors, which their inactivation forms are basically located in the cytoplasm. Once ligand binding occurs, PPARs-ligand complex is translocated into the nucleus to bind with PPRE to the regulatory region of target genes, thereafter, expression of the receptors can be observed more in the nucleus. The expression and localization of PPAR γ has been demonstrated in macrophage-like cell line RAW 264 using Western blotting and confocal

microscopy. The results showed that PPAR γ was mainly observed in cytosol fraction in non-stimulated cells. After treatment with rosiglitazone (PPAR γ ligand), the receptor was observed in the nuclear fraction (Shibuya et al., 2002). Therefore, the localization of PPAR subtypes have a heterogeneous subcellular distribution as observed in the cytoplasm, nucleus, and luminal borders of epithelial cells, which are in agreement with many reports (Roberts-Thomson and Snyderwine, 2000; Mukunyadzi et al., 2003; Gao et al., 2013; Sozmen et al., 2013; Apostoli et al., 2014).

From our study, the expression of PPAR α in normal canine mammary tissue was moderate, and its immunoreactivity in benign mammary tumor was significantly stronger than that of normal tissues. Likewise, its immunoreactivity in the malignant type tended to be higher than normal tissue as well. Our results are similar to the evidence in rat, which showed that the mRNA of PPAR α expression was higher in mammary gland carcinoma than in normal mammary glands (Roberts-Thomson and Snyderwine, 2000). However, the PPAR α protein expression in rat

mammary gland has not been performed. A recent study showed that dog PPAR α shares 94.7 and 91.0% amino acid sequence identical with human and rat PPAR α . Especially in the LBD region, dog PPAR α has 97.0% and 92.4% sharing identical homology with human and rat PPAR α , respectively (Nagasawa et al., 2004). Several studies in human and rodents suggested the roles of PPAR α in tumor promotion by regulating genes involving in cell proliferation and apoptosis. In rodents, PPAR α has an ability to suppress apoptosis (Nahle, 2004) and the activation of PPAR α by fenofibrate has been shown to promote hepatic tumor at least in part by producing reactive oxygen species. (Reddy and Rao, 1989; Rusyn et al., 2000). A different result has been shown in glioblastoma cells showing that fenofibrate-induced PPAR α activation stimulates apoptosis mediated by nuclear translocation of FoXO3A (Wilk et al., 2012). In mammary glands,

PPAR α activation during pregnancy impairs the development of mammary gland in mice (Yang et al., 2006), on the other hand, activation of PPAR α promoted the proliferation of human breast cancer cell lines (Suchanek et al., 2002). These data suggested that the role of PPAR α activation on the suppression of cell proliferation or promotion of tumorigenesis depends on several factors including species, cell types, the stage of organ development, and stages of tumors. Taken together with our study, the upregulation of PPAR α in canine mammary gland tumors maybe a defence mechanism in response to the proliferation of mammary epithelial cells. Therefore, ligand-induced PPAR α receptor activation might be a target to beneficial treatment of canine mammary gland tumor. However, the effect of PPAR α activation on cell proliferation and apoptosis in canine mammary tumor needs further investigation.

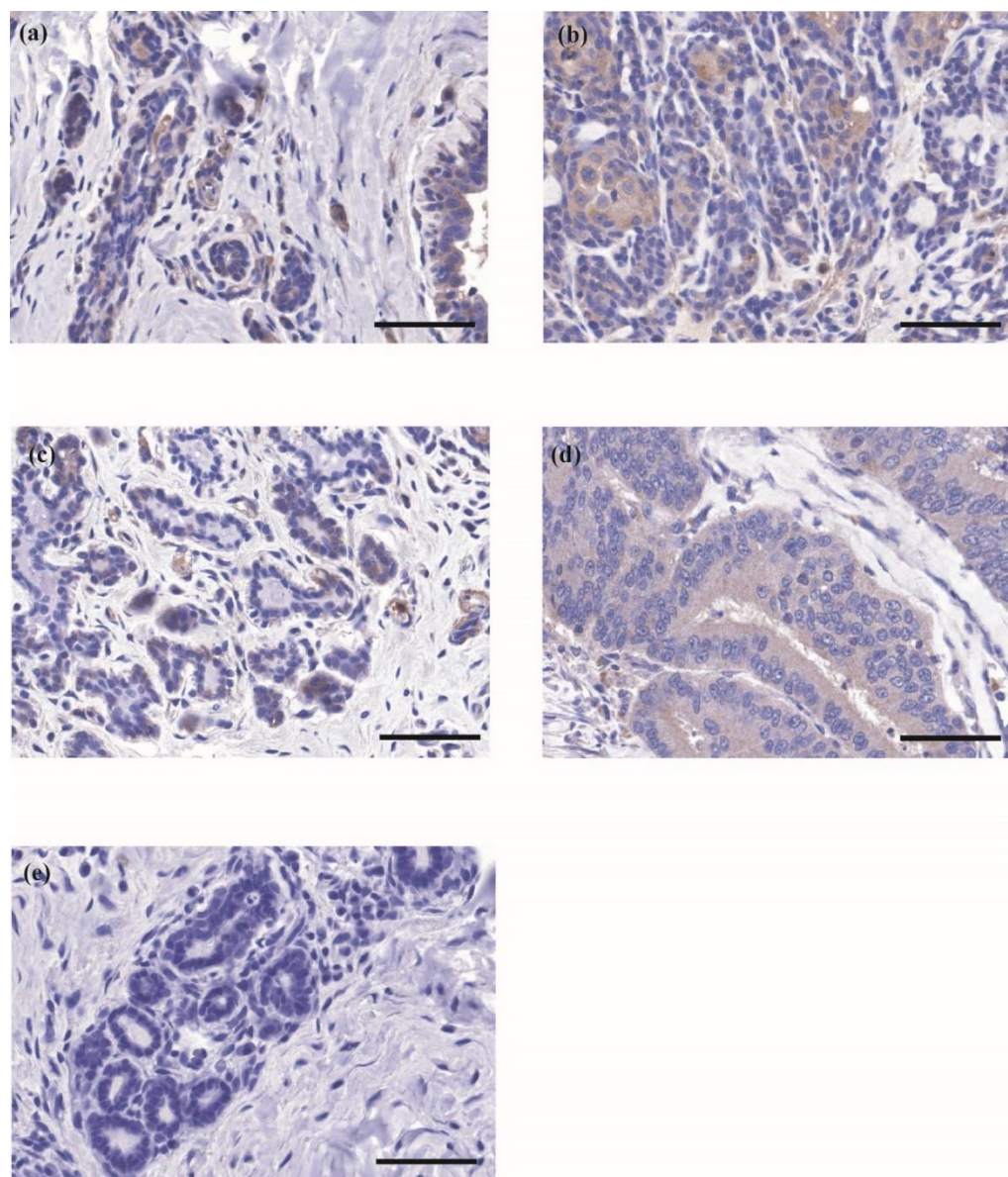


Figure 4 The immunohistochemical staining of PPAR γ in canine mammary tissues. Immunoreactivity of PPAR γ (brown in color) in non-neoplastic mammary tissue (control) (a) compared to benign mammary tumor tissue (b) from the same bitch. In mammary tissues from another bitch, PPAR γ immunoreactivity of non-neoplastic mammary tissue (c) compared to malignant mammary tumor (d). Mammary tissue staining with Mayer's hematoxylin (blue in color) was used as a negative control (e). Microscopic magnification at 40x. Bar =50 μ m.

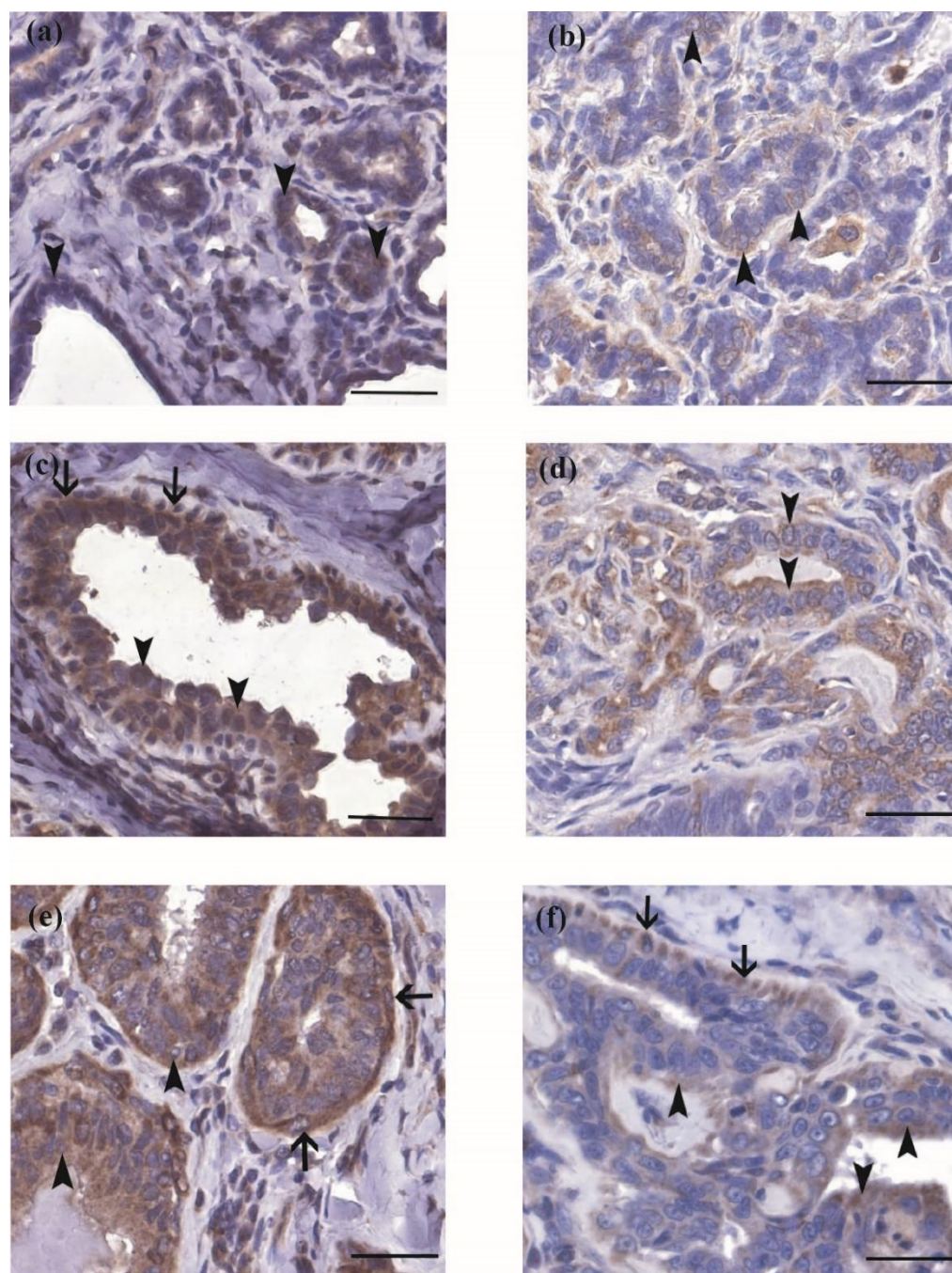


Figure 5 Localization of PPAR α and PPAR γ in non-neoplastic tissue (normal) and neoplastic canine mammary tissue. Expression of PPAR α in non-neoplastic tissue (a) and PPAR γ in non-neoplastic tissue (b). PPAR α in canine mammary tumor (benign type) (c) and PPAR γ in canine mammary tumor (benign type) (d). PPAR α in canine mammary tumor (malignant type) (e) and PPAR γ in canine mammary tumor (malignant type) (f). Both PPAR α and PPAR γ express mainly in cytoplasm and plasma membrane of glandular epithelium and ductal epithelium with lower expression in perinucleolar region and nucleus (arrowhead). Both receptor subtypes also express in cytoplasm and some nuclei of myoepithelial cells (arrow). Microscopic magnification 40x. Bar = 30 μ m.

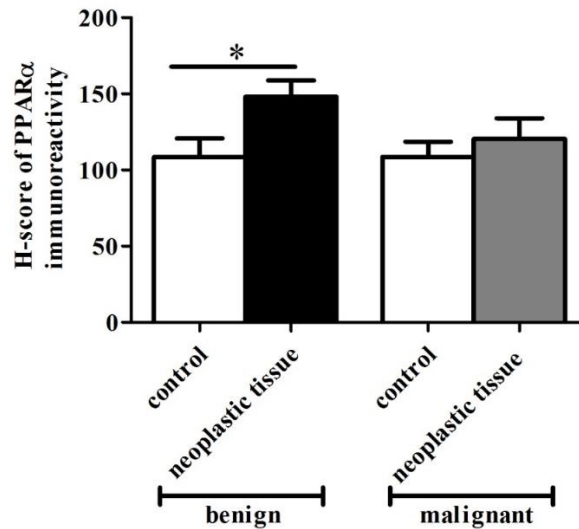
Our study showed that PPAR γ expression in glandular epithelial cells and epithelial lining duct cells of mammary tissue was mild to moderate and localized mainly in the cytoplasm, however, it is also localized in the perinucleolar region and nuclei of some cells. Moreover, PPAR γ expression in malignant canine mammary tissue was higher than in normal tissues, while its expression in benign type did not change compared to normal tissue. For decades, expression of PPAR γ have been demonstrated in severe cancers including colorectal, pancreas, breast, prostate, and salivary duct carcinoma (Mukunyadzi et al., 2003). In

similarity with human salivary duct carcinoma, immunoreactivity was observed in the cytoplasm, but not in the nucleus (Mukunyadzi et al., 2003). A recent study have shown that PPAR γ are diffusely or granular expressed in the cytoplasm and perinucleolar region in some nasal epithelial cells and the positivity of PPAR γ in canine nasal carcinomas tissue was stronger than normal canine nasal epithelium (Paciello et al., 2007). A plausible explanation for the fact that the expression of PPAR γ is high in malignant canine mammary tumor is that the activation of PPAR γ plays roles in growth inhibitory effect and differentiation in cancers as it has

been demonstrated in human prostate cancer cell line (Mueller et al., 2000) and breast cancer by increasing lipid accumulation, altering breast epithelial gene

expression, reducing malignant state, declining in growth rate and clonogenic capacity of the cells (Mueller et al., 1998).

(A)



(B)

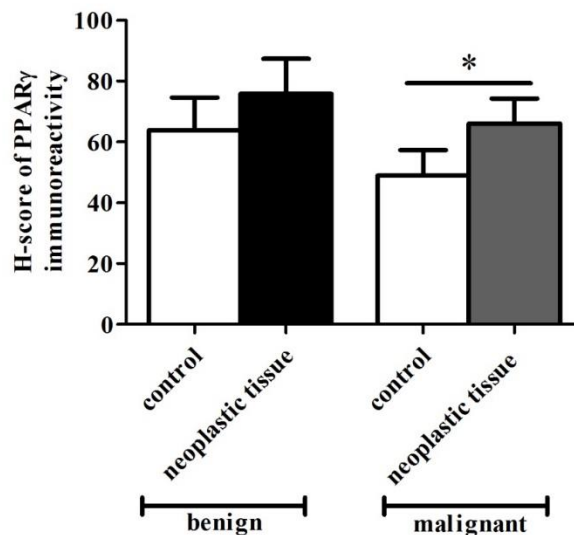


Figure 6 (A) Graph shows H-score of PPARα immunoreactivity of control in comparison with benign mammary tumors (left, n=12) and control in comparison with malignant mammary tumors (right, n=12). (B) Graph shows H-score of PPARγ immunoreactivity of control in comparison with benign mammary tumors (left, n=12) and control in comparison with malignant mammary tumors (right, n=12). *P<0.05

In conclusion, the results of this present study showed the expression of PPARα and PPARγ in normal canine mammary tissue, and the upregulation of these receptors was observed in both benign and malignant mammary gland tumors. These data suggested that both receptor subtypes play an important role in normal mammary tissue function and pathogenesis of canine mammary gland tumor. Additionally, this novel

may provide a new target for canine mammary gland tumor therapeutic treatment in the future.

However, gene and protein expressions by other methods need to be confirmed for future studies.

Acknowledgements

We would like to thank Mrs. Jongkol Sangwiroon, Mr. Silpchai Pienchop, and Mr. Wittoon Mabutr for their help in Immunohistochemistry work.

We also thank the Obstetrics Unit, Chulalongkorn University Small Animal Hospital and Department of Physiology, Faculty of Science, Mahidol University for providing tissue samples. We also would like to give special thanks to the pathologists from the Department of Pathology, Faculty of Veterinary Science, Chulalongkorn University for tumor diagnoses. Lastly, we would like to give deeply gratitude to Chulalongkorn University for supporting us by providing the Grants for Development of New Faculty Staff, Ratchadaphiseksomphot Endowment Fund, Chulalongkorn University.

References

- Apostoli AJ, Skelhorne-Gross GE, Rubino RE, Peterson NT, Di Lena MA, Schneider MM, SenGupta SK and Nicol CJ 2014. Loss of PPARgamma expression in mammary secretory epithelial cells creates a pro-breast tumorigenic environment. *Int J Cancer*. 134(5): 1055-1066.
- Apostoli AJ, Skelhorne-Gross GE, Rubino RE, Peterson NT, Di Lena MA, Schneider MM, SenGupta SK and Nicol CJ 2014. Loss of PPARgamma expression in mammary secretory epithelial cells creates a pro-breast tumorigenic environment. *Int J Cancer*. 134(5): 1055-1066.
- Ban JO, Oh JH, Son SM, Won D, Song HS, Han SB, Moon DC, Kang KW, Song MJ and Hong JT 2011. Troglitazone, a PPAR agonist, inhibits human prostate cancer cell growth through inactivation of NFkappaB via suppression of GSK-3beta expression. *Cancer Biol Ther*. 12(4): 288-296.
- Blanquicett C, Roman J and Hart CM 2008. Thiazolidinediones as anti-cancer agents. *Cancer Ther*. 6(A): 25-34.
- Braissant O, Fougere F, Scotto C, Dauca M and Wahli W 1996. Differential expression of peroxisome proliferator-activated receptors (PPARs): tissue distribution of PPAR-alpha, -beta, and -gamma in the adult rat. *Endocrinology*. 137(1): 354-366.
- Conzen SD 2008. Minireview: nuclear receptors and breast cancer. *Mol Endocrinol*. 22(10): 2215-2228.
- Elstner E, Muller C, Koshizuka K, Williamson EA, Park D, Asou H, Shintaku P, Said JW, Heber D and Koeffler HP 1998. Ligands for peroxisome proliferator-activated receptor gamma and retinoic acid receptor inhibit growth and induce apoptosis of human breast cancer cells in vitro and in BNX mice. *Proc Natl Acad Sci U S A*. 95(15): 8806-8811.
- Gao W, Xu W and Li H 2013. The expression and role of peroxisome proliferator-activated receptor alpha in atherosclerosis. *Mol Med Rep*. 7(3): 862-868.
- Gimble JM, Pighetti GM, Lerner MR, Wu X, Lightfoot SA, Brackett DJ, Darcy K and Hollingsworth AB 1998. Expression of peroxisome proliferator activated receptor mRNA in normal and tumorigenic rodent mammary glands. *Biochem Biophys Res Commun*. 253(3): 813-817.
- Goldschmidt M, Pena L, Rasotto R and Zappulli V 2011. Classification and grading of canine mammary tumors. *Vet Pathol*. 48(1): 117-131.
- Gonzalez FJ and Shah YM 2008. PPARalpha: mechanism of species differences and hepatocarcinogenesis of peroxisome proliferators. *Toxicology*. 246(1): 2-8.
- Jain S, Pulikuri S, Zhu Y, Qi C, Kanwar YS, Yeldandi AV, Rao MS and Reddy JK 1998. Differential expression of the peroxisome proliferator-activated receptor gamma (PPARgamma) and its coactivators steroid receptor coactivator-1 and PPAR-binding protein PBP in the brown fat, urinary bladder, colon, and breast of the mouse. *Am J Pathol*. 153(2): 349-354.
- Lehrke M and Lazar MA 2005. The many faces of PPARgamma. *Cell*. 123(6): 993-999.
- Mahmoud AM, Macias V, Al-Alem U, Deaton RJ, Kadaksy-Balla A, Gann PH and Rauscher GH 2017. BRCA1 protein expression and subcellular localization in primary breast cancer: Automated digital microscopy analysis of tissue microarrays. *PLoS One*. 12(9): e0184385.
- Michalik L, Auwerx J, Berger JP, Chatterjee VK, Glass CK, Gonzalez FJ, Grimaldi PA, Kadowaki T, Lazar MA, O'Rahilly S, Palmer CN, Plutzky J, Reddy JK, Spiegelman BM, Staels B and Wahli W 2006. International Union of Pharmacology. LXI. Peroxisome proliferator-activated receptors. *Pharmacol Rev*. 58(4): 726-741.
- Michel E, Feldmann SK, Kowalewski MP, Bley CR, Boos A, Guscetti F and Reichler IM 2012. Expression of prolactin receptors in normal canine mammary tissue, canine mammary adenomas and mammary adenocarcinomas. *BMC Vet Res*. 8: 72.
- Mueller E, Sarraf P, Tontonoz P, Evans RM, Martin KJ, Zhang M, Fletcher C, Singer S and Spiegelman BM 1998. Terminal differentiation of human breast cancer through PPAR gamma. *Mol Cell*. 1(3): 465-470.
- Mueller E, Smith M, Sarraf P, Kroll T, Aiyer A, Kaufman DS, Oh W, Demetri G, Figg WD, Zhou XP, Eng C, Spiegelman BM and Kantoff PW 2000. Effects of ligand activation of peroxisome proliferator-activated receptor gamma in human prostate cancer. *Proc Natl Acad Sci U S A*. 97(20): 10990-10995.
- Mukunyadzi P, Ai L, Portilla D, Barnes EL and Fan CY 2003. Expression of peroxisome proliferator-activated receptor gamma in salivary duct carcinoma: immunohistochemical analysis of 15 cases. *Mod Pathol*. 16(12): 1218-1223.
- Nagasawa M, Ide T, Suzuki M, Tsunoda M, Akasaka Y, Okazaki T, Mochizuki T and Murakami K 2004. Pharmacological characterization of a human-specific peroxisome proliferator-activated receptor alpha (PPARalpha) agonist in dogs. *Biochem Pharmacol*. 67(11): 2057-2069.
- Nahle Z 2004. PPAR trilogy from metabolism to cancer. *Curr Opin Clin Nutr Metab Care*. 7(4): 397-402.
- Paciello O, Borzacchiello G, Varricchio E and Papparella S 2007. Expression of peroxisome proliferator-activated receptor gamma (PPARgamma) in canine nasal carcinomas. *J Vet Med A Physiol Pathol Clin Med*. 54(8): 406-410.
- Reddy JK and Hashimoto T 2001. Peroxisomal beta-oxidation and peroxisome proliferator-activated

- receptor alpha: an adaptive metabolic system. *Annu Rev Nutr.* 21: 193-230.
- Reddy JK and Rao MS 1989. Oxidative DNA damage caused by persistent peroxisome proliferation: its role in hepatocarcinogenesis. *Mutat Res.* 214(1): 63-68.
- Roberts-Thomson SJ and Snyderwine EG 2000. Characterization of peroxisome proliferator-activated receptor alpha in normal rat mammary gland and 2-amino-1-methyl-6-phenylimidazo[4,5-b]pyridine-induced mammary gland tumors from rats fed high and low fat diets. *Toxicol Lett.* 118(1-2): 79-86.
- Rusyn I, Rose ML, Bojes HK and Thurman RG 2000. Novel role of oxidants in the molecular mechanism of action of peroxisome proliferators. *Antioxid Redox Signal.* 2(3): 607-621.
- Schmeel LC, Schmeel FC and Schmidt-Wolf IGH 2017. In Vitro Apoptosis Induction by Fenofibrate in Lymphoma and Multiple Myeloma. *Anticancer Res.* 37(7): 3513-3520.
- Shibuya A, Wada K, Nakajima A, Saeki M, Katayama K, Mayumi T, Kadowaki T, Niwa H and Kamisaki Y 2002. Nitration of PPARgamma inhibits ligand-dependent translocation into the nucleus in a macrophage-like cell line, RAW 264. *FEBS Lett.* 525(1-3): 43-47.
- Sozmen M, Kabak YB, Gulbahar MY, Gacar A, Karayigit MO, Guvenc T and Yarim M 2013. Immunohistochemical characterization of peroxisome proliferator-activated receptors in canine normal testis and testicular tumours. *J Comp Pathol.* 149(1): 10-18.
- Suchanek KM, May FJ, Robinson JA, Lee WJ, Holman NA, Monteith GR and Roberts-Thomson SJ 2002. Peroxisome proliferator-activated receptor alpha in the human breast cancer cell lines MCF-7 and MDA-MB-231. *Mol Carcinog.* 34(4): 165-171.
- Tontonoz P and Spiegelman BM 2008. Fat and beyond: the diverse biology of PPARgamma. *Annu Rev Biochem.* 77: 289-312.
- Wang YX, Lee CH, Tiep S, Yu RT, Ham J, Kang H and Evans RM 2003. Peroxisome-proliferator-activated receptor delta activates fat metabolism to prevent obesity. *Cell.* 113(2): 159-170.
- Warden A, Truitt J, Merriman M, Ponomareva O, Jameson K, Ferguson LB, Mayfield RD and Harris RA 2016. Localization of PPAR isotypes in the adult mouse and human brain. *Sci Rep.* 6: 27618.
- Wilk A, Urbanska K, Grabacka M, Mullinax J, Marcinkiewicz C, Impastato D, Estrada JJ and Reiss K 2012. Fenofibrate-induced nuclear translocation of FoxO3A triggers Bim-mediated apoptosis in glioblastoma cells in vitro. *Cell Cycle.* 11(14): 2660-2671.
- Yang Q, Kurotani R, Yamada A, Kimura S and Gonzalez FJ 2006. Peroxisome proliferator-activated receptor alpha activation during pregnancy severely impairs mammary lobuloalveolar development in mice. *Endocrinology.* 147(10): 4772-4780.
- Youssef J and Badr M 2011. Peroxisome proliferator-activated receptors and cancer: challenges and opportunities. *Br J Pharmacol.* 164(1): 68-82.

บทคัดย่อ

การยับยั้งอนุมูลอิสระของ peroxisome proliferator activated receptor อัลฟ่า และ แกมมา ในเนื้อเยื่อเต้านมสุนัขที่ปกติ เนื้องอกเต้านมสุนัขชนิดไม่ร้ายแรงและชนิดร้ายแรง

วุฒิชัย กลมเกลียว¹ พรหมพร รักษาเสรี^{1*}

peroxisome proliferator activated receptors (PPARs) เป็นนิวเคลียร์รีเซพเตอร์ชนิดหนึ่งซึ่งทำหน้าที่เป็น transcription factor ที่ควบคุมเมตาบอลิซึมของไขมันและน้ำตาล มีด้วยกัน 3 subtypes ได้แก่ PPAR α , PPAR γ , และ PPAR δ การกระตุ้น PPAR α และ PPAR γ ถูกค้นพบว่าสามารถทำให้เกิดการยับยั้งการแบ่งตัวและการเปลี่ยนแปลงของเนื้องอกได้ อย่างไรก็ตามยังไม่มีข้อมูลการแสดงออกของรีเซพเตอร์เหล่านี้ในเนื้อเยื่อเต้านมสุนัข ในการทดลองนี้จึงได้ศึกษาเปรียบเทียบการแสดงออกของ PPAR α และ PPAR γ ในเนื้อเยื่อเต้านมของสุนัขทั้งส่วนที่เป็นปกติ ส่วนที่เป็นเนื้องอกชนิดไม่ร้ายแรง และชนิดร้ายแรง สุนัขเพศเมียจำนวน 24 ตัวอายุระหว่าง 5 ถึง 15 ปี ที่ถูกวินิจฉัยว่าเป็นเนื้องอกเต้านมถูกนำมาใช้ในการทดลองนี้ ในแต่ละตัวจะตัดเนื้อเยื่อเต้านมส่วนที่เป็นปกติและส่วนที่เป็นเนื้องอกมาย้อมด้วย H&E เพื่อแยกแยะชนิดของเนื้องอก พบว่าเป็นชนิดไม่ร้ายแรง จำนวน 12 ตัวและเป็นชนิดร้ายแรงจำนวน 12 ตัว เมื่อนำเนื้อเยื่อมาย้อมด้วยวิธีอิมมูโนฮิสโตเคมี พบว่า PPARs ทั้งสองชนิด มีการแสดงออกในไซโตพลาสซึม รอบนิวเคลียส และในบางนิวเคลียสของ glandular epithelial cells ductal epithelial cells และ myoepithelial cells นอกจากนี้ยังพบการแสดงออกของโปรตีนทั้งสองชนิดนี้ในปริมาณเล็กน้อยใน fibroblast macrophage เซลล์เยื่อและเซลล์กล้ามเนื้อเรียบของหลอดเลือด cytoplasmic immunoreactivity ของรีเซพเตอร์ถูกนำมาคำนวณเป็นค่า H-score พบว่า H-score ของ PPAR α ในเนื้องอกชนิดไม่ร้ายแรงและ PPAR γ ในเนื้องอกชนิดร้ายแรงมีค่ามากกว่าเนื้อเยื่อเต้านมปกติอย่างมีนัยสำคัญ ($P < 0.05$) เนื่องจากมีการแสดงออกของรีเซพเตอร์ทั้งสองชนิดนี้ในเนื้อเยื่อเต้านมปกติและมีการเพิ่มจำนวนของรีเซพเตอร์มากขึ้นในเนื้องอกเต้านม แสดงให้เห็นว่า PPAR α และ PPAR γ นั้นน่าจะมีส่วนสำคัญในการทำงานของเต้านมในภาวะปกติและอาจเกี่ยวข้องกับกลไกการเกิดเนื้องอกเต้านมในสุนัข

คำสำคัญ: สุนัข ต่อมเต้านม เนื้องอก PPAR α PPAR γ

¹ภาควิชากายวิภาคศาสตร์ คณะสัตวแพทยศาสตร์ จุฬาลงกรณ์มหาวิทยาลัย ปทุมวัน กรุงเทพฯ 10330

*ผู้รับผิดชอบบทความ E-mail: Promporn.R@chula.ac.th