

## Ophthalmology Snapshot

Nalinee Tuntivanich

### History

Jelly, a 2 year-old mixed breed cat, was referred to the Small Animal Hospital Teaching Hospital, Faculty of Veterinary medicine, Chulalongkorn University. Her left eye had been unresponsive to treatment of ulcerative keratitis provided by her veterinarian. Epiphora as well as ocular discomfort had been noted.

Ophthalmic examinations on the first visit revealed inflammation of the uvea. The IOP was 57 mmHg. Lens was anteriorly displaced and the left globe was enlarged. Retinal detachment and hemorrhage were noticed. Right eye was ophthalmically normal.

Two weeks after treatment, the IOP was within normal limit. Fluorescein staining was positive (Figure 1).

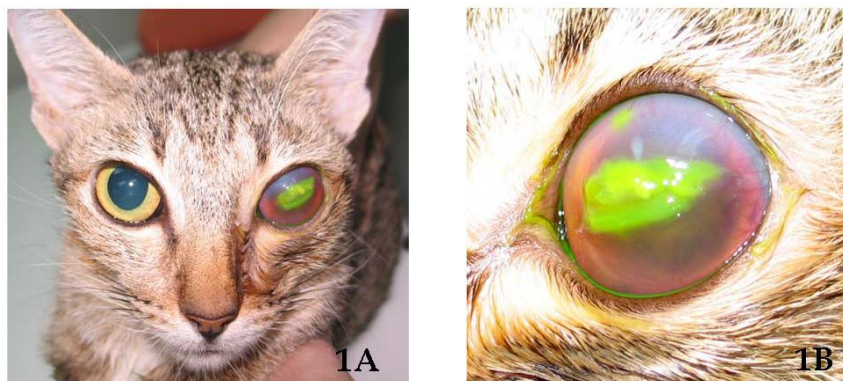

Figure 1. Photograph of Jelly; (A) comparing both eyes and; (B) demonstrating positive fluorescein staining on the cornea and uveitis. (For better quality, figures can be viewed at [www.vet.chula.ac.th/~tjvm](http://www.vet.chula.ac.th/~tjvm))

### Further information

Part of complete blood count (CBC) test: RBC =  $3 \times 10^6 / \mu\text{L}$ , Hb = 7 g/dL, Hct = 28%, Platelet =  $95,000 / \text{mm}^3$

### Questions

1. Give the cause of positive fluorescein staining at central cornea?
2. Give your tentative diagnosis and associated underlying cause

Please turn to the next page for answers .....

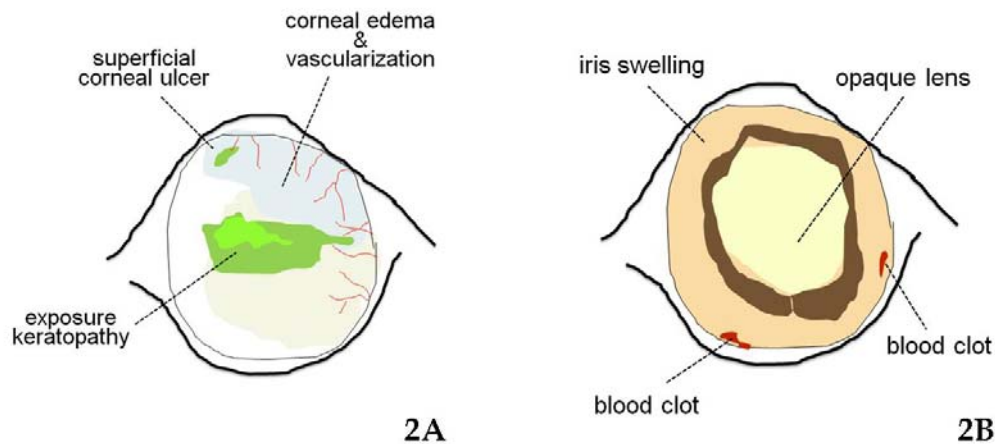


Figure 2. Photograph of; (A) the ocular surface and; (B) anterior portion of the left eye.

### Answers

1. Exposure keratopathy secondary to incomplete eyelid closure
2. Secondary glaucoma induced by vascular disorder

### Comments

Vascular disorder is one of a well established systemic diseases in cat associated with several abnormalities including anemia. Supply of oxygen to vascular endothelium in anemic cat is reduced, therefore resulting in a breakdown of endothelial vasculature that causes secondary leakage of capillaries mainly in uvea and retina. Blood pressure should in addition be assessed because anemia can be correlated with systemic hypertension. Retinal detachment and hemorrhage seen at the first visit may perhaps be part of anemic and/or hypertensive retinopathy. Other causes of feline anemia such as *Mycoplasma haemofelis* infection, thrombocytopenia, autoimmune hemolytic anemia, etc should not be

overlooked.

Systemic disorder can easily be diagnosed by ophthalmic examination in conjunction with physical examination to preserve not only vision but life. The common ocular manifestation of systemic disease is uveitis, a leading cause of secondary glaucoma. Chronic stage of glaucoma is characterized by buphthalmos, anterior (cataractous) lens luxation and exposure keratopathy. Treatment of keratitis should be given concurrently with rapid reduction of the IOP.

### References

- Dietrich, U. 2005. Feline glaucomas. Clin. Tech. Small Anim. Pract. 20(2): 108-116.
- La Croix, N.C. 2005. Ocular manifestations of systemic disease in cats. Clin. Tech. Small Anim. Pract. 20: 121-128.
- Blocker, T. and van der Woerd, A. 2001. The feline glaucomas: 82 cases (1995-1999). Vet. Ophthalmol. 4(2): 81-85.