

Avian Polyomavirus Infection in Non-Budgerigar Psittacine Birds in Thailand - A case report

Thanongsak Mamom^{1*} Prasit Dumrongsoonthornchai² Ladda Trongwongsa³

Abstract

One sick 4-week-old Eclectus (*Eclectus roratus*) and two carcasses of 3-week-old Macaws (*Ara macao*) from a bird farm near Bangkok were submitted in July 2009 for investigation. Necropsy revealed multifocal hemorrhages at subcutaneous tissue, heart, liver and bursa of Fabricius. The most prominent findings were hepatomegaly and splenomegaly. Histopathologic examination showed severe splenic necrosis with presence of homogeneous pale basophilic intranuclear inclusion body in splenic periarteriolar sheath cells. The liver showed severe necrosis with occasionally intranuclear inclusion body in sinusoid-lining cells. Intranuclear inclusion bodies were detected in mesangial cells, epithelium of collecting tubules and papillary ducts of kidney and mesenchymal cells of lung and heart. TEM examination revealed tremendous 45 nm icosahedral non-enveloped capsids consistent with virions of polyomavirus in intranuclear inclusion body containing cells in kidney and lung. The diagnosis of avian polyomavirus (APV) infection was made based on histopathologic and electron microscopic results. Avian polyomavirus cause severe disease in a wide range of psittacine and non-psittacine birds. It occurs most frequently in budgerigars, macaws, conures, Eclectus parrots, Ringneck parrots and lovebirds. The disease is more severe in nestlings as also observed in this study. In this report, we document the macroscopic and microscopic findings including TEM feature of a recent case of APV infection in non-budgerigar psittacine birds from a bird farm near Bangkok, Thailand. This report may remind avian veterinarians and breeding aviary farmers about the occurrence of APV infection in this country and make them be aware of the possible outbreak of APV in the future.

Keywords: avian, electron microscopy, histopathology, polyomavirus, psittacine

¹ Department of Pathology, Faculty of Veterinary Medicine, Mahanakorn University of Technology, Bangkok, 10530 Thailand

² Clinic for Poultry, Faculty of Veterinary Medicine, Mahanakorn University of Technology, Bangkok, 10530 Thailand

³ Pathology Section, National Institute of Animal Health (NIAH), Bangkok, Thailand

Corresponding author E-mail: thanonsa@mut.ac.th

บทคัดย่อ

โรคติดเชื้อเอเวียนโปลิโอมาไวรัสในนกปากขอที่ไม่ใช่หงษ์หยกในประเทศไทย:

รายงานสัตว์ป่วย

ทนงค์ศักดิ์ มะม่ม^{1*} ประสิทธิ์ ดำรงสุนทรชัย² ลัดดา ตรงวงศ์³

นกแก้วอีเล็คตัส (*Eclectus roratus*) อายุ 4 สัปดาห์ จำนวน 1 ตัว และ ชากนกแก้วมาคอว์ (*Ara macao*) อายุ 3 สัปดาห์ จำนวน 2 ตัว จากฟาร์มนกใกล้กรุงเทพฯ ถูกส่งมายังห้องปฏิบัติการชันสูตรซาก ในช่วงเดือนกรกฎาคม ปี พ.ศ. 2552 เพื่อการตรวจวินิจฉัย ผลการชันสูตรซากพบจุดเลือดออกกระจายหลายจุดที่ได้ผิวหนัง หัวใจ ตับ และ ต่อมเบอริชา รอยโรคเด่นชัดที่สุด คือ ตับโตและม้ามโต ผลทางจุลพยาธิวิทยา พบเนื้อตายรุนแรงบริเวณเนื้อเยื่อรอบหลอดเลือดในม้ามและพบอินคลูชันบอดีตึตึสีฟ้าจางอยู่ภายในนิวเคลียส ตับพบเนื้อตายและพบอินคลูชันบอดีตึตึในนิวเคลียสของเซลล์บุช่องเลือดในตับ ก้อนอินคลูชันบอดีตึลักษณะดังกล่าวยังสามารถพบได้ที่ Mesangial cells ของโกลเมอรูลัสหลายแห่ง ที่เซลล์บุผิวท่อรวมปัสสาวะในไต รวมถึงใน Mesenchymal cells ในปอดและหัวใจด้วย ผลการตรวจด้วยกล้องจุลทรรศน์อิเล็กตรอนชนิดลำแสงส่องผ่าน พบไวรัส ไม่มีเปลือกหุ้ม รูปร่างเป็นแบบ Icosahedral ขนาดประมาณ 45 นาโนเมตร คล้ายโปลิโอมาไวรัส อยู่ในก้อนอินคลูชันบอดีตึ จากผลทางจุลพยาธิวิทยาและทางกล้องจุลทรรศน์อิเล็กตรอน สรุปได้ว่าเกิดโรคติดเชื้อ เอเวียนโปลิโอมาไวรัส (เอพีวี) เชื้อเอพีวีก่อโรครุนแรงในนกหงษ์หยก มาคอว์ คอנוร์ อีเล็คตัส นกแก้ว นกแก้วคอแหวน และ นกสวยงามอื่นๆ โดยโรคจะรุนแรงในลูกนกเช่นเดียวกับที่พบในการศึกษานี้ ในรายงานนี้ได้นำเสนอลักษณะทางมหพยาธิวิทยา จุลพยาธิวิทยาและ ลักษณะทางกล้องจุลทรรศน์อิเล็กตรอน ที่พบในนกปากขอจากฟาร์มนกใกล้กรุงเทพฯ ที่ติดเชื้อเอเวียนโปลิโอมาไวรัส รายงานนี้อาจช่วยให้สัตวแพทย์ผู้ดูแลนกและเจ้าของฟาร์มพ่อแม่พันธุ์นกตระหนักถึงอุบัติการณ์ของโรคนี้และต้นตอในการรับมือกับการระบาดที่อาจเกิดขึ้นอีกในอนาคต

คำสำคัญ: สัตว์ปีก กล้องจุลทรรศน์อิเล็กตรอน จุลพยาธิวิทยา โปลิโอมาไวรัส นกปากขอ

¹สาขาวิชาพยาธิวิทยา คณะสัตวแพทยศาสตร์ มหาวิทยาลัยเทคโนโลยีมหานคร หนองจอก กรุงเทพฯ 10530

²สาขาวิชาคลินิกสำหรับสัตว์ปีก คณะสัตวแพทยศาสตร์ มหาวิทยาลัยเทคโนโลยีมหานคร หนองจอก กรุงเทพฯ 10530

³กลุ่มงานพยาธิวิทยา สถาบันสุขภาพสัตว์แห่งชาติ จตุจักร กรุงเทพฯ

*ผู้รับผิดชอบบทความ E-mail: thanonsa@mut.ac.th

Introduction

Avian polyomavirus (APV) was first known as pathogen in young budgerigars (*Melopsittacus undulatus*) in the early 1980s (Davis et al., 1981) and was recognized as the causative agent of the budgerigar fledgling disease (BFD) at that time. The virus causes severe disease in a wide range of psittacine and non-psittacine birds. APV has been recognized in a variety of avian species like non-budgerian psittaciformes, falconiformes, domestic geese as well as finches and gallinaceous birds. The infection is mostly severe and fatal in young birds (Bernier et al., 1981; Pass et al., 1987; Rahaus and Wolff, 2005). In fledgling budgerigars, mortality rate may reach 100% (Krautwald et al., 1989). Clinical signs observed in acute infections are polyuria, subcutaneous hemorrhages, dyspnoea and depression (Graham and Calnek, 1987; Stoll et al., 1993). APV has been placed into the distinct subgenus Avipolyomavirus. The non-enveloped capsids of APV virions are icosahedral shape and about 45-50 nm in size (Bozeman et al., 1981; Pass et al., 1987). The

genome is a circular and double-stranded DNA of 4981 bp in length, which is fully sequenced and molecular characterization of isolated APV based on the whole genome sequence analysis were documented (Katoh et al., 2009; Rott et al., 1988). An outbreak of APV infection in Thailand was reported in 2005 and the diagnosis was confirmed by PCR (Banlunara et al., 2005). Predominant macroscopic lesions were hepatomegaly with focal hemorrhage, splenomegaly, hydropericardium, hydroperitoneum and patchy hemorrhage in the subcutaneous tissue. Histopathology showed hepatic necrosis with karyomegalic fine granular basophilic intranuclear inclusion bodies in hepatocytes, Kupffer's cells, cells in perivascular sheath of spleen, in lamina propria of intestines, glomerular mesangial cells, renal tubular cells and feather follicular cells (Banlunara et al., 2005).

The aim of this study is to present gross, microscopic and ultrastructural features of a recent case of APV infection in non-budgerigar psittacine birds in Thailand.

Materials and Methods

Case history: One sick 4-week-old Eclectus (*Eclectus roratus*) and two carcasses of 3-week-old Macaws (*Ara macao*) from a bird farm near Bangkok were submitted in July 2009 to Mahanakorn Veterinary Diagnostic Center (MVDC) for investigation. The animals showed history of severe and acute onset of illness and were found dead. Necropsy was performed on the two carcasses and tissue samples were fixed in 10% buffered formalin. The tissue samples from three birds were sent to histopathology laboratory for slide preparation using conventional method. Briefly, the tissues were processed and embedded in paraffin, sectioned at 4 microns and stained with hematoxylin and eosin (H&E). All slides were examined under light microscope (Axiolab, Zeiss, Germany). Some pieces of organ including kidney, liver and lung were re-collected from achieve formalin fixed material for further transmission electron microscopic (TEM) study at Pathology Section, the National Institute of Animal Health (NIAH). Briefly, the tissue samples were post-fixed in 1% osmium tetroxide and embedded in epoxy resin (Epon). Semithin sections were cut at 0.5 micron and stained with 2% toluidine blue. The sections were examined under light microscope to locate specific areas for ultrathin sections. The ultrathin sections were cut and stained with 5% uranyl acetate and lead citrate. The samples were examined under transmission electron microscope (JEM-1200EX, JEOL, Japan).

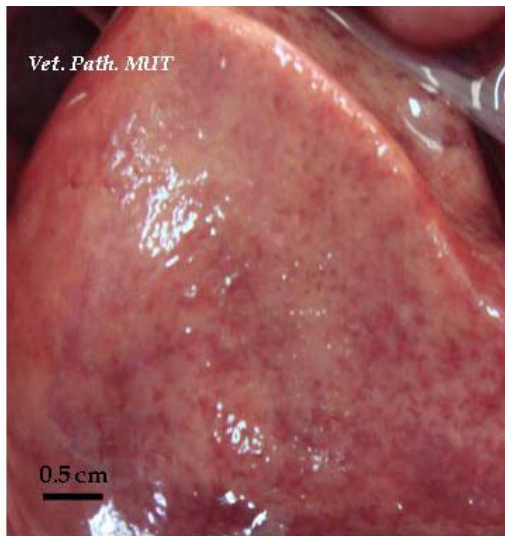


Figure 1. Hepatomegaly with multiple ecchymotic hemorrhages at liver surface.

Results and Discussion

Necropsy result: The carcass examination revealed multifocal patchy hemorrhages at subcutaneous tissue. The most prominent gross pathological findings were hepatomegaly (Figure 1) and splenomegaly with multiple white foci. Multifocal ecchymotic hemorrhages were detected at epicardium of heart (Figure 2), liver and bursa of Fabricius. The kidneys were pale and the lungs were congested and edematous. Other organs showed non remarkable macroscopic finding.

Histopathological result: The most pronounce microscopic findings were found in spleen and liver. Splenic lesions composed of red pulp congestion and severe periarteriolar sheath necrosis. Karyomegaly, margination of nuclear chromatin and homogeneous pale basophilic intranuclear inclusion body were observed in many splenic periarteriolar sheath cells (Figures 3 & 4). Homogeneous pale basophilic intranuclear inclusion bodies were commonly detected in glomerular mesangial cells (Figure 5), epithelium of collecting tubules and papillary ducts of the kidney and mesenchymal cells of lung and heart (Figures 6a & 6b). The liver showed severe congestion with multifocal randomly hepatic necrosis and hemorrhages. Occasionally, homogeneous pale basophilic intranuclear inclusion body was found in sinusoid-lining cells (Figure 7). Bursa of Fabricius showed markedly medullary lymphoid necrosis without detectable cytoplasmic and nuclear inclusion bodies. Other organs showed non-remarkable microscopic lesion.

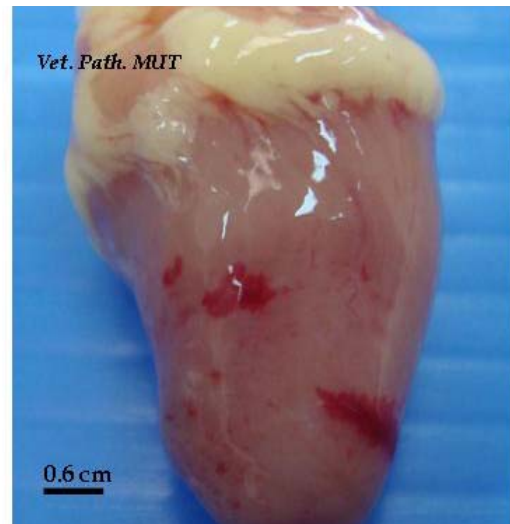


Figure 2. Heart showing petechial and ecchymotic hemorrhages at epicardium.

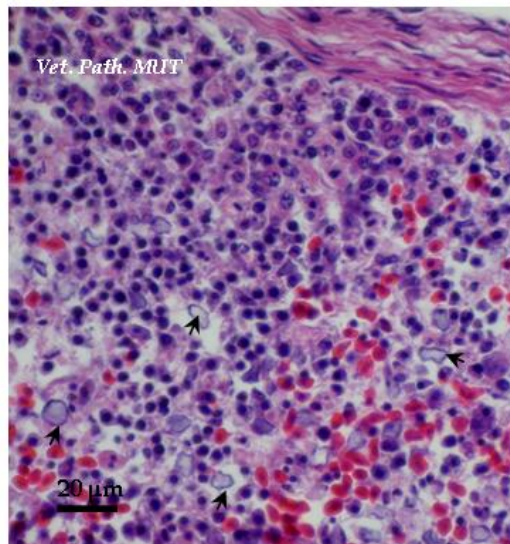


Figure 3. Spleen showing necrosis at periarteriolar sheath with presence of basophilic intranuclear inclusion bodies (black arrows)

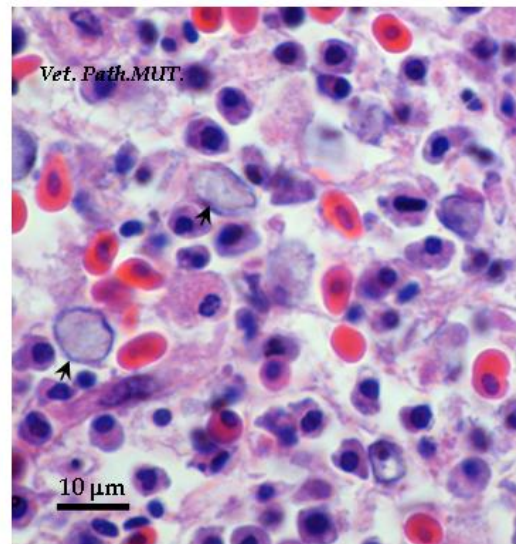


Figure 4. Higher magnification of spleen from figure 3, pale homogenous basophilic intranuclear inclusion bodies found in karyomegalic nuclei (black arrows) of periarteriolar sheath cells of spleen

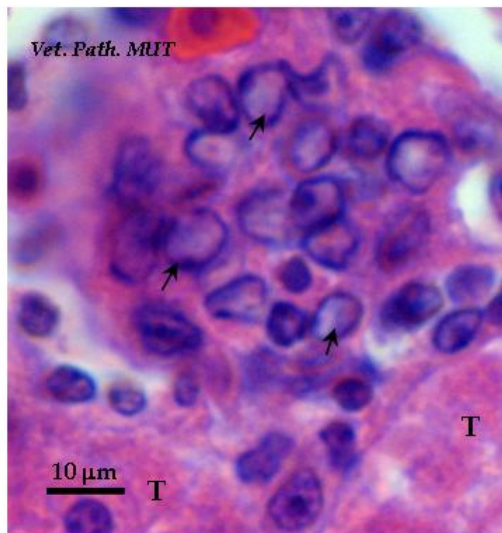


Figure 5. Basophilic intranuclear inclusion bodies seen in karyomegalic nuclei of mesangial cells (black arrows) within renal glomeruli, T: renal tubule

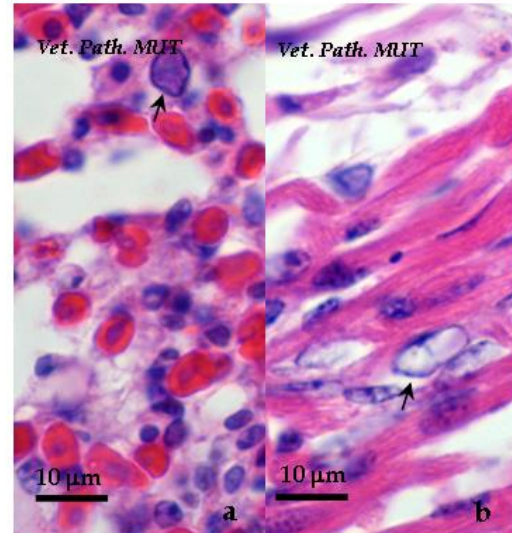


Figure 6a-6b. Intranuclear inclusion bodies in karyomegalic nuclei (black arrows) in lung and heart

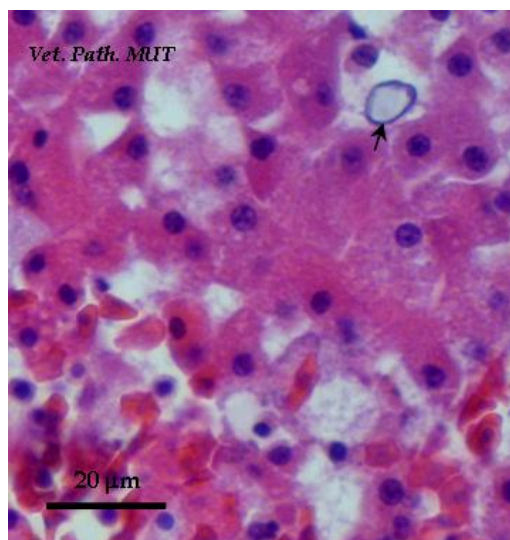


Figure 7. Focal hemorrhage in liver with presence of intranuclear inclusion body in nucleus (black arrow) of sinusoidal lining cell

Transmission electron microscopic (TEM) result: On semithin sections of kidney, liver and lung, intranuclear inclusion bodies could be observed as previously mentioned in histopathological findings. Within the affected nuclei, karyomegaly with margination of nuclear chromatin were found. Tremendous 45 nm icosahedral, non-enveloped capsids consistent with virions of polyomavirus were detected in intranuclear inclusion body containing cells in kidney and lung (Figure 8). In the kidney, some virions of polyomavirus were also recognized in cytoplasm of collecting duct epithelium. There was no virion of polyomavirus observed in inclusion body containing cells in liver in this study. Based on shape

and size of virions and host range of the virus, it was classified to avian polyomavirus (APV) which belong to family Papovaviridae and genus Polyomavirus.

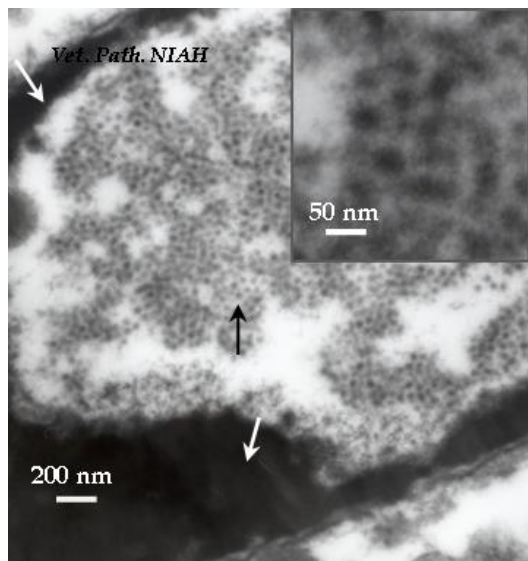


Figure 8. TEM picture of mesenchymal cell in lung showing tremendous icosahedral non-enveloped capsids consistent with virions of polyomavirus (black arrow and in set) within the nucleus, white arrows demonstrate margination of nuclear chromatin.

Morphological diagnosis: Avian polyomavirus (APV) infection was diagnosed based on histopathology and electron microscopy.

Discussion: Avian polyomavirus infection occurs most frequently in budgerigars, macaws, conures, Eclectus parrots, Ringneck parrots and lovebirds. The disease is more severe in nestlings. In this study, the affected birds were macaws and Eclectus parrot and all of them were nestlings. All three non-budgerigar psittacine birds died rapidly and the most prominent external findings were subcutaneous hemorrhages and edema as reported by many authors (Banlunara et al., 2005; Bernier et al., 1981; Davies, 2000; Garcia et al., 1993; Pass et al., 1987). Petechial and ecchymotic hemorrhages are also the hallmark of many cases of acute death from APV as also observed in this study. Presumptive diagnosis of APV infection can be based on history, clinical findings, and characteristic gross and histopathologic lesions (Raidal, 1995). The presence of karyomegaly with margination of nuclear chromatin and homogenous pale basophilic intranuclear inclusion bodies are pathognomonic lesions of APV infection (Bernier et al., 1981; Pass et al., 1987). In this study, intranuclear inclusion bodies were most frequently found at periarteriolar sheath cells of spleen and glomerular mesangial cells of kidney as also found in budgerigars in Thailand previously reported (Banlunara et al., 2005). In the literatures, inclusion bodies were observed in both epithelial and mesenchymal cells (Pass et al., 1987; Garcia et al., 1993). TEM is used to confirm the presence of polyomavirus virions within the nuclear inclusion body. Polyomavirus virions were detected both in the nucleus and cytoplasm of collecting duct epithelial cells in kidney and in the nucleus of mesenchymal cells of lung. The presence of virions of

polyomavirus in cytoplasm of collecting duct epithelial cells is compatible with the study of Pass and colleagues (1987). The exact origin of some inclusion body containing cells was difficult to identify both histopathologically and electron microscopically as also mentioned by same authors. This may due to small amount of cytoplasm of affected cells and alteration of cell morphology from the viral infection. However, the cell position within the affected tissue could give some hints of suggestion about cell origin. Diagnoses of chronic or subclinical cases require molecular technique. Although DNA *in situ* hybridisation (Garcia et al., 1994; Latimer et al., 1994; Ramis et al., 1994) and polymerase chain reaction (PCR) technique (Banlunara et al., 2005; Hsu et al., 2006; Roy et al., 2004; Tomasek et al., 2008) had recently become the most common and standard methods to confirm APV infection, a conventional tool such as TEM examination is still be useful for diagnostic confirmation especially in laboratories where TEM is available and routinely performed.

In this study, we document the macroscopic and microscopic findings including TEM feature of a recent case of avian polyomavirus infection in non-budgerigar psittacine birds from a bird farm near Bangkok, Thailand. This report may remind avian veterinarians and breeding aviary farmers about the occurrence of APV infection in this country and make them be aware of the possible outbreak of APV in the future.

Acknowledgements

The author thanks Mahanakorn University of Technology (MUT) for financial support. Special thanks were given to Dr. Masanori Kubo, NIAH-Japan for TEM consultation, Dr. Sontana, Dr. Jetsada and Ms. Somchit, NIAH-Thailand for a very nice cooperative and support for TEM study. Many thanks were also given to Dr. Suvarin and Ms. Siriwan, staff of Mahanakorn Veterinary Diagnostic Center (MVDC), for all technical supports.

References

- Banlunara, W., Tantilertcharoen, R. and Lekdumrongsak, T. 2005. The detection of avian polyomavirus in psittaciforme birds by using polymerase chain reaction. Proc. of the 4th Chulalongkorn University Veterinary Annual Conference. Thai J. Vet. Med. 35(1): 68.
- Bernier, G., Morin, M. and Marsolais, G. 1981. A generalized inclusion body disease in the budgerigar (*Melopsittacus undulatus*) caused by a papovavirus-like agent. Avian Dis. 25: 1083-1092.
- Bozeman, L.H., Davis, R.B., Gaudry, D., Lukert, P.D., Fletcher, O.J. and Dykstra, M.J. 1981. Characterization of a papovavirus isolated from fledgling budgerigars. Avian Dis. 25: 972-980.
- Davies, R.R. 2000. Avian Liver Disease: Etiology and Pathogenesis. Seminar in Avian and Exotic Pet Medicine. 9(3): 115-125.
- Davis, R.B., Bozeman, L.H., Gaudry, D., Fletcher, O.J., Lukert, P.D. and Dykstra, M.J. 1981. A viral

- disease of fledgling budgerigars. *Avian Dis.* 25: 179-183.
- Garcia, A.P., Latimer, K.S., Niagro, F.D., Norton, T.M., Hamon, B.G., Campagnoli, R.P. and Steffens III, W.L. 1993. Avian Polyomavirus infection in three black-bellied seed crackers (*Pyrenestes ostrinus*). *J. Assoc. Avian Vet.* 7(2): 79-82.
- Garcia, A., Latimer, K.S., Niagro, F.D., Ritchie, B.W. and Campagnoli, R.P., 1994. Diagnosis of polyomavirus-induced hepatic necrosis in psittacine birds using DNA probes. *J. Vet. Diagn. Invest.* 6: 308-314.
- Graham, D.L. and Calnek, B.W. 1987. Papovavirus infection in hand-fed parrots: virus isolation and pathology. *Avian Dis.* 31: 398-410.
- Hsu, C.M., Ko, C.Y. and Tsaia, H.J. 2006. Detection and sequence analysis of avian polyomavirus and psittacine beak and feather disease virus from psittacine birds in Taiwan. *Avian Dis.* 50(3): 348-352.
- Katoh, H., Ohya, K., Une, Y., Yamaguchi, T. and Fukushi, H. 2009. Molecular characterization of avian polyomavirus isolated from psittacine birds based on the whole genome sequence analysis. *Vet. Microbiol.* 138: 69-77.
- Krautwald, M.E., Mueller, H. and Kaleta, E.F. 1989. Polyomavirus infection in budgerigars (*Melopsittacus undulatus*): clinical and aetiological studies. *Zentralbl. Veterinarmed. B.* 36: 459-467.
- Latimer, K.S., Niagro, F.D., Steffens, W.L., Ritchie, B.W. and Campagnoli, R.P. 1996. Polyomavirus encephalopathy in a Ducorps' cockatoo (*Cacatua ducorpsii*) with psittacine beak and feather disease. *J. Vet. Diagn. Invest.* 8(3): 291-295.
- Pass, D.A., Prus, S.E. and Riddell, C. 1987. A Papova-Like Virus Infection of Splendid Parakeets (*Neophema splendida*). *Avian Dis.* 31: 680-684.
- Rahaus, M. and Wolff, M.H. 2005. A survey to detect subclinical polyomavirus infections of captive psittacine birds in Germany. *Vet. Microbiol.* 105: 73-76.
- Raidal, S.R. 1995. Viral Skin Diseases of Birds. Seminar in Avian and Exotic Pet Medicine. 4(2): 72-82.
- Ramis, A., Latimer, K.S., Niagro, F.D., Campagnoli, R.P., Ritchie, B.W. and Pesti, D. 1994. Diagnosis of psittacine beak and feather disease (PBFD) viral infection, avian polyomavirus infection, adenovirus infection and herpesvirus infection in psittacine tissue using DNA *in situ* hybridization. *Avian Pathol.* 23(4): 643-657.
- Rott, O., Kroger, M., Mueller, H. and Hobom, G. 1988. The genome of budgerigar fledgling disease virus, an avian polyomavirus. *Virology.* 165: 74-86.
- Roy, P., Dhillon, A.S., Lauerman, L. and Shivaprasad, H.L. 2004. Detection of avian polyomavirus infection by polymerase chain reaction using formalin-fixed, paraffin-embedded tissues. *Avian Dis.* 48(2): 400-404.
- Stoll, R., Luo, D., Kouwenhoven, B., Hobom, G. and Mueller, H. 1993. Molecular and biological characteristics of avian polyomaviruses: isolates from different species of birds indicate that avian polyomaviruses form a distinct subgenus within the Polyomavirus genus. *J. Gen. Virol.* 74: 229-237.
- Tomasek, O., Kubicek, O. and Tukac, V. 2008. Comparison of three template preparation methods for routine detection of psittacine beak and feather disease virus and avian polyomavirus with single and nested polymerase chain reaction in clinical specimens. *Avian Pathol.* 37(2): 145-149.