

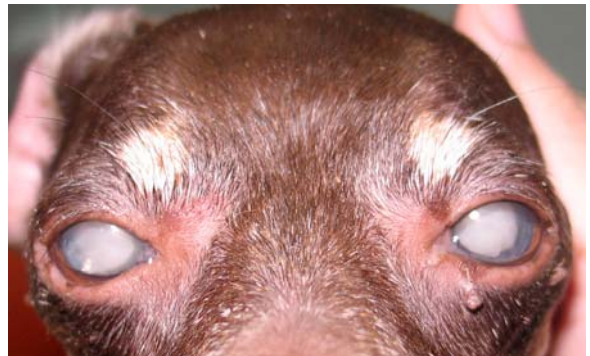## Ophthalmology Snapshot

Nalinee Tuntivanich

### *History*

A 9 year-old, female Miniature Pinscher was presented at the Ophthalmology Clinic, Animal Teaching Hospital, Chulalongkorn University with a chief complaint of rapid impaired blindness and white eye. Menace responses were negative while dazzle reflexes were strongly detected. Degree of conjunctival hyperemia was noticed on both eyes. Intraocular pressures were 5 mmHg.

The dog had had diabetic mellitus and been treated for over two years. Fasting blood glucose (FBG) at the first visit was 464 mg%, while it had been ranged 200-350 mg% during the past 2 years. Intraocular pressures measured from both eyes every visits were, for the whole time, below 10 mmHg.



**Figure 1** The female Miniature Pinscher presented with white eyes.

*(For better quality, figures can be viewed in the TJVM website)*

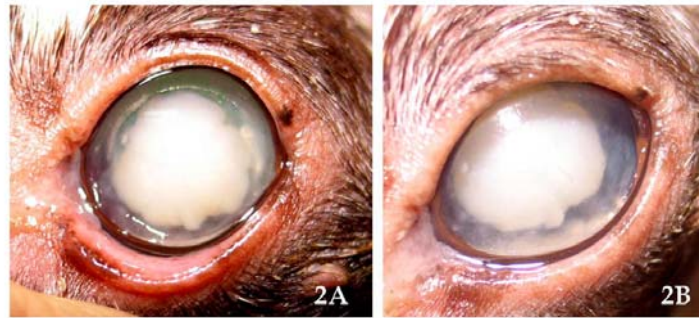
### **Question**

What is your diagnosis ?

Please turn to the next page for answers .....

**Answer**

Diabetic cataract



**Figure 2** Front views of the left eye revealing aggressive lens resorption (2A) and precipitation of lens protein in the anterior chamber (2B).

(For better quality, figures can be viewed in the TJVM website)

**Comments**

A concern of Diabetes mellitus (DM) should be taken when dogs are presented with rapid onset of cataract and impaired vision. Ophthalmoscopic examinations initially reveal very opaque, swollen lenses known as intumescent cataract. As diabetic cataract rapidly progresses, hypermature cataract characterized by resorbed lens is usually noticed.

When more glucose enters sorbitol pathway in hyperglycemic dogs, accumulation of sorbitol, fructose and dulcitol occurs upon metabolism of aldose reductase in the lens. Increased lens cell membrane permeability leads to fluid ingress, accumulation of osmotic products, glycosylation of lens protein and shortly, dense cataract formation. Rapid swollen lens, resulting in an increased porosity of intact lens capsule, can cause small tear or spontaneous lens capsule rupture in canine cases associated with DM.

Leakage of lens protein into the aqueous elicits phacoclastic uveitis; immune-mediated mechanism of the body to lens protein, which is normally isolated inside the lens capsule. Topical NSAID is recommended to control lens-induced

uveitis. Cataract surgery is advised with high success prior to the development of uveitis as well as other secondary complications.

**References**

- Basher AW and Roberts SM. 1995. Ocular manifestations of diabetes mellitus: diabetic cataracts in dogs. *Vet Clin North Am Small Anim Pract.* 25(3): 661-676.
- Ofri R. 2013. Lens. In: *Slatter's fundamentals of veterinary ophthalmology.* 5<sup>th</sup> ed. DJ Maggs, PE Miller and R Ofri (ed.) St. Louis, Elsevier. 275, 280-281.
- Miller PE. 2013. Uvea. In: *Slatter's fundamentals of veterinary ophthalmology.* 5<sup>th</sup> ed. DJ Maggs, PE Miller and R Ofri (ed.) St. Louis, Elsevier. 234.
- Wilkie DA, Gemensky-Metzler AJ, Colitz CM, Bras ID, Kuonen VJ, Norris KN, Basham CR. 2006. Canine cataracts, diabetes mellitus and spontaneous lens capsule rupture; a retrospective study of 18 dogs. *Vet Ophthalmol.* 9(5): 328-334.