

Apitoxin Aquapuncture and Administration of Herbal Medicines in a Dog with Superficial Pyoderma

Cheng-Hung Lai^{1,2*} Pan-Chen Liu^{1,2} Wei-Ming Lee^{1,2} Han-Yuan Lin¹

Abstract

A 6-month-old, 7.2 kg, intact female mongrel stray dog was referred to the Veterinary Medical Teaching Hospital, National Chung Hsing University with a chief complaint of alopecia, and severe pruritus. A skin swab was obtained for bacterial culture, and *Staphylococcus pseudintermedius* was identified. The definitive diagnosis was canine superficial pyoderma. Apitoxin aquapuncture was performed to treat superficial pyoderma once a week for 5 weeks. The acupoints used in this clinical case included GV-14 (Da Zhui), BL-13 (Fei Shu), LI-11 (Qu Chi), BL-40 (Wei Zhong), ST-36 (Zu San Li), SP-6 (San Yin Jiao), and SP-10 (Xue Hai). In addition, the herbal medicines Shi Wei Bai Du Tang, Huang Lian Jie Du Tang, and Wu Wei Xiao Du Yin were orally administered twice a day for 5 weeks. The results indicated that apitoxin aquapuncture combined with the administration of herbal medicines resulted in a favorable therapeutic effect in the treatment of canine superficial pyoderma.

Keywords: apitoxin, aquapuncture, herbal medicine, superficial pyoderma

¹Veterinary Medical Teaching Hospital, College of Veterinary Medicine, National Chung Hsing University, No. 250-1, Kuo Kuang Road, Taichung, 402, Taiwan, R.O.C.

²Department of Veterinary Medicine, College of Veterinary Medicine, National Chung Hsing University, No. 250, Kuo Kuang Road, Taichung, 402, Taiwan, R.O.C.

*Corresponding author: E-mail: chlai@dragon.nchu.edu.tw

บทคัดย่อ

การฉีดน้ำพิษเหล็กในผึ้งร่วมกับการป้อนสมุนไพรเพื่อรักษาโรคผิวหนังอักเสบเป็นหนองในสุนัข

Cheng-Hung Lai^{1,2*} Pan-Chen Liu^{1,2} Wei-Ming Lee^{1,2} Han-Yuan Lin¹

สุนัขจรจัดพันธุ์ผสมเพศเมียอายุ 6 เดือน น้ำหนัก 7.2 กก. ถูกพามาที่โรงพยาบาลสัตว์ของมหาวิทยาลัย National Chung Hsing ด้วยอาการขนร่วงและคันอย่างรุนแรง การตรวจตรวจผิวหนังเพื่อการเพาะเชื้อแบคทีเรียพบเชื้อ *Staphylococcus pseudintermedius* การวินิจฉัยสรุปว่าเป็นโรคผิวหนังอักเสบเป็นหนองในสุนัข ในการรักษาใช้การฉีดน้ำพิษเหล็กในผึ้งรักษาสัปดาห์ละหนึ่งครั้ง ติดต่อกัน 5 สัปดาห์ โดยจุดที่ใช้ในการฉีดได้แก่ จุด GV-14 (Da Zhui) จุด BL-13 (Fei Shu) จุด LI-11 (Qu Chi) จุด BL-40 (Wei Zhong) จุด ST จุด Zu San Li จุด SP-6 (San Yin Jiao) และจุด SP-10 (Xue Hai) นอกจากนั้นยังมีการป้อนสมุนไพรยาจีน Shi Wei Bai Du Tang และ Huang Lian Jie Du Tang และ Wu Wei Xiao Du Yin วันละสองครั้งติดต่อกัน 5 สัปดาห์ ผลการรักษาพบว่าการฉีดน้ำพิษเหล็กในผึ้งร่วมกับการป้อนสมุนไพรให้ผลในการรักษาโรคผิวหนังอักเสบเป็นหนองในสุนัขเป็นที่น่าพอใจ

คำสำคัญ: พิษเหล็กในผึ้ง การฉีดน้ำ สมุนไพร โรคผิวหนังอักเสบเป็นหนองในสุนัข

¹Veterinary Medical Teaching Hospital, College of Veterinary Medicine, National Chung Hsing University, No. 250-1, Kuo Kuang Road, Taichung, 402, Taiwan, R.O.C.

²Department of Veterinary Medicine, College of Veterinary Medicine, National Chung Hsing University, No. 250, Kuo Kuang Road, Taichung, 402, Taiwan, R.O.C.

*ผู้รับผิดชอบบทความ E-mail: chlai@dragon.nchu.edu.tw

Introduction

Staphylococcus spp. is mainly harmless commensals of the skin and mucous membranes of man and other mammals. *Staphylococcus pseudintermedius* (formerly known as *S. intermedius*) is the most common causal agent of canine pyoderma, a bacterial skin condition that usually results from a primary underlying skin disorder (Ganiere et al., 2005; Sasaki et al., 2005; Fitzgerald, 2009). Canine pyoderma can be controlled with systemic or topical application of antibiotics (Jones et al., 2007; Toma et al., 2008). However, prolonged antibiotic treatment or incorrect selection of antibiotics may increase the opportunity for production of multi-drug resistant *S. pseudintermedius* strains (Sasaki et al., 2007; Meucci et al., 2010). Moreover, *S. pseudintermedius* can occasionally transfer from dogs to humans, the potential carriage of multi-drug resistant *S. pseudintermedius* in dogs can be a critical public health problem (Guardabassi et al., 2004; Frank et al., 2009).

Acupuncture and herbal medicine have been used throughout history for the treatment of various kinds of human diseases. The therapeutic effects of acupuncture combined with herbal medicine have been examined in various human skin diseases (Salameh et al., 2008; Qing et al., 2009). Several reports have described the therapeutic effects of acupuncture and herbal medicine on canine diseases, including

hepatic injury (Kim et al., 2007), hind limb paralysis (Jun et al., 2007^b), and acanthomatous epulis (Kim, 2008). However, there are few reports about acupuncture for the treatment of canine skin disease.

Apitoxin or honeybee venom is a bitter, colorless liquid. The active portion of the venom is a complex mixture of proteins that causes local inflammation and acts as an anticoagulant. Apitoxin contains at least 18 active components, including enzymes, peptides, and biogenic amines, which have a wide variety of pharmaceutical properties (Hider, 1988; Son et al., 2007). The main component is melittin, which comprises 40% to 50% of dry bee venom. Melittin is a strong anti-inflammatory agent and induces the production of cortisol in the body (Son et al., 2007). Anti-inflammatory and analgesic effects of apitoxin have been demonstrated (Kwon et al., 2002; Lee et al., 2004; Chen et al., 2006), and it has been shown to be useful for the treatment of some canine diseases. Kim et al. (2008) reported that apitoxin aquapuncture was an effective treatment for canine otitis externa, and that it might be an alternative treatment method for this condition. In addition, Jun et al. (2007^a) reported 3 cases of canine demodicosis that had favorable therapeutic responses to the combination of aquapuncture, antibiotics, and conventional treatment. Therefore, we attempted apitoxin aquapuncture combined with herbal medicines to treat superficial pyoderma in a dog.

Case History

A 6-month-old, 7.2 kg, intact female mongrel stray dog was referred to Veterinary Medical Teaching Hospital, National Chung Hsing University with a chief complaint of alopecia, and severe pruritus. The skin problems had affected the patient for about two months, and no treatment had been attempted prior to the referral. Physical examination revealed lesions on the trunk, ventrum, medial thigh, and lateral thorax region. Close examination of the patient revealed generalized pustules, crusted pustule, scales, and epidermal collarettes. Skin impression smear was performed on the lesions, and numerous neutrophils and Gram-positive cocci were observed. Hematological examination revealed decrease in RBC ($4.26 \times 10^6/\mu\text{l}$), MCHC (27.8 g/dl) and normal MCV (61.9 fl) level, there was normocytic and hypochromic anemia. Marked elevation of WBC ($33,500/\mu\text{l}$) might result from inflammation or infection.

Differential Diagnosis

Differential diagnosis was performed to rule out the underlying problems. Atopic dermatitis was ruled out according to the criteria established by Favrot et al. (2010). A home-made diet composing of rice and chicken was provided for 8 weeks to rule out food hypersensitivity. Ectoparasite infestations, sarcoptic mange, and demodicosis were ruled out by clinical examination, coat brushings, hair plucking, and skin scraping. Hypothyroidism was ruled out via detection of the concentration of total thyroxine (T4), and free thyroxine, compared to reference ranges (Peterson et al., 1997). *Malassezia* dermatitis and overgrowth were ruled out by light microscopic examinations of Diff-Quik (Sysmex, Japan) stained smear samples taken from lesional skin. Samples of hair, crust, and scale were collected from lesional skin for dermatophyte examination. Dermatophyte test medium (DTM) fungal culture was executed to isolate and identify dermatophyte organisms, but no colony grew after two weeks of cultivation.

A sample of purulent exudates was taken from skin lesions using a sterile swab for bacterial culture, and *Staphylococcus pseudintermedius* was identified according to standard methods including

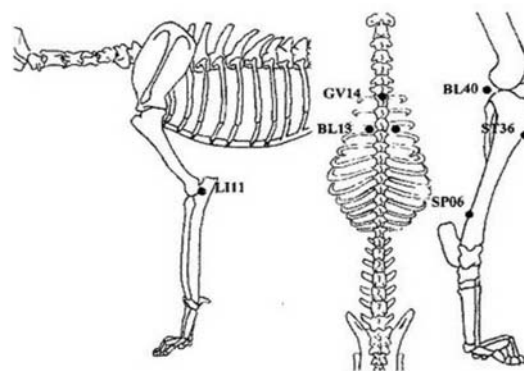


Figure 1 The acupoints used for apitoxin aquapuncture in the present case.

Gram staining, hemolysis, catalase test, production of coagulase, and DNA sequencing. Antibiotic sensitivity testing was performed with antibiotics frequently used to treat canine pyoderma at Veterinary Medical Teaching Hospital, National Chung Hsing University. The results indicated that this staphylococcal isolate was resistant to amoxicillin, ampicillin, cephalexin, cephalosin, and enrofloxacin. According to the results of differential diagnosis, the definitive diagnosis of this patient was canine superficial pyoderma.

Treatments

In this clinical case, we performed apitoxin aquapuncture for the treatment of canine superficial pyoderma. First, 1 mg of apitoxin (Apimez®, Korea) was dissolved in 1 ml saline. In each treatment, 0.2 ml apitoxin solution was drawn and mixed with an equal volume of 2% lidocaine and then diluted with saline to 1 ml. Then, the diluted apitoxin solution was injected into specific acupoints using a sterile syringe with 26G needle. The acupoints used in this case included GV-14 (Da-Zhui), BL-13 (Fei-Shu, both), BL-40 (Wei-Zhong, both), LI-11 (Qu-Chi, both), ST-36 (Hou-San-Li, both), and SP-6 (San-Yin-Jiao, both) (Fig 1 and Table 1). Approximately 0.05–0.1 ml of the apitoxin-lidocaine mixture was injected into each acupoint at each treatment session. Direct insertion of needles into skin ulcers, skin infection areas, and scar tissues was contraindicated. Apitoxin aquapuncture was performed once a week for 5 weeks.

Table 1 Anatomical locations of the acupoints used for apitoxin aquapuncture in the present case (Chrisman and Xie, 2007)

Acupoints		Location
BL-13	Fei-Shu	On the dorsolateral aspect of the spine, 1.5 cun lateral to the caudal border of the dorsal spinous process of T3.
BL-40	Wei-Zhong	In the center of the popliteal crease.
LI-11	Qu-Chi	On the lateral side of the thoracic limb at the lateral end of the cubital crease.
SP-06	San-Yin-Jiao	On the medial side of the pelvic limb 3 cun proximal to the tip of the medial malleolus in a small depression on the caudal border of the tibia.
ST-36	Hou-San-Li	On the cranio-lateral aspect of the pelvic limb, 3 cun to the depression distal to the patella, 0.5 cun lateral to the cranial aspect of the tibial crest.
GV-14	Da-Zhui	On the dorsal midline in the depression in front of the dorsal spinous process of the T1 vertebrae.

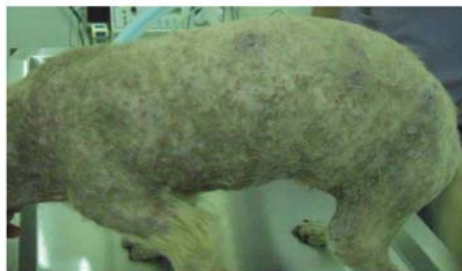

Figure 2 Generalized pustules, erythema, epidermal collarettes, and alopecia of the patient were noted pre-treatment.



Figure 3 Full recovery was achieved after five-week treatment.

In addition to apitoxin aquapuncture, traditional herbal formulas including Huang Lian Jie Du Tang (0.1 g/kg bw), Shi Wei Bai Du Tang (0.1 g/kg bw), and Wu Wei Xiao Du Yin (0.1 g/kg bw) (KODA Pharmaceutical Co., Taiwan) were simultaneously orally administered twice a day for 5 weeks.

The patient's skin lesions (pustules, scales, erythema, and alopecia) were significantly improved within two weeks and full recovery was achieved after five weeks of treatment (Fig 2 & 3). Hematological examination indicated that the values of WBC ($12,600/\mu\text{l}$), RBC ($6.38 \times 10^6/\mu\text{l}$), and MCHC (33.7 g/dl) returned to normal range. The patient was subsequently examined every two weeks for 6 months, and no relapse of superficial pyoderma was observed.

Discussion

Canine superficial pyoderma is one of the most common skin diseases in dogs, and is mainly treated with antibiotics. Furthermore, antiseptic shampoos are often used for canine superficial pyoderma in combination with antibiotics. Recently, Murayama et al. (2010) indicated that dogs with superficial pyoderma showed clinical improvement following twice-weekly treatment with 2% chlorhexidine acetate. However, the majority of dogs still required systemic antibiotics to resolve the infection. In this case, an alternative therapy was performed by apitoxin aquapuncture combined with the administration of herbal medicine. Aquapuncture is the injection of fluids and soluble products into acupuncture points. Sterile saline, vitamin B₁₂, and local anesthetics are most commonly used in Western acupuncture practice. Aquapuncture is used to lengthen and strengthen an acupuncture treatment (Ferguson, 2007).

In traditional Chinese medicine, pyoderma can be caused by wind, dampness, and heat. GV-14 can clear heat from the whole body; BL-40 and SP-10 can cool blood and clear heat; SP-6 can clear damp-heat; and LI-11 can open skin and clear wind. The lungs master the skin and hair, and BL-13 can strengthen lung function and thus improve skin and hair conditions. Moreover, the spleen is the "mother" element of the lung; ST-36 can tonify spleen Qi to reform the infirmities (Chrisman and Xie, 2007).

Huang Lian Jie Du Tang is composed of Huang Lian (Coptis), Huang Qin (Scutellaria), Huang Bai (Phellodendron), and Zhi Zi (Gardenia), and is used to treat heat or damp-heat in the entire body, and it is often used for the treatment of bacterial infections of the urinary tract, lungs, and skin (Wang et al., 2010). Huang Lian Jie Du Tang is contraindicated for patients with Yin deficiency heat. Shi Wei Bai Du Tang is made up of Fu Ling (Poria), Du Huo (Angelica), Jin Ying Zi (Rosa), Fang Feng (Ledebouriella), Jie Geng (Platycodon), Chuan Xiong (Ligusticum), Chai Hu (Bupleurum), Jing Jie (Schizonepeta), Gan Cao (Glycyrrhiza), and Sheng Jiang (Zingiberis). The main effect of Shi Wei Bai Du Tang occurs through the removal of inner and outer Xie Qi and detoxification. This herbal medicine can be used for the treatment of furuncles, pustules, phlegmon, lymphangitis, inflammation of the mammary gland, sinusitis, dermatitis, eczema, rhinitis, otitis externa, etc. However, it should be avoided in pregnant or nursing patients. Wu Wei Xiao Du Yin, which consists of Jin Yin Hua (Lonicera), Ju Hua (Chrysanthemum), Pu Gong Ying (Taraxacum), and Zi Hua Di Ding (Viola), has strong actions to clear heat, remove toxins, eliminate ulcers, and dissipate swelling on the surface. It is applicable to furuncles; pustules; swelling in various types of skin, muscles, joints, and organs; suppurative dermatitis; eczema; etc. However, it should be cautioned in patients with spleen Qi deficiency (Wang et al., 2010).

This case report demonstrates that in the treatment of canine superficial pyoderma, apitoxin aquapuncture together with traditional herbal medicine had a favorable therapeutic effect. However, further research involving more patients with superficial pyoderma is necessary to confirm the observed effect.

Acknowledgements

The authors would like to thank and remember Prof. Dr. Duck-Hwan Kim, Chungnam National University, Korea, for his enthusiastic guidance in acupuncture.

References

- Chen, Y.N., Li, K.C., Li, Z., Shang, G.W., Liu, D.N., Lu, Z.M., Zhang, J.W., Ji, Y.H., Gao, G.D. and Chen, J. 2006. Effects of bee venom peptidergic components on rat pain-related behaviors and inflammation. *Neurosci.* 138: 631-640.

- Chrisman, C. and Xie, H. 2007. Canine transpositional acupoints. In: Xie's Veterinary Acupuncture. 1st ed. H. Xie and V. Preast (eds.) Iowa: Blackwell. 129-215.
- Favrot, C., Steffan, J., Seewald, W. and Picco, F. 2010. A prospective study on the clinical features of chronic canine atopic dermatitis and its diagnosis. *Vet Dermatol.* 21: 23-30.
- Ferguson, B. 2007. Techniques of veterinary acupuncture and moxibustion. In: Xie's Veterinary Acupuncture. 1st ed. H. Xie and V. Preast (eds.) Iowa: Blackwell. 329-339.
- Fitzgerald, J.R. 2009. The *Staphylococcus intermedius* group of bacterial pathogens: species reclassification, pathogenesis and the emergence of methicillin resistance. *Vet Dermatol.* 20: 490-495.
- Frank, L.A., Kania, S.A., Kirzeder, E.M., Eberlein, L.C. and Bemis, D.A. 2009. Risk of colonization or gene transfer to owners of dogs with methicillin-resistant *Staphylococcus pseudintermedius*. *Vet Dermatol.* 20: 496-501.
- Ganiere, J.P., Medaille, C. and Mangion, C. 2005. Antimicrobial drug susceptibility of *Staphylococcus intermedius* clinical isolated from canine pyoderma. *J Vet Med B.* 52: 25-31.
- Guardabassi, L., Loeber, M.E. and Jacobson, A. 2004. Transmission of multiple antimicrobial-resistant *Staphylococcus intermedius* between dogs affected by deep pyoderma and their owners. *Vet Microbiol.* 98: 23-27.
- Hider, R.C. 1988. Honeybee venom: A rich source of pharmacologically active peptides. *Endeavour* 12: 60-65.
- Jones, R.D., Kania, S.A., Rohrbach, B.W., Frank, L.A. and Bemis, D.A. 2007. Prevalence of oxacillin- and multidrug-resistant staphylococci in clinical samples from dogs: 1,772 samples (2001-2005). *J Am Vet Med Assoc.* 230: 221-227.
- Jun, H.K., Han, J.W., Oh, H.U., Park, B.K., Park, S.J., Cho, S.W. and Kim, D.H. 2007^a. Injection acupuncture combined by conventional treatment in canine demodicosis: Case report. *J Vet Clin.* 24: 432-436.
- Jun, H.K., Park, S.K., Kim, D.H., Kim, M.H., Xue, K.Y., Xue, C.L., Yao, C.J. and Gue, H.Y. 2007^b. Treatment by injection-acupuncture with apitoxin and apitoxin combined by Chinese herbal medicine in patients with canine hind limb paralysis: Case report. *J Vet Clin.* 24: 225-228.
- Kim, M.S. 2008. Application of acupuncture and Chinese herbal medicine for the treatment of acanthomatous epulis in a dog. *J Vet Clin.* 25: 27-30.
- Kim, S.H., Jun, H.K., Kim, S., You, M.J., Jun, M.H. and Kim, D.H. 2008. Therapeutic effect of injection-acupuncture with bee-venom (apitoxin) in cases of canine otitis externa. *J Vet Clin.* 25: 159-164.
- Kim, T.K., Kim, S.H., Jun, H.K., Cho, S.W. and Kim, D.H. 2007. Recovery effect of Xiao Chai Hu Tang (So Si Ho Tang) on hepatic injury in dogs. *J Vet Clin.* 24: 164-168.
- Kwon, Y.B., Lee, H.J., Han, H.J., Mar, W.C., Kang, S.K., Yoon, O.B., Beitz, A.J. and Lee, J.H. 2002. The water-soluble fraction of bee venom produces antinociceptive and anti-inflammatory effects on rheumatoid arthritis in rats. *Life Sci.* 71: 191-204.
- Lee, J.D., Kim, S.Y., Kim, T.W., Lee, S.H., Yang, H.I., Lee, D.I. and Lee, Y.H. 2004. Anti-inflammatory effect of bee venom on type II collagen-induced arthritis. *Am J Chin Med.* 32: 361-367.
- Meucci, V., Vanni, M., Guardabassi, L., Moodley, A., Soldani, G. and Intorre, L. 2010. Evaluation of methicillin resistance in *Staphylococcus intermedius* isolated from dogs. *Vet Res Commun.* 34 (Suppl 1): S79-82.
- Murayama, N., Nagata, M., Terada, Y., Shibata, S. and Fukata, T. 2010. Efficacy of surgical scrub including 2% chlorhexidine acetate for canine superficial pyoderma. *Vet Dermatol.* 21: 586-592.
- Peterson, M.E., Melian, C. and Nichols, R. 1997. Measurement of serum total thyroxine, triiodothyronine, free thyroxine, and thyrotropin concentrations for diagnosis of hypothyroidism in dogs. *J Am Vet Med Assoc.* 211: 1396-1402.
- Qing, H., Tian, Y.S., Fan, J.M., Tang, B.Y., Niu, H.O. and Lu, J.Y. 2009. Meridian three-combined therapy for treatment of ordinary psoriasis: a multi-center randomized controlled study. *Zhongguo Zhen Jiu.* 29: 181-184.
- Salameh, F., Peria, D., Solomon, M., Gamus, D., Barzilai, A., Greenberger, S. and Trau, H. 2008. The effectiveness of combined chinese herbal medicine and acupuncture in the treatment of atopic dermatitis. *J Altern Complement Med.* 14: 1043-1048.
- Sasaki, A., Shimizu, A., Kawano, J., Wakita, Y., Hayashi, T. and Ootsuki, S. 2005. Characteristics of *Staphylococcus intermedius* isolates from diseased and healthy dogs. *J Vet Med Sci.* 67: 103-106.
- Sasaki, T., Kikuchi, K., Tanaka, Y., Takahashi, N., Kamata, S. and Hiramatsu, K. 2007. Methicillin-resistant *Staphylococcus pseudintermedius* in a veterinary teaching hospital. *J Clin Microbiol.* 45: 1118-1125.
- Son, D.J., Lee, J.W., Lee, Y.H., Song, H.S., Lee, C.K. and Hong, J.T. 2007. Therapeutic application of anti-arthritis, pain-releasing, and anti-cancer effects of bee venom and its constituent compounds. *Pharmacol Ther.* 115: 246-270.
- Toma, S., Colombo, S., Cornegiani, L., Persico, P., Galzerano, M., Gianino, M.M. and Noli, C. 2008. Efficacy and tolerability of once-daily cephalexine in canine superficial pyoderma: An open controlled study. *J Small Anim Pract.* 49: 384-391.
- Wang, X., Bartholomew, M. and Xie, H. 2010. Herbal formulas to clear heat. In: Xie's Chinese Veterinary Herbology. 1st ed. H. Xie and V. Preast (eds.) Iowa: Wiley-Blackwell. 368-389.

