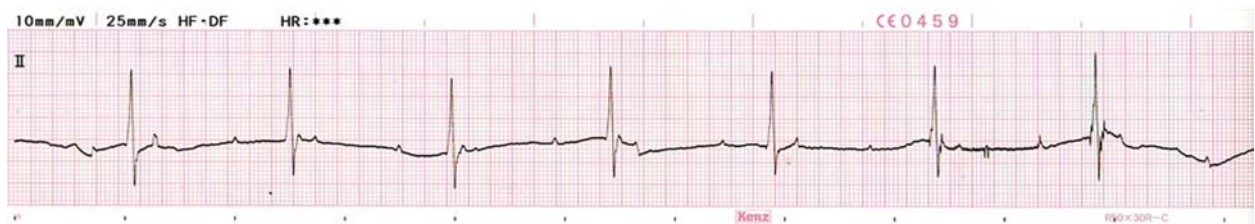
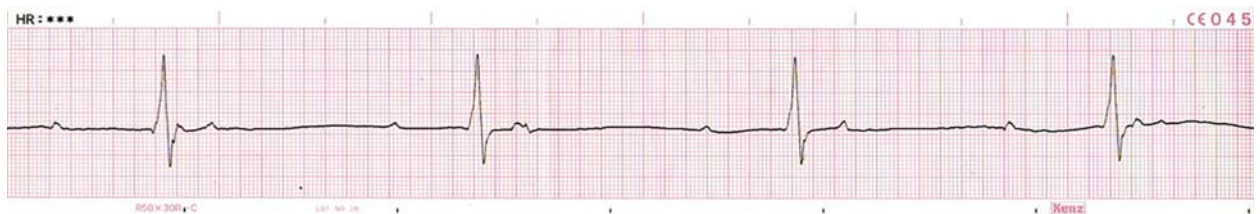
ECG Quiz

Chollada Buranakarl¹ Monkon Trisiriroj² Thanusorn Phakhawambodee²



Paper speed 25 mm/sec



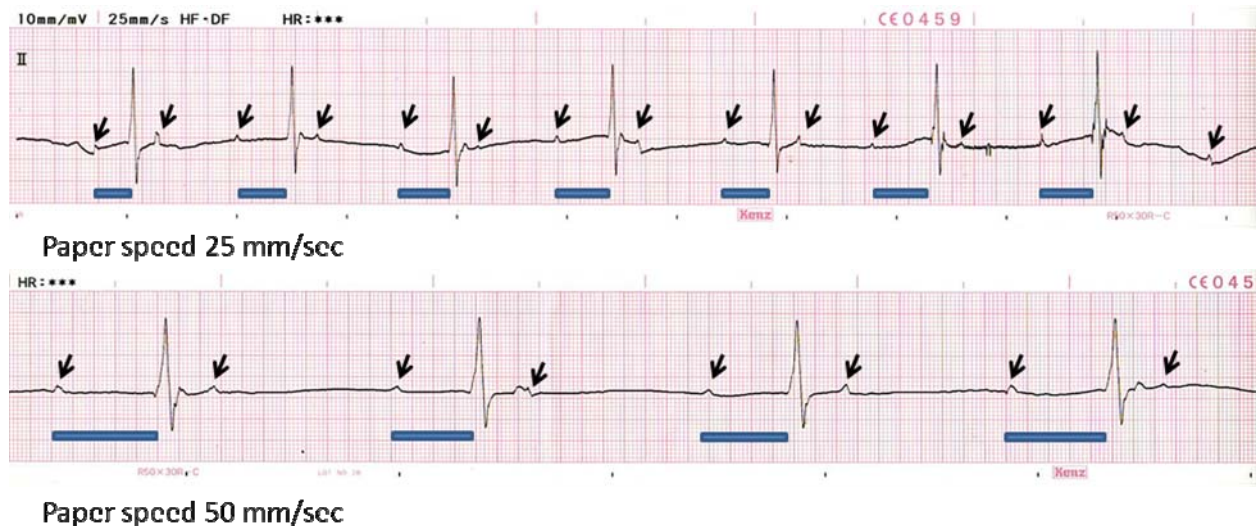
Paper speed 50 mm/sec

These lead II ECG strips were recorded from a twelve years old male uncastrated mixed breed dog weighing 16.1 kg. He was referred to the Small Animal Teaching Hospital, Chulalongkorn University with a history of exercise intolerance and dysuria. He was diagnosed from the local veterinarian to have prostate gland enlargement and urethral calculi from radiography. From physical examination, the dog had mild depression with increased lung sound. Mild abdominal clamp was found during palpation. The abdominal radiography showed multiple small cystic calculi with normal size prostate gland. The thoracic radiograph showed left heart enlargement with mild

pulmonary edema at perihilar area. Blood collection reviewed normal complete blood count. The BUN and creatinine were 15 mg/dl and 1.0 mg/dl, respectively. Urinalysis showed urine with pH 6, mild proteinuria (+1) with urine specific gravity of 1.022. There were some white blood cells (10/HPF) in the urine sediment. The echocardiography was performed and mild mitral valve endocardiosis was found with fractional shortening of 55% and LA/AO ratio was 1.12. The antibiotics and cardiac drug including angiotensin converting enzyme inhibitor and low dose diuretics were prescribed.

Please answer before turning to the next page.

¹Department of Veterinary Physiology, ²Small Animal Hospital, Faculty of Veterinary Science, Chulalongkorn University



Interpretation

Third degree atrioventricular block with junctional escape rhythm

The ECG tracings showed atrial rate which corresponded to multiple P-waves (small arrows) with the rate of approximately 75 beats per minute, while the ventricular rate (QRS complexes) was 40 beats/minute. The atrioventricular (AV) block was diagnosed. It was noticed that the durations between preceding P-waves and the QRS complexes were inconsistent (thick lines), therefore, these QRS complexes did not follow the impulses originated from SA node that was spreading throughout the atriums. No relationship between P waves and QRS complexes was found. Thus, no PR interval was found in this circumstance. All P-waves in which the impulses were originated from sinoatrial (SA) node were non-conducted P-waves and the rate was resemble normal heart rate. Since the atrioventricular dissociation occurred, the escape beats were emerged. The ventricular action potentials were originated from other ectopic foci under the area of blocking. Since the

shape of ectopic complexes was similar to normal QRS waves except there was no preceding P-wave and the slope of prepotential of AV nodal cells was the steepest among cardiac tissue rather than SA node, the pacemaker cell may be located at or nearby the AV node. The ventricular ectopic impulses were regular and originated between atrium and ventricle which was called "junctional rhythm". The ectopic pacemaker rate was slower than the normal SA node. The cardiac output will be low in this case since blood was ejected only after ventricular was contracted. The cause of third degree AV block is usually associated with the intrinsic heart disease rather than vagal overstimulation. However, atropine challenging test may be advantage to rule out the autonomic modulation as the treatment protocol. Ventricular rate could be accelerated by using adrenergic agonists or bronchodilator. However, insertion of cardiac pacemaker will be required if the animal has unstable clinical signs due to inadequate cardiac output.