

## ECG Quiz

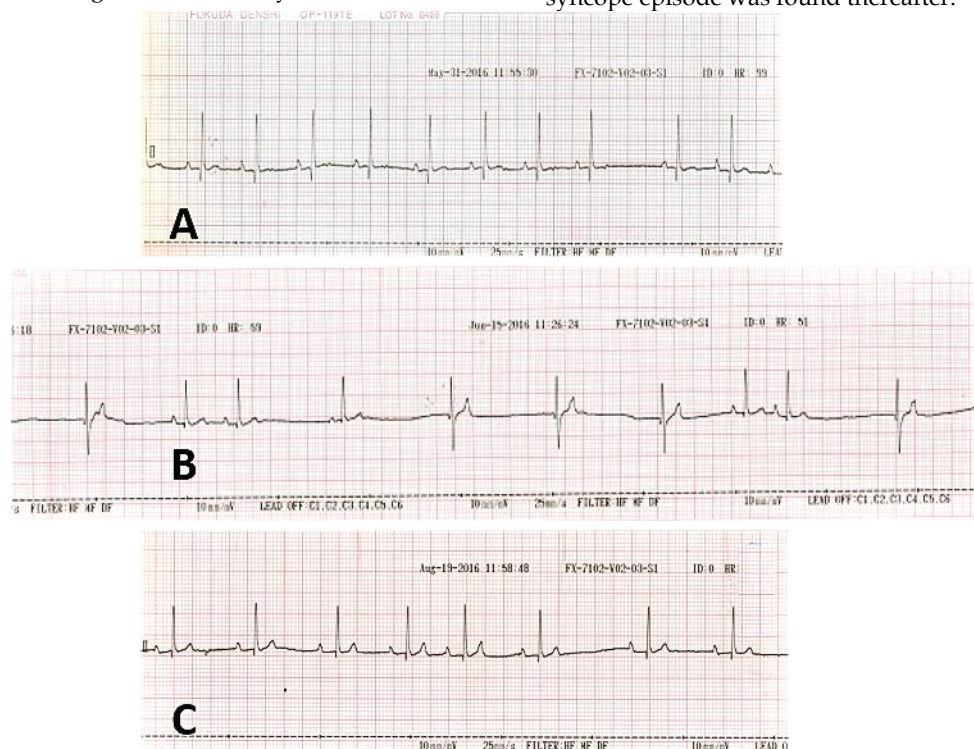
**Chollada Buranakarl<sup>1\*</sup> Saikaew Sutayatram<sup>1</sup>**

### History

A 14-year-old castrated male mixed breed dog, weighting 16 kilograms (body condition score 4/5). The systolic murmur heart sound grade II/VI was first detected two year ago while the medication, angiotensin converting enzyme inhibitor, was begun at that time. The progression was developed until in 2016 with clinical signs of exercise intolerance and coughing. The chest radiography showed cardiomegaly with mild perihilar lung infiltration. Echocardiogram indicated thickening of mitral valve with severe MR, decreased left sided systolic function, and severe LA enlargement. Abdominal ultrasonography showed both adrenal gland hyperplasia with hepatic congestion and nodules. Spironolactone and a positive inotrope (pimobendan) were added.

Later on, the dog was referred to the emergency unit of the Small Animal Teaching Hospital, Chulalongkorn University. The owner

reported that the dog had syncope and felt three days ago and after recovery the dog was anorexia and vomiting. Physical examination revealed that the dog was dehydrated with pale mucus membrane while he was on lateral recumbence. The dog had hypotensive with systolic blood pressure of 70 mmHg. ECG was show in Fig 1A. Blood work indicated thrombocytopenia, increased liver enzymes (ALP and ALT), and azotemia. Urinalysis depicted mild proteinuria with concentrated urine and urinary tract infection. Fluid, antibiotic, and supportive therapy were started. During the course of treatment, doxycycline was given to the dog since blood smear was positive for blood parasites, *Ehrlichia canis* and *Hepatozoon* spp. Two weeks later, although clinical symptoms were improved, the irregular pulse was detected and ECG recording was repeated (Fig. 1B). No medication for treatment of arrhythmia was given. ECG recorded two months later showed the respiratory sinus arrhythmia (Fig. 1C) while no syncope episode was found thereafter.



**Figure 1** The ECG tracing which were recorded in a dog at the emergency unit at first arrived (A) two weeks and 2 months after discharged, respectively (A-C) (paper speed of 25 mm/sec).

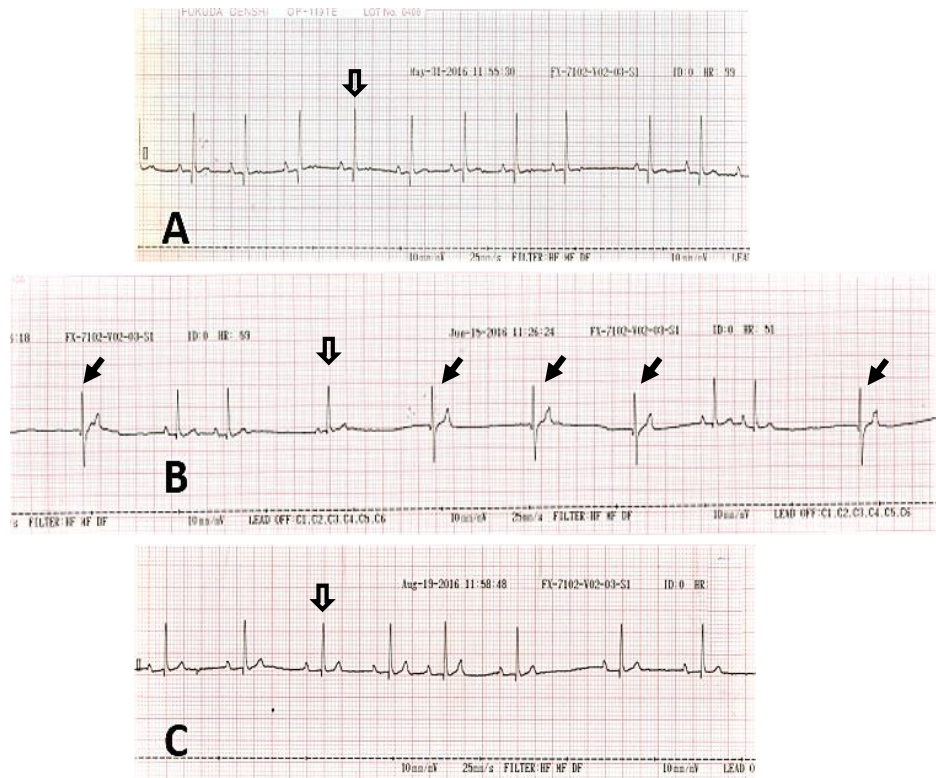
Please answer before turning to the next page.

<sup>1</sup>Department of Veterinary Physiology, Faculty of Veterinary Science, Chulalongkorn University

## Interpretation

Figure 1A and 1C  
Figure 1B

- Sinus arrhythmia
- Sinus arrhythmia with periodic junctional rhythm



The tracing in Figure 1A and 1C showed the dog had sinus arrhythmia which may be due to respiratory origin (hollow arrows). The heart rate was approximately 75 beats/min. On the first admission, the clinical signs was unstable with hypotensive without tachycardia which suggested that the cardiovascular reflex may not be fully function. However, the hypotensive problem may not be associated with cardiac problem but rather be due to fluid deficit and/or vascular dilation. After 2 weeks of recovery, however, the dog came back with arrhythmia in which the ECG showed 2 different locations of pacemaker, sinus (hollow arrow) and ectopic focus (solid arrow) probably at the atrioventricular junction.

The origin of impulse was not located from sinus since there is no preceding P-wave or atrial depolarization. However, the impulse was propagated through the Bundle of His because of the similar shape of R wave was seen compared to R wave originated from normal sinus. Moreover, the rate of these

abnormal complexes was slightly lower than the sinus rate (55 beats/min).

It was noticed that the irregular rate from sinus occurred first and the ectopic impulse may emerge after a long pause from sinus. This pause may not be considered to be sinus block. The abnormal complexes which was found after sinus long pause also should not be considered as escape beats since they may be seen when the slope of diastolic potential of ectopic beats was steeper than that of sinus. The causes of acceleration of junctional ectopic rhythm that override the sinus arrhythmia may not be fully understood but may be related to over activity of cardiac sympathetic modulation. Impaired autonomic nervous system activity may arise from blood parasitic infection and/or nervous system disorder due to traumatic injury since the signs of brain trauma was seen after the dog was felt during syncope episode. This abnormal impulse generation was disappeared 2 months thereafter without further syncope.