

## Treatment Outcomes in Eales' Disease with Vitreous Hemorrhage at Tertiary Center in Southern Thailand

Thada Tantisarasart, M.D., Patama Bhurayanontachai, M.D.

Department of Ophthalmology, Faculty of Medicine, Prince of Songkla University, Hat Yai, Songkhla 90110, Thailand.

Received 28 March 2021 • Revised 2 September 2021 • Accepted 9 September 2021 • Published online 18 October 2021

### Abstract:

**Objective:** To assess the anatomical and functional outcomes of Eales' disease with secondary vitreous hemorrhage after conservative treatment and/or pars plana vitrectomy (PPV).

**Material and Methods:** A retrospective chart review of patients, diagnosed with Eales' disease, at Songklanagarind Hospital from January 2003 to December 2017 was performed. Thirty-two eyes, from 28 patients, with secondary vitreous hemorrhage underwent conservative treatment and/or PPV; depending on the degree of vitreous hemorrhage, clinician consideration and patient's decision.

**Results:** Twenty-five eyes, with low-grade (grade 1–3) and dense (grade 4) vitreous hemorrhage, initially underwent conservative treatment; in which 64.0% achieved final best corrected visual acuity (BCVA)  $\geq 20/70$  and 56.0% achieved final BCVA  $\geq 20/40$  with complete resolution of vitreous hemorrhage. However, 8 eyes eventually required additional PPV as a result of non-resolving vitreous hemorrhage. Alternatively, 7 eyes with dense vitreous hemorrhage (grade 4) at the presentation, preferred PPV as primary treatment, which resulted in final BCVA  $\geq 20/70$  in 57.0% and final BCVA  $\geq 20/40$  in 43.0%. Post vitrectomy complications included; cataract progression (52.9%), high intraocular pressure (35.3%), epiretinal membrane (23.5%), and rhegmatogenous retinal detachment (17.6%).

**Conclusion:** Anatomical and functional outcomes of Eales' disease with vitreous hemorrhage were relatively good following either conservative treatment or PPV. Each treatment option offered both advantages and disadvantages. The risks and benefits of each treatment option should be discussed with each individual patient to achieve the optimal outcome. Due to being a less invasive procedure, conservative treatment should be initially performed with close monitoring. In the

**Contact:** Patama Bhurayanontachai, M.D.  
Department of Ophthalmology, Faculty of Medicine, Prince of Songkla University,  
Hat Yai, Songkhla 90110, Thailand.  
E-mail: patama103@yahoo.com.au

J Health Sci Med Res 2022;40(3):359–366  
doi: 10.31584/jhsmr.2021844  
www.jhsmr.org

© 2021 JHSMR. Hosting by Prince of Songkla University. All rights reserved.  
This is an open access article under the CC BY–NC–ND license  
(<http://www.jhsmr.org/index.php/jhsmr/about/editorialPolicies#openAccessPolicy>).

minority of patients, vitrectomy still plays an important role to improve visualization and enable laser photocoagulation, despite potential risk of cataract progression.

**Keywords:** conservative treatment, Eales' disease, laser photocoagulation, outcome, pars plana vitrectomy, vitreous hemorrhage

## Introduction

Eales' disease is an idiopathic inflammatory venous occlusion that primarily affects the peripheral retina. The distinctive retinal findings include: perivascular phlebitis, peripheral capillary non-perfusion, and neovascularization.<sup>1</sup> Eales' disease generally affects young, healthy adults and there has been a male predominance in most series.<sup>1,2</sup> Although, the exact pathogenic mechanism of the disease is still unknown, it has long been postulated that immune-mediated mechanisms may play an important role in the pathogenesis. Various immunological studies have revealed the role of retinal S-antigen, interphotoreceptor retinoid-binding protein (IRBP), Human leukocyte antigen (HLA) and *Mycobacterium tuberculosis* (MTB) causing autoimmune responses in the eye.<sup>3,4</sup> The most favored etiologic theory is hypersensitivity to tuberculo-protein. Interestingly, negative Mantoux reaction has also been reported.<sup>5</sup> In retrospective studies, a significant number of MTB DNA tested by PCR were detected in the epiretinal membrane and vitreous fluid samples.<sup>6,7</sup> However, the etiology appears to be multifactorial. Although, it is rarely found in developed countries, it commonly affects young, healthy males at approximately 1 in 250 ophthalmic patients in India.<sup>8</sup> In Thailand, Apinyawasisuk reviewed the medical records of 47 patients with retinal vasculitis, and reported that the most common clinical entities in the non-infectious group was Eales' disease in 23.0% (11 of 47 patients).<sup>9</sup> The natural course of Eales' disease is characterized by 3 sequential vasculopathic stages: inflammation (peripheral retinal perivasculitis); occlusion (peripheral retinal capillary

non-perfusion); and neovascularization of the retina or optic disc, which often leads to retinal or vitreous hemorrhage. Significant visual deterioration can occur as a result of recurrent episodes of vitreous hemorrhage, macular changes, and tractional or combined retinal detachment involving macula.<sup>10</sup> However, vitreous hemorrhage was observed to be the most common presenting feature (49.3%).<sup>11</sup>

The management of vitreous hemorrhage secondary to Eales' disease has varied among several different clinical practices.<sup>1-3</sup> Yet, there has been an absence of a randomized controlled clinical trial. Currently, there are two main treatment options; including, conservative treatment pars plana (PPV). Firstly, conservative treatment comprises of observation, by keeping the head in the upright position in the hope that the bleeding will be spontaneously absorbed, and peripheral laser photocoagulation over the ischemic area when the fundus becomes visible<sup>12</sup>, including, injection of intravitreal bevacizumab in certain cases.<sup>13</sup> Secondly, vitreoretinal surgery, by vitrectomy, which is usually reserved for eyes with non-resolving vitreous hemorrhage, multiple vitreous membranes with or without tractional retinal detachment, and combined tractional and rhegmatogenous retinal detachment.<sup>14</sup> Nevertheless, there are no established guidelines regarding the timing of vitrectomy in cases of vitreous hemorrhage secondary to Eales' disease.

Despite an endemic area of tuberculosis in Thailand, there have been only a few studies regarding Eales' disease and none of them reported the outcomes of treatments. The author, therefore, analyzed both anatomical and functional

outcomes among this group of patients. This will provide crucial information to aid both physicians and patients to make decisions in the management of vitreous hemorrhage secondary to Eales' disease.

## Material and Methods

A retrospective chart review of patients with vitreous hemorrhage secondary to Eales' disease was carried out. This study was conducted from 1 January 2003 to 31 December 2017, at the retina clinic of Songklanagarind Hospital, a tertiary care center in Songkhla, Thailand. In reference to a new classification by Saxena et al.<sup>15</sup>, only stage 3b were recruited into our study. A diagnosis of Eales' disease was based on history, clinical examination, and relevant screening tests of the patient. Due to the fact that Eales' disease is primarily a diagnosis of exclusion, vitreous hemorrhage secondary to diabetic retinopathy, retinal vein occlusion, aged-related macular degeneration, retinal macroaneurysm, retinal vascular tumors, posterior vitreous detachment, retinal breaks, and trauma were excluded from the study. The study was approved by the Ethics Committee of the Faculty of Medicine, Prince of Songkla University (REC. 60-027-02-4).

The data consisted of age, gender, laterality of involvement, history of contact with patients with tuberculosis, the result of a purified protein derivative (PPD) skin test, chest X-ray, computed chest tomography (CT chest), best corrected visual acuity (BCVA) measured by the Early Treatment of Diabetic Retinopathy Study chart, intraocular pressure (IOP), lens status, fundus examination, fundus fluorescein angiography (FFA) in cases of visible fundus, and degree of vitreous hemorrhage, which were categorized into the following 4 grades; modified from a previous study by Lieberman et al.<sup>16</sup> Grade 1: minimal vitreous hemorrhage, optic disc and retinal vessels were clearly visible, Grade 2: mild vitreous hemorrhage, most of the optic disk and retinal vessels were visible, Grade 3:

moderate vitreous hemorrhage, optic disc, or retinal vessels were barely visible. Grade 4: severe vitreous hemorrhage was too dense to allow visualization of the optic disc. All of the data were collected at the first visit at the eye clinic, during the first six months of follow up after treatment, or at the last visit.

In this study, patients underwent conservative treatment and/or vitrectomy, depending on the degree of vitreous hemorrhage, clinician consideration and patient's decision. In spite of dense vitreous hemorrhage, most patients initially received conservative treatment. However, some patients decided to undergo vitrectomy. An ultrasonography was performed in every case with dense vitreous hemorrhage to evaluate if retinal detachment (RD) presented. In such cases, the patient with RD would be excluded from the study. The cases with a milder degree of vitreous hemorrhage and fundus that could be visualized, laser photocoagulation with/without intravitreal anti-VEGF injection was considered to limit activity of neovascularization. Recurrent vitreous hemorrhage; defined as a vitreous hemorrhage that occurs after the complete resolution of previous bleeding, was also recorded.

The sample size was calculated based on a study by Kumar et al.<sup>17</sup>, which reported visual outcomes following early PPV [proportion=0.65] and deferred PPV [proportion=0.20] in Eales' disease with vitreous hemorrhage. Two independent proportions (two-tailed test) were used with 95% confidence level (Alpha=0.05, Beta=0.2), the calculated sample size was: 22 eyes/group. Due to the rarity of the disease, 15 years of data collection was performed from 2003 to 2017.

The statistical analysis was performed using the R software 3.3.3 (R foundation for statistical Computing, Vienna, Austria). Continuous variables including age, recovery time of vitreous hemorrhage, and onset of recurrent vitreous hemorrhage was presented as mean and standard deviation or median and interquartile

range. Categorical variables; such as, gender, retinal findings, BCVA, grading of vitreous hemorrhage, disease complications and post-operative complications were calculated as percentage and proportion. Fisher's exact test was used to compare visual acuity outcomes for each treatment group. A p-value less than 0.050 was considered statistically significant.

## Results

In a 15-year review period, 32 eyes of 28 patients diagnosed clinically as Eales' disease with vitreous hemorrhage at presentation were included in the study. Patient's clinical characteristics and demographic data are summarized in Table 1. All of the patients were male. Patient age ranged from 19 to 65 years, with the mean age of  $34.11 \pm 10.39$  years. Twenty patients (71.4%) showed bilateral involvement. Presenting symptoms were visual loss (78.0%) and floater (22.0%). Tuberculin (PPD) test results were recorded in 23 patients, and considered as a positive response (induration 10 mm) in 14 cases (60.0%). Evidence of pulmonary Tuberculosis (TB) infection was shown in chest X-rays of five patients. CT chest was performed in four patients (14.3%), due to uncertain chest X-ray interpretation; with one displaying evidence of previous TB infection. Seven patients (25.0%) received anti-tuberculosis therapy from a pulmonologist. None of the patients had a documented history of TB contact. None of the patients had evidence of other systemic diseases; such as, diabetes mellitus, hypertension, blood dyscrasias, hemoglobinopathy, sarcoidosis, or systemic lupus erythematosus.

The retinal findings noted at presentation or during pars plana vitrectomy are demonstrated in Table 1. Fundus fluorescein angiography was performed in seven patients; once their vitreous was clear. Fluorescein angiographic features included: leakage from neovascularization, telangiectasia, area of capillary non-perfusion and vascular staining. These vascular abnormalities were also detected in

**Table 1** Clinical characteristics and demographic data of patients

Clinical characteristics and demographic	n=28 patients
Gender	
Male, n (%)	28 (100)
Female, n (%)	0 (0.0)
Age (years)	
Mean (S.D.)	34 ( $\pm 10.4$ )
Median (min-max)	32 (19-65)
Laterality	
Bilateral, n (%)	20 (71.4)
Unilateral, n (%)	8 (28.6)
Retinal findings	n=32 eyes (%)
Perivascular sheathing	19 (59.4)
Neovascular elsewhere	18 (56.3)
Intra-retinal hemorrhage	13 (40.6)
Neovascular at disc	9 (28.1)
Sclerotic vessels	8 (25.0)
Pre-retinal hemorrhage	6 (18.7)
Epi-retinal membrane	4 (12.5)
Flame-shaped hemorrhage	3 (9.4)

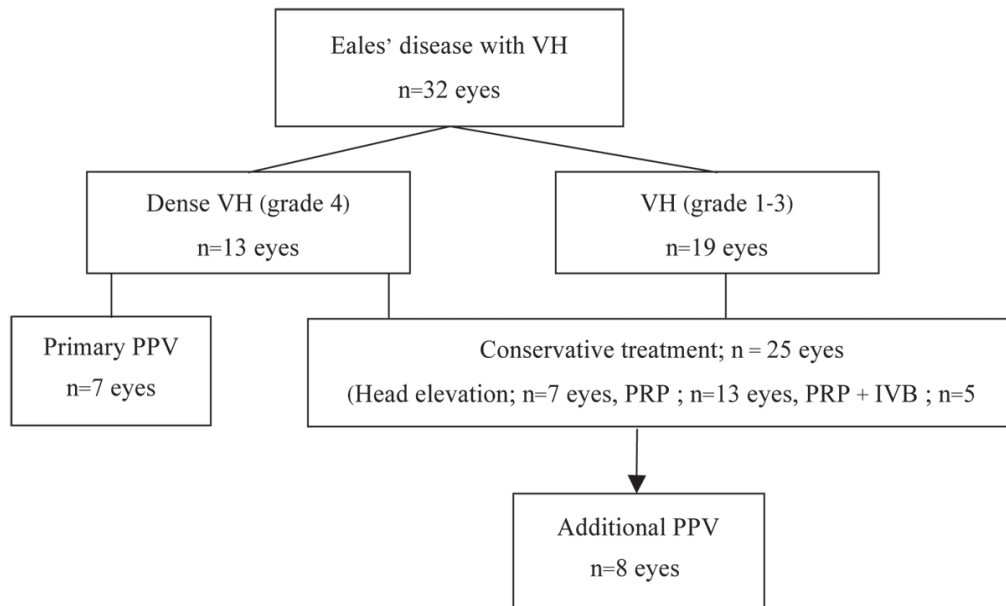
S.D.=standard deviation

the fellow eye of three patients, who had unilateral clinical presentation.

The treatment diagram is illustrated in Figure 1. At the first visit, among 13 eyes presenting with dense vitreous hemorrhage (grade 4), around half of them (7 eyes) decided to receive primary PPV and 6 eyes, contrary, preferred conservative treatment. On the other hand, 19 eyes in the group of low-grade vitreous hemorrhage (grade 1-3) decided to undergo conservative treatment.

Initial and final visual acuities of the eyes treated with conservative treatment and/or PPV are summarized in Table 2. Both treatment strategies provided a statistically significant improvement of visual acuity (p-value=0.026 and p-value=0.021, respectively).

Conservative treatment included observation with keeping the head in an elevated position in seven, pan-retinal photocoagulation (PRP) in thirteen, and additional intravitreal Bevacizumab in five. In total, conservative treatment was



VH=vitreous hemorrhage, PPV=pars plana vitrectomy, PRP=pan-retinal photocoagulation, IVB=intravitreal bevacizumab

Figure 1 Treatment diagram in the study

Table 2 Visual outcomes of eyes with vitreous hemorrhage in Eales' disease, following conservative treatment or vitrectomy

BCVA (Best corrected visual acuity)	Conservative treatment number (%) Total n=25		Vitrectomy number (%) Total n=7	
	Initial	Final	Initial	Final
<20/200	11 (44.0)	6 (24.0)	7 (100.0)	2 (29.0)
20/200-<20/70	2 (8.0)	3 (12.0)	0 (0.0)	1 (14.0)
20/70-<20/40	7 (28.0)	2 (8.0)	0 (0.0)	1 (14.0)
≥20/40	5 (20.0)	14 (56.0)	0 (0.0)	3 (43.0)
p-value	0.026		0.021	

performed in twenty-five eyes, including those initially presented with low-grade vitreous hemorrhage (grade 1-3) or dense vitreous hemorrhage (grade 4). From this 64.0% achieved final BCVA ≥20/70 and 56.0% of them achieved final BCVA ≥20/40, with complete resolution of vitreous hemorrhage and the regression of neovascularization. The median time for vitreous hemorrhage clearance was 120 days (range 30-148 days). However, six eyes (24.0%)

achieved a BCVA of less than 20/200, and eventually required another vitrectomy: five were due to non-clearing vitreous hemorrhage and one was due to tractional retinal detachment with macular involvement. Moreover, additional pars plana vitrectomy (PPV) was also performed in two eyes that achieved final BCVA between 20/200 and 20/70, because of incomplete resolution of vitreous hemorrhage.

Primary PPV was performed in seven eyes, because of dense vitreous hemorrhage. Endolaser panretinal photocoagulation was performed in every case that underwent vitrectomy. Over a half (57.0%) of them achieved BCVA  $\geq 20/70$  and 43.0% of them achieved BCVA  $\geq 20/40$  at final visit. However, two eyes (29.0%) eventually had BCVA  $< 20/200$  as a result of retinal detachment.

Overall, a total of 15 vitrectomized eyes (52.9%); including primary PPV and additional PPV, developed cataracts or had cataract progression and cataract surgery was subsequently performed. Other complications included: increased intraocular pressure in 35.2%, which were medically controlled, epiretinal membrane in 23.5% and rhegmatogenous retinal detachment in 17.6%. In contrast to vitrectomy, no treatment related complications were recorded following laser photocoagulation or intravitreal bevacizumab. None of the cases developed endophthalmitis in our series. Neovascular glaucoma occurred in three eyes, due to poor compliance for pan-retinal photocoagulation.

Recurrent vitreous hemorrhage was recorded in six eyes, including five eyes out of 25 eyes (20.0%) following conservative treatment and one eye out of seven eyes (14.0%) following vitrectomy. The earliest recurrent episode was found at one month following conservative treatment, and the latest recurrent episode was found at 96 months after vitrectomy.

## Discussion

Although Eales' disease is an uncommon idiopathic retinal vasculitis, it can lead to blindness in young, healthy men. A long-term cohort study performed by Biswas et al. described male predominance (95.2%) with bilateral involvement in 81.0% of Eales' disease cases.<sup>11</sup> Similar demographic data were shown in our study; all patients were male and 71.4% had bilateral presentation. Various etiologies have been established; with most of them emphasizing an association between Eales' disease and

tuberculosis.<sup>4,7</sup> Generally, the vasculitis in Eales' disease is believed to be a hypersensitivity response to tuberculin protein, rather than an active infection. It is postulated that the incidence of Eales' disease is higher in Asia than the Western world<sup>11</sup>, possibly due to the higher endemic area of tuberculosis in these countries; including Thailand.

In our retrospective study, we included 32 eyes, of 28 patients with clinical characteristics of Eales' disease that presented with vitreous hemorrhage at the retina clinic of Songklanagarind Hospital, Thailand. The clinical diagnosis was made by exclusion of other conditions that present with retinal vasculitis, and are accompanied by vitreous hemorrhage. Tuberculin testing was positive in 61.0% of our patients. However, negative tuberculin tests could be found in 39.0%, which is slightly higher than 27.0% in a previous study.<sup>4</sup>

Vitreous hemorrhage is the most common presentation of Eales' disease, and a the leading cause of visual loss in Eales' disease. In general, the management is initially conservative; wherein, vitrectomy is reserved for non-resolving vitreous hemorrhage or retinal detachment. However, prompt vitrectomy to fasten the clearance of blood, has been employed in some studies, with satisfactory long term visual outcomes.<sup>18</sup> In this study, we discussed treatment options with the patients; as to whether to begin with conservative treatment or undergo prompt vitrectomy, depending on the intensity of vitreous hemorrhage, clinician consideration and patient decisions.

As a result of this study, both conservative treatment and vitrectomy offered a significant improvement of functional outcome in patients with vitreous hemorrhage resulting from Eales' disease ( $p$ -value=0.026 and  $p$ -value=0.021, respectively), as shown in Table 2. The proportion of poor visual acuities (BCVA  $< 20/200$ ) decreased from 44.0% to 24.0%, following conservative treatment, and from 100.0% to 29.0% following vitrectomy at the last follow-up. Similarly, Dehghan et al.<sup>14</sup> reported reduction

in severe visual loss following laser therapy or vitrectomy; wherein, the percentage of eyes having visual acuities <20/200 declined from 16.0% before laser therapy to 9.0% after laser therapy, and from 50.0% before vitrectomy to 21.0% after vitrectomy. The majority of eyes in our study achieved final visual acuities of better than 20/200 in 71.0% following vitrectomy, and 76.0% following conservative treatment. Furthermore, 43.0% and 56.0% of eyes reached visual acuities better than 20/40 at final visit as a result of vitrectomy and conservative treatment, respectively. Similar to a previous study<sup>14</sup>, 38.0% and 60.0% of eyes could maintain visual acuities  $\geq 20/30$  following vitrectomy and laser photocoagulation. This study demonstrated that conservative and/or vitrectomy provided a relatively good visual outcome; similar to a previous report by Dehghan et al.<sup>14</sup> This satisfactory visual outcome may be due to the fact that Eales' disease is characterized by peripheral vasculopathy in nature, thereby sparing the macula. In contrast to the minority of the patients, unfavorable visual outcome as a result of disease complications; such as epiretinal membrane (12.5%) and neovascular glaucoma (9.0%), was lower than a previous large cohort<sup>11</sup>, with epiretinal membrane (26.0%) and neovascular glaucoma (21.9%); this may be possibly due to a smaller sample size. We also found that vitrectomy led to several post-operative complications. Cataract progression following vitrectomy (52.9%) was the most common complication, which was higher than in a previous study (38.1%).<sup>19</sup> The second most common complication was high intraocular pressure, which accounted for 35.3%; however, could be controlled by medication in all patients. A less common, but serious complication, was rhegmatogenous retinal detachment in 17.6%; with similar incidence to the prior report.<sup>20</sup>

Although vitrectomy led to several post-operative complications, it offered faster resolution of vitreous hemorrhage with the risk of cataract progression. Furthermore, less recurrent rate of vitreous hemorrhage following

vitrectomy may be less than conservative treatment, was possibly due to more adequate endo-photocoagulation.

We recommend that conservative treatment should be initiated in vitreous hemorrhage secondary to Eales' disease, because it offers similar functional outcomes to vitrectomy, and also provides many advantages over vitrectomy as well. Conservative treatment reduces the need of hospitalization, preserves operating resources and avoids the risk of vitrectomy complications. However, the disadvantages following conservative treatment were slower resolution of vitreous hemorrhage, as the median time of complete resolution in this study was 120 days. Additional vitrectomy was required in 32.0% of cases in our study, due to non-clearing vitreous hemorrhage. The conservative treatment may not be suitable for patients who need rapid visual recovery and tend to be lost to follow-up or laser photocoagulation. The behavior of recurrent vitreous hemorrhage in Eales' disease found in our study was quite diverse. Therefore, close monitoring and frequent follow-ups are crucial; especially for those opting for conservative treatment despite having dense vitreous hemorrhage.

Owing to its retrospective nature, this study had some limitations. Firstly, the small number of participants might not yield adequate generalization of the result. Secondly, multiple surgeons and examining clinicians could affect the treatment and outcome evaluations. Ultimately, various follow-up periods may influence a comparison of outcomes among patients.

## Conclusion

In summary, vitreous hemorrhage secondary to Eales' disease had a relatively good prognosis in the absence of macular pathology. Since no consensus had been established regarding treatment options; either conservative treatment or vitrectomy and the optimal time for vitrectomy, our study demonstrated that the anatomical and functional outcome of both treatment strategies were

satisfactory. Each treatment option offered both advantages and disadvantages. Frequent follow-up is essential for those deciding to undergo conservative treatment in order to provide adequate laser therapy and to monitor complications. Vitrectomy should be reserved for tractional retinal detachment involving the macula, or rhegmatogenous retinal detachment in order to avoid the risk of post-operative complications; such as, cataract formation, high IOP and rhegmatogenous retinal detachment. Finally, the recurrence times of vitreous hemorrhage in this disease were quite diverse, and regular long-term follow-up is necessary.

## Acknowledgement

The authors acknowledge Ms. Sujinda Damthong and Ms. Parichart Damthongsuk for their help with this study.

## Conflict of interest

The authors declare no conflicts of interest.

## References

- Das T, Pathengay A, Hussain N, Biswas J. Eales' disease: diagnosis and management. *Eye* 2010;24:472–82.
- Biswas J, Sharma T, Gopal L, Madhavan HN, Sulochana KN, Ramakrishnan S. Eales' disease—an update. *Surv Ophthalmol* 2002;47:197–214.
- Saxena S, Rajasingh J, Biswas S, Kumar D, Shinohara T, Singh VK. Cellular immune response to retinal S-antigen and interphotoreceptor retinoid-binding protein fragments in Eales' disease patients. *Pathobiology* 1999;67:39–44.
- Gupta P, Biswas J. Further evidence of the association of latent *Mycobacterium tuberculosis* in Eales' disease. *Int Ophthalmol* 2021;41:901–6.
- Muthukkaruppan V, Rengarajan K, Chakkalath HR, Namperumalsamy P. Immunological status of patients of Eales' disease. *Indian J Med Res* 1989;90:351–9.
- Agrawal R, Gunasekeran DV, Gonzalez-Lopez JJ, Cardoso J, Gupta B, Addison PKF, et al. Peripheral retinal vasculitis: analysis of 110 consecutive cases and a contemporary reappraisal of tubercular etiology. *Retina* 2017;37:112–7.
- Madhavan HN, Therese KL, Doraiswamy K. Further investigations on the association of *Mycobacterium tuberculosis* with Eales' disease. *Indian J Ophthalmol* 2002;50:35–9.
- Biswas J, Ravi RK, Naryanasamy A, Kulandai LT, Madhavan HN. Eales' disease – current concepts in diagnosis and management. *J Ophth Inflamm Infect* 2013;3:11.
- Pathanapitoon K, Rothova A, Apinyawasisuk S, Kunavisarut P. Clinical features and etiology of retinal vasculitis in Northern Thailand. *Indian J Ophthalmol* 2013;61:739–42.
- Saxena S, Kumar D. New classification system-based visual outcome in Eales' disease. *Indian J Ophthalmol* 2007;55:267.
- Biswas J, Reesha KR, Pal B, Gondhale HP, Sitaula RK. Long-term outcomes of a large cohort of patients with Eales' disease. *Ocul Immunol Inflamm* 2018;26:870–6.
- El-Asrar AMA, Al-Kharashi SA. Full panretinal photocoagulation and early vitrectomy improve prognosis of retinal vasculitis associated with tuberculo-protein hypersensitivity (Eales' disease). *Br J Ophthalmol* 2002;86:1248–51.
- Patwardhan SD, Azad R, Shah BM, Sharma Y. Role of intra-vitreous Bevacizumab in Eales' disease with dense vitreous hmoerhage. *Retina* 2011;31:866–70.
- Dehghan MH, Ahmadi H, Soheilian M, Azarmina M, Mashayekhi A, Naghibozakerin J. Therapeutic effects of laser photocoagulation and/or vitrectomy in Eales' disease. *Eur J Ophthalmol* 2005;15:379–83.
- Saxena S, Kumar D. A new staging system for idiopathic retinal periphlebitis. *Eur J Ophthalmol* 2004;14:236–9.
- Grillone LR LR, Gow JA. Development and implementation of a vitreous hemorrhage grading scale. *Retinal Physician* 2006;3:S1–8.
- Kumar A, Tiwari HK, Singh RP, Verma L, Prasad N. Comparative evaluation of early vs. deferred vitrectomy in Eales' disease. *Acta Ophthalmol Scand* 2000;78:77–8.
- Connors D, Shah G, Blinder K, Dang S. Early versus delayed vitrectomy for nondiabetic vitreous hemorrhage. *J Vitreoretin Dis* 2018;2. doi: 10.1177/2474126418758771.
- Khanduja S, Gupta S, Sinha S, Venkatesh P, Vohra R, Garg S. Surgical outcomes of minimally invasive vitrectomy surgery in Eales' disease. *Nep J Oph* 2013;5:182–9.
- Shanmugam MP, Badrinath SS, Gopal L, Sharma T. Long term visual results of vitrectomy for Eales' disease complications. *Int Ophthalmol* 1998;22:61–4.