

Carotid cavernous sinus fistula with central retinal artery occlusion: A case report

Suntaree Thitiwichienlert¹, Chonwarat Phattarapongdilok¹,
Paiboon Bawornwattanadilok¹

¹Department of Ophthalmology, Faculty of Medicine Thammasat University, Thailand

Background: A carotid-cavernous sinus fistula (CCF) is an abnormal arteriovenous communication between the cavernous sinus and the internal carotid artery (ICA) and/or external carotid artery (ECA). Central retinal artery occlusion (CRAO) is a rare posterior segment complication occurring as result of traumatic CCF from an ocular hypoperfusion.

Case Report: We present a 58-year-old female complaining of acute visual loss, with redness and swelling of the right eye following a motor vehicle accident. Her visual acuity was light perception (PL) in the right eye and 20/40 in the left eye. The intraocular pressure (IOP) was 52 mm Hg in the right eye and normal in the left eye. Eye examinations revealed proptosis, ptosis, complete total ophthalmoplegia and a 5-mm fixed dilated right pupil with relative afferent pupillary defect (RAPD) positive in her right eye. The fundus examination showed CRAO in the right eye. Cerebral angiography revealed a high flow direct CCF Barrow's type A. Endovascular treatment was performed using balloon embolization. During the one-year follow-up, the patient had improvement of eye redness, proptosis, and ophthalmoplegia. However, the visual prognosis was poor due to optic atrophy and macular ischemia with the final visual acuity of PL.

Conclusion: A complete fundus examination found vision-threatening complications in patients who have traumatic CCFs. Early recognition of CRAO is important in the management of these patients.

Conflicts of interest: The authors report no conflicts of interest.

Keywords: carotid cavernous sinus fistula, central retinal artery occlusion, endovascular treatment
EyeSEA 2020;15(1):1-5

DOI: <https://doi.org/10.36281/2020010101>

Background:

A carotid-cavernous sinus fistula (CCF) is an abnormal arteriovenous communication between the cavernous sinus and the internal carotid artery (ICA) and/or external carotid artery (ECA). Traumatic CCF is usually of a direct Barrow type A and has a high velocity of blood flow CCF, which can be formed by a traumatic tear in the cavernous portion of the ICA resulting in high blood flow direct shunts between the cavernous sinus and ICA.¹ Posterior segment complications may result from choroidal effusion, venous stasis retinopathy, or ocular hypoperfusion.² The

authors report a rare case of central retinal artery occlusion (CRAO), which is a posterior segment complication occurring as result of traumatic CCF from an ocular hypoperfusion.

Case report:

A 58-year-old female complained of acute visual loss, with redness and swelling of the right eye following a motor vehicle accident. On eye examination, the best corrected visual acuity (BCVA) was light perception (PL) in the right eye and 20/40 in the left eye. The intraocular pressure (IOP) was 52 mm Hg in the right eye and 13 mmHg in the left eye. She had complete ptosis in the right eye. Hertel's exophthalmometry showed a reading of 22 mm and 14 mm in the right and left eye, respectively with a base reading of 125 mm. The motility examination showed full duction in the left eye, but limited in all gaze directions in the right eye. The external

Correspondence to:

Suntaree Thitiwichienlert, Department of Ophthalmology,
Faculty of Medicine Thammasat University, Thailand

E-mail: punoipunoi@gmail.com

Received: January 28, 2020

Accepted: February 2, 2020

Published: June 30, 2020

examination of eyes showed marked proptosis and conjunctival chemosis (Figure 1). The slit lamp examination showed clear corneas and nuclear cataract, and a severely congested right conjunctiva with corkscrew vessels. The pupil size was a 5 mm fixed dilated right pupil and 3 mm react to light left pupil with relative afferent pupillary defect (RAPD) positive in her right eye. The fundus examination of the right eye showed whitening retinal edema and a cherry red spot at the macula with attenuated retinal arteries. Carotid bruit was detected on the right side. Based on the clinical presentation, an initial diagnosis of direct CCF with central retinal artery occlusion (CRAO) was made. The initial computerized tomography (CT) scan from a regional hospital showed a subarachnoid hemorrhage with a skull base fracture and dilated right superior ophthalmic vein (Figure 2). An urgent neurosurgical consultation was done. Cerebral angiography revealed a high flow direct CCF Barrow's type A with early contrast enhancement of the right cavernous sinus and the dilatation and early enhancement of the right superior ophthalmic vein. Endovascular treatment with balloon embolization was performed, and further cerebral angiography showed right direct CCF exhibited almost complete coil embolization due to the failure of balloon embolization (Figure 3). Subsequently cerebral angiography showed complete occlusion of the fistula without ICA stenosis. During the follow-up at one month later, carotid bruit was not detected, and the external eye and slit lamp examination showed similar findings. Dilated fundus examination showed right optic atrophy with attenuated arteries and epiretinal membrane. Fundus fluorescein angiography (FFA) showed a delay in the filling of the retinal arteries, a delayed arteriovenous transit time, and enlargement of the foveal avascular zone (FAZ) (Figure 4). During the one-year follow-up, the patient had improvement of eye redness, proptosis, ophthalmoplegia and secondary glaucoma. The visual prognosis was poor due to optic atrophy and macular ischemia with the final BCVA of PL.

Discussion:

CRAO is most often caused by embolization or atherosclerosis-related thrombosis occurring at the level of the lamina cribrosa. Less common causes are hemorrhage under an atherosclerotic plaque, thrombosis, trauma, spasm, and a

dissecting aneurysm within the central retinal artery.³ The possible mechanisms of CRAO in CCF include (1) direct increased intraocular pressure, or secondary increased intraorbital venous pressure causing CRAO, (2) traumatic damage to the endothelium of the blood vessels can cause formation of thrombosis, with the thrombus acutely occluding the vessel, (3) local vasoconstriction influenced by the traumatic injury can contribute to subsequent vasospasm of the central retinal artery, and (4) ocular hypoperfusion pressure from the diversion of blood to the cerebral venous system (posterior cortical venous drainage).⁴

Pierre Filho Pde T, et al. reported a rare case of CRAO complicating traumatic CCF with spontaneous closure of the fistula.⁵ They considered the possibility that blunt trauma, venous congestion and thrombosis of the fistula were the possible predisposing factors for CRAO. It is possible that when there is an elevation of pressure in the cavernous sinus, the pressure in the central retinal artery also increases, causing the obstruction of the retinal arterial circulation and this can explain for the progression from stasis retinopathy to CRAO.

In the present study, the patient had sudden severe visual loss and clinical features of direct CCF with CRAO. Posterior segment complications following CCF include CRVO from venous stasis retinopathy and CRAO. An increase in venous pressure can compromise retinal vein outflow and produces venous stasis retinopathy and CRVO.⁶ Rarely, CCF may cause CRAO from a steal phenomenon in the cerebral vessels. In this case, cerebral angiography did not show significant decreased flow into the right middle cerebral artery territory. Therefore, the patient did not have a strong evidence of a steal phenomenon. It is possible that an elevation of intraorbital venous pressure and intraocular pressure can explain the mechanism of CRAO because the initial IOP is very high.

The patient requires surgical treatment because endovascular treatment is indicated when the patient has progressive visual loss or signs of posterior cortical venous drainage. The goal of endovascular treatment is the closure of the fistula with preservation of carotid artery patency. The neurosurgeon selected detachable balloons for initial therapeutic cerebral angiography due to the relatively high effectiveness to

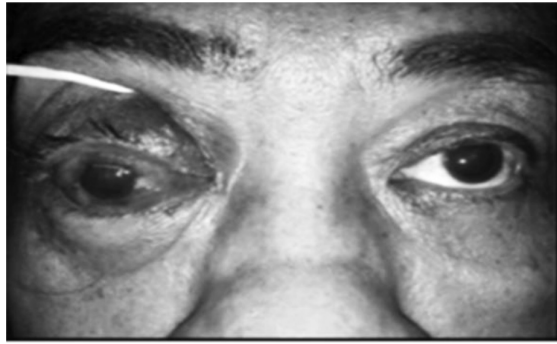


Figure 1 External examination of eyes shows marked proptosis and conjunctival chemosis in the right eye.

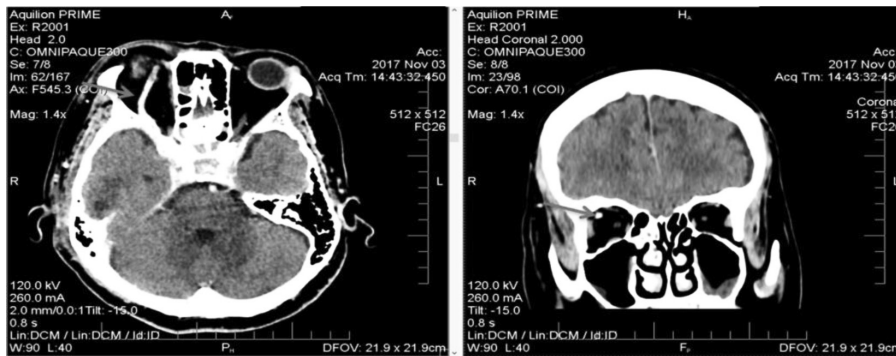


Figure 2 CT brain (a) axial view (b) coronal view show a dilatation of the right superior ophthalmic vein (red arrow).

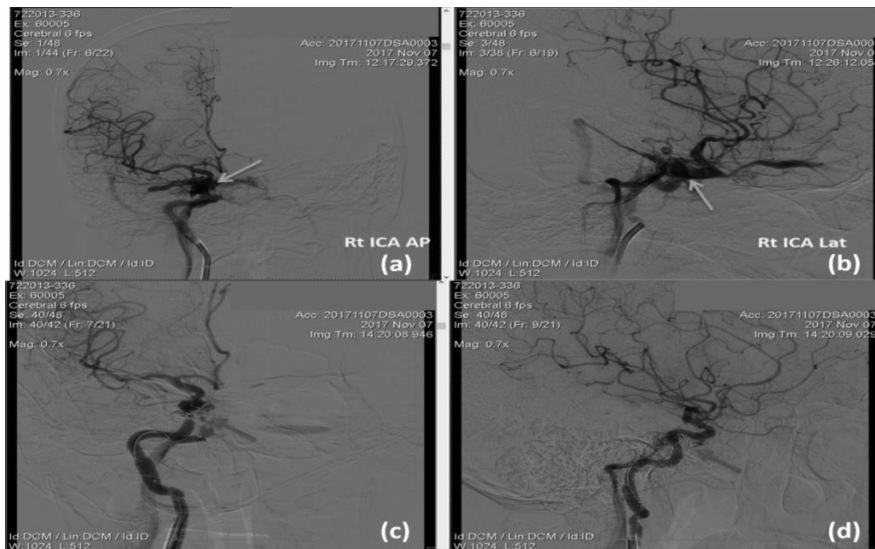


Figure 3 Cerebral angiography (a) anteroposterior (AP) view (b) lateral view showing a high flow direct CCF Barrow's type A with early contrast enhancement of the right cavernous sinus (green arrow) and the dilatation and early enhancement of the right superior ophthalmic vein (red arrow) (c) oblique view, and (d) lateral view showing nearly complete obliteration (blue arrow) of the right direct CCF post coil embolization.

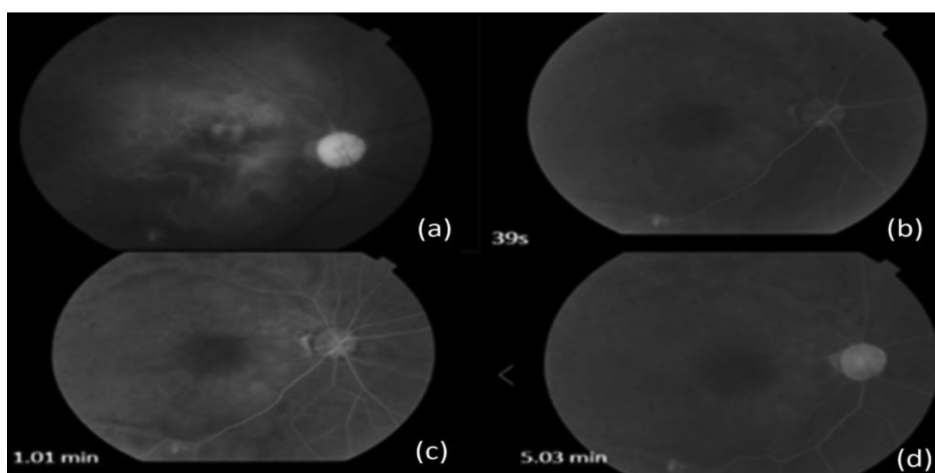


Figure 4 Fundus fluorescein angiogram (a) color fundus photograph (b) early phase (c) mid phase (d) late phase show a delay in the filling of the retinal arteries, a delayed arteriovenous transit time, and enlargement of FAZ.

directly occlude the fistula at low cost compared with the coil material.⁷ Unfortunately, CCF are difficult to treat with balloons embolization techniques and a further second coil embolization was performed. Recurrence during the early deflation of the balloons may explain lack of success of the treatment. However, further cerebral angiography showed right direct CCF underwent complete embolization without ICA insufficiency.

Once a fistula is completely closed, the clinical improvement depends on the severity and duration time that the fistula was present. During the long-term follow-up, the patient had improvement of a preexisting bruit, Corkscrew vessels, proptosis, ophthalmoplegia, and secondary glaucoma. Even when the fistula is completely closed and the ICA retains patency, visual loss caused by CRAO is least likely to improve. The previous studies in nonhuman primates have suggested that possible irreversible damage to the sensory retina occurs after 90 minutes of complete arterial occlusion.^{8,9} Fluorescein angiography images in our case reveal hypofluorescence of the retinal vessels and enlargement of the foveal avascular zone (FAZ) corresponding to an occlusion of the central retinal artery with macular ischemia. The latter results in poor visual prognosis and the patient's final visual acuity was light perception.

In summary, CRAO should be considered as a rare posterior segment complication in patients with traumatic CCF. Traumatic CCF

often require endovascular treatment and early recognition of CRAO is of clinical importance.

References:

1. Chi CT, Nguyen D, Duc VT, Chau HH, Son VT. Direct Traumatic Carotid Cavernous Fistula: Angiographic Classification and Treatment Strategies. *Interventional Neuroradiology* 2014;20:461-75.
2. Tan AC, Farooqui S, Li X, Tan YL, Cullen J, et al. Ocular manifestations and the clinical course of carotid cavernous sinus fistulas in Asian patients. *Orbit*. 2014;33:45–51.
3. Varma DD, Cugati S, Lee AW, Chen CS. A review of central retinal artery occlusion: clinical presentation and management. *Eye (Lond)*. 2013;27:688-97.
4. Pillai GS, Ghose S, Singh N, Garodia VK, Puthassery R, Manjunatha NP. Central retinal artery occlusion in dural carotid cavernous fistula. *Retina*. 2002; 22:493-4.
5. Pierre Filho Pde T, Medina FM, Rodrigues FK, Carrera CR. Central retinal artery occlusion associated with traumatic carotid cavernous fistula: case report. *Arq Bras Oftalmol*. 2007;70:868–70.
6. Alam MS, Jain M, Mukherjee B, et al. Visual impairment in high flow and low flow carotid cavernous fistula. *Sci Rep*. 2019;9(1):12872. Published 2019 Sep 6. doi:10.1038/s41598-019-49342-3
7. Wolpert SM. In re: Serbinenko FA.

- Balloon catheterization and occlusion of major cerebral vessels. *AJNR Am J Neuroradiol.* 2000;21:1359-60.
8. Hayreh SS, Zimmerman MB, Kimura A, Sanon A. Central retinal artery occlusion. Retinal survival time. *Exp Eye Res.* 2004;78:723-36.
 9. Hayreh SS, Kolder HE, Weingeist TA. Central retinal artery occlusion and retinal tolerance time. *Ophthalmology* 1980; 87:75-8.