

An ipsilateral white cataract following percutaneous nephrolithotomy

Aliyya Badaruddin¹, Choo May May¹

¹*Department of Ophthalmology, University Malaya Medical Centre, Malaysia.*

Background: There is a rising concern over the increasing amount of radiation exposure in patients undergoing diagnostic imaging and medical procedures. A case of rapid visual deterioration following a percutaneous nephrolithotomy (PCNL) has been described. The aim of this paper is to report the formation of semi-acute white cataract following a PCNL procedure.

Methods: Case Report

Results: A 57-year-old gentleman with underlying hypertension, gout and history of right nephrolithiasis complained of rapid deterioration in his right eye (RE) vision for 3 months duration. It was not associated with eye pain, redness, eye discharge or history of eye trauma. He denied taking steroids or any over-the-counter medication. However, prior to that he underwent a PCNL procedure for right nephrolithiasis. His visual acuity was 6/60 for the affected eye. Anterior segment examination reveals dense white cataract on the RE which turned out to be dense cortical matter following phacoemulsification.

Conclusion: Although uncommon and not routinely discussed between surgeons and patients, PCNL may cause a semi-acute cataract formation secondary to radiation associated with the procedure. In view of the increasing trend of radiation involved in the management of nephrolithiasis, both surgeons and patients need to be made aware of this complication and the possible ways to overcome it.

Conflicts of interest: The authors report no conflicts of interest.

Keywords: cataract, nephrolithiasis, percutaneous nephrolithotomy.

EyeSEA 2018;13(2): 1-7

Full text. <https://www.tci-thaijo.org/index.php/eyesea/index>

Background

Cataract is the leading cause of blindness in the world. It is opacification of the natural crystalline lens of the eye due to disruption

Correspondence to:

Badaruddin A, Department of Ophthalmology, University of Malaya, Kuala Lumpur, 50603, Malaysia
E-mail: aliyyabadaruddin@gmail.com

of lens protein fibres. Common risk factors for cataract include aging, ultraviolet light, steroid use, ionizing radiation, diabetes and ocular trauma.¹ Age is by far the strongest risk factor for cataract however the number of cataract caused by ionizing radiation is on the rise following the increase in the use of ionizing agents for diagnostic and therapeutic purposes for example in

percutaneous nephrolithotomy (PCNL). The incidence and prevalence of renal calculi has been reported to be increasing across the world.²

Percutaneous nephrolithotomy is a minimally invasive technique introduced in the 1950s that became popular only in the 1970s.³ It is commonly used in the removal of renal calculi usually more than 2 cm in size. Under fluoroscopic guidance, a needle is inserted percutaneously through the patient's back while in the prone position and guided to the renal stone. A tract is created, and the stone is then removed or broken into small fragments.³ It has been associated with a few common side effects such as bleeding and infection but recent studies have looked at the radiation doses involved in this procedure that could be potentially harmful.⁴ These side effects have not been well-known and have rarely been discussed by surgeons with their patients prior to the procedure.

In this instance, we report a case of a patient with right nephrolithiasis who underwent a PCNL procedure and developed right eye cataract soon after. We identified the investigations and treatment he underwent including the relative amount of ionizing radiation he received. We also looked at the risk factors this patient had that might increase the likelihood of developing cataract not long after the procedure was carried out.

Case history

A 57-year-old gentleman with underlying hypertension, gout and history of right nephrolithiasis complained of right eye blurring of vision for 4 months duration. It was painless, sudden in onset and progressively worsening. It was not associated with eye pain, redness, eye discharge or any history of eye trauma. He recently underwent a percutaneous nephrolithotomy (PCNL) procedure for removal of renal calculi prior to the onset of symptoms. He

denies blurring of vision or other ocular symptoms in the other eye. He had his eye check-up about 2 years back but was told they were normal.

On his first visit to our clinic, he appeared generally healthy and was not obese. On ocular examinations, his RE vision was 6/60 and no improvement was seen with pinhole. Relative afferent pupillary defect was negative. Anterior segment examination reveals dense white cataract on the RE (Figure 1). Conjunctiva was white, cornea was clear, there was no phacodonesis or iridodonesis. No other significant findings in the anterior segment. There was no fundus view of the RE but B-scan showed flat retina and vitreous was clear.

On examination of the left eye (LE), vision was 6/6 with mild nuclear sclerosis of the lens (Figure 2). Other anterior segment examinations of LE were unremarkable. Fundus examination showed pink optic disc, cup-disc-ratio (CDR) of 0.4 with well-defined margin, vitreous was clear, macula was normal, retina was flat and no retinal vascular abnormalities were seen.

He was planned for RE phacoemulsification under local anaesthesia. During the cataract extraction, it was noted that the lens consisted mainly of dense white cortical matter. The surgery went well and patient's RE vision improved to 6/7.5 after 3 months.

On further history, he had a history of urinary frequency and dysuria for 1 month duration before he sought treatment at a private medical centre. He underwent a Kidney-Ureter-Bladder (KUB) x-ray (Figure 3) and was found to have a large right renal staghorn calculi. On the day of treatment, he underwent fluoroscopy-guided percutaneous nephrolithotomy (Figure 4) to remove the renal calculi. Following that, he underwent another round of KUB x-ray (Figure 5) after the removal of renal calculi to assess any remaining renal calculi. The KUB x-ray showed some remaining

calculi in the right kidney measuring 0.7cm to 0.8cm. The position of right JJ stent was noted with no hydronephrosis seen. The left kidney and urinary bladder was normal. A few days later after the

nephrostomy tube was removed, he had his third KUB x-ray to re-assess his condition again. (Figure 6). Only minimal residual renal calculi was left behind in which no immediate treatment was planned for him.

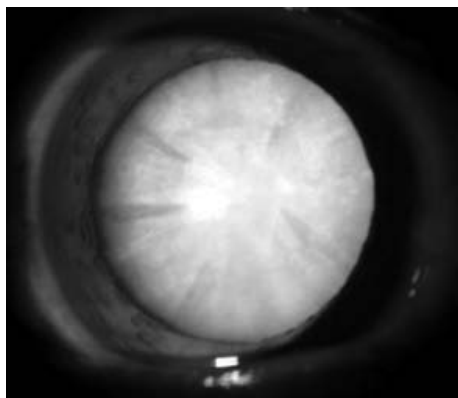


Figure 1: Anterior segment photograph of right eye showing white cataract

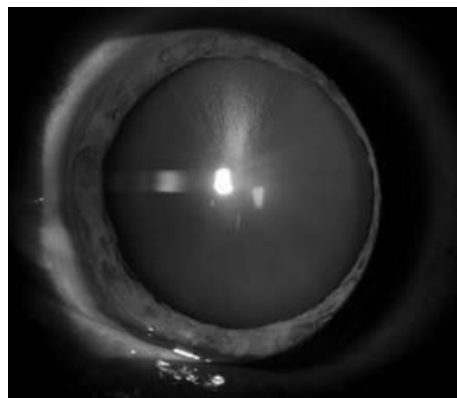


Figure 2: Anterior segment photograph of left eye

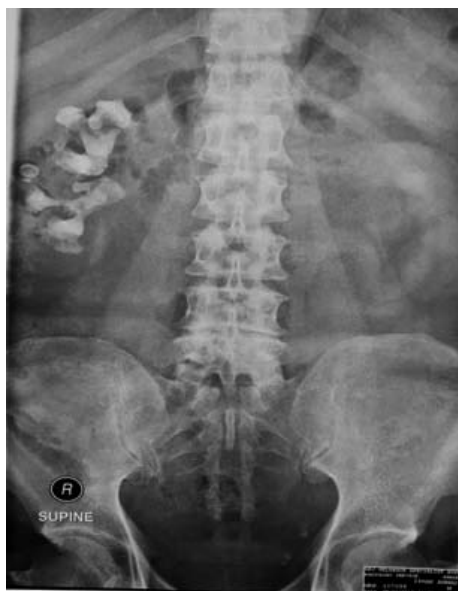

Figure 3: KUB x-ray showing large right renal staghorn calculi

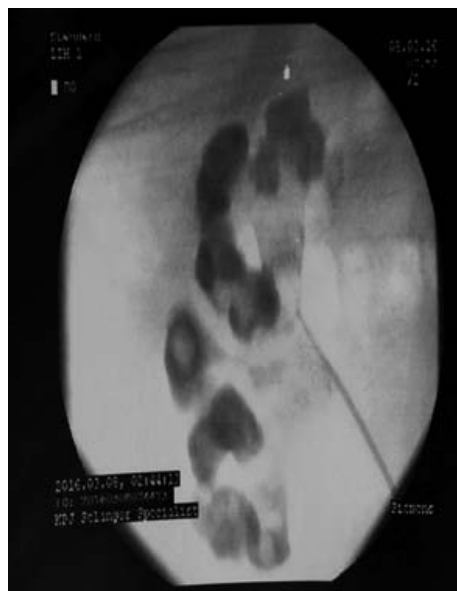

Figure 4: Fluoroscopy-guided PCNL

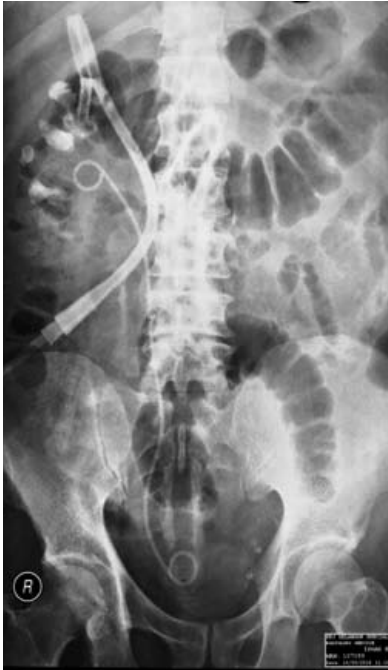

Figure 5: KUB x-ray showing a nephrostomy tube and JJ stent in situ with some remaining renal calculi

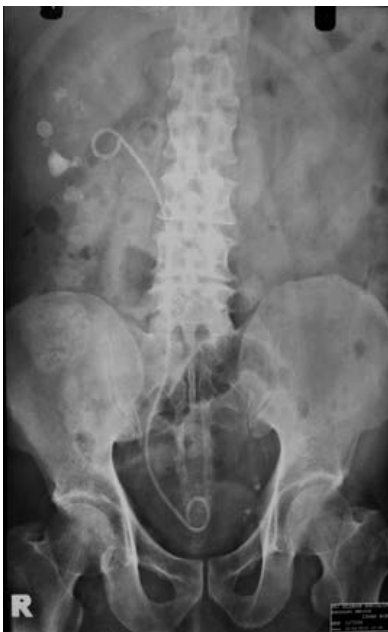

Figure 6: A repeat KUB x-ray following removal of nephrostomy tube

The procedure went well and he was discharged from the hospital with no immediate complications. He was well until about 1 month later when he started having gradual right eye blurring of vision that rapidly progressed and hence brought him to our clinic 4 months later.

He has underlying hypertension and hyperlipidemia for the past 20 years and gout for 4 years. His blood pressure has been well-controlled with 1 oral anti-hypertensive. He is on allopurinol for gout and seldom gets gout attack. He does not smoke nor drink alcohol and he is not obese. He works as a police officer and is usually exposed to sunlight for about 12 hours per week during which he wears sunglasses most of the time.

Discussion

Percutaneous nephrolithotomy (PCNL) is a minimally invasive procedure commonly used in treating large or complex renal calculi.⁵ Since its introduction, the open surgery technique for large nephrolithiasis has been eliminated, the associated morbidities have been minimized and duration of hospital stay has been reduced.⁶ PCNL also allows direct access to the calculi while minimizing trauma to the kidney and surrounding structures.

During PCNL, the patient will lie in prone position and a nephroscope tube is inserted through the skin on the patient's back under fluoroscopic guidance into the kidney. This provides access to the renal drainage system and enables the insertion of telescope, laser fibres and stone grasping instruments to visualize the stones followed by removal of smaller stones or fragmentation of larger stones.³ At the end of the procedure, a drainage catheter called a nephrostomy tube may be left in the kidney to drain the urine.⁷ Alternatively, fluoroscopy might be replaced by CT or ultrasound-guidance when making a tract into the kidney.⁸

Indications for PCNL include large size

renal calculi usually more than 2 cm, stag-horn calculi, upper tract calculi not responding to other modes of treatment and calculi in anatomically abnormal kidneys.⁹ Patients undergoing PCNL are exposed to a greater or equal amount of radiation than they receive from a CT scan.¹⁰ Prior to the procedure, the patients need to undergo some radio-imaging investigations to help the surgeon in locating the stones and gives rough estimation of its size. These may include Kidney-ureter-bladder (KUB) x-ray, renal ultrasound, Intravenous Pyelogram (IVP) or abdominal Computed Tomography (CT) scan in some patients.

Although it is widely performed, PCNL has some risks and complications such as infection, sepsis, bleeding and adjacent organ injury.⁷ Although relatively uncommon, PCNL has a major drawback in the sense that the patients are exposed to some form of ionizing radiation from imaging and fluoroscopy. This may expose patients to the risk of

solid or haematological malignancies. Examples of imaging involved include KUB x-ray, intravenous pyelogram or CT abdomen depending on cases.¹⁰ Patients with a single stone episode receive a median effective dose of 5.3 millisievert (mSv) (range 1.18 to 37.66) during diagnosis and treatment with minimal CT use.¹¹ Some risk factors that might increase radiation exposure and thus its complications are recurrent renal calculi, large size calculi, obesity and multiple tracts.⁸

The human eye is vulnerable to radiation damage which may lead to cataract formation. The current guidelines by The International Commission on Radiological Protection (ICRP) regarding radiation protection against cataracts are shown in Table 1. ICRP also recommends that for occupational exposure, annual lens radiation dose limit is 20 mSv in a year, averaged over 5 years period with no single year exceeding 50 mSv. As for the public, annual lens radiation dose limit is set at 15 mSv per year.¹²

Table 1: ICRP Guidelines on Minimal Lens Doses for Cataract Induction¹³

End Point	Brief Exposures (Sv)	Fractionated or Protracted Exposures (Sv)	Annual Dose Rate (Sv)
Detectable opacities	0.5 - 2.0	> 0.1	5
Visual impairment	5	> 0.15	> 8

A study that evaluates radiation exposure in patients receiving fluoroscopy during PCNL found the mean effective dose to be 8.66 mSv.¹⁰ Other studies have shown that median effective dose for non-obese men undergoing left-sided PCNL was 8.11mSv and right-sided PCNL was 7.63mSv.⁸ The mean radiation exposure dose from fluoroscopy was 9mSv⁵, from CT abdomen was 8mSv⁵ and KUB x-ray exposes patients to radiation dose of 0.5 to 0.8mSv.¹³ In this case, this patient underwent fluoroscopy-guided PCNL and had 3 KUB x-rays taken within 18-days duration. This might have exposed him to a radiation dose of

roughly 10 mSv. Although less than the minimal lens radiation dose recommended by ICRP, it is important to note that cataract formation may still be possible as the patient was exposed to multiple radiation doses within a short period of time.

A few mechanisms on how ionizing radiation induces cataractogenesis have been proposed. These include damage to the lens cell membrane and damage to the lens cell DNA causing a decrease in protective enzymes production as well as protein concentrations.¹⁴ Cataractogenic radiation damage begins at the anterior surface of the lens where the dividing cells form clear

crystalline-protein fiber which migrates to the posterior pole of the lens, the posterior subcapsular region.¹⁵ Unlike senile cataract which commonly causes nuclear cataract, radiation damage causes DNA break, aberrant cell migration and complex biochemical alterations resulting in aberrant crystalline protein folding and dysregulation of lens cell morphology.¹⁵ This results in lens opacification especially in the posterior subcapsular region. Previously it is thought that radiation-induced cataract is limited to posterior subcapsular region only. However recent data has shown that radiation induced opacities can also be found in the lens cortex.¹⁵

Hence by understanding these mechanisms, mechanical shielding such as wearing leaded glass eyewear is recommended to minimize the risk of radiation-induced cataract.¹⁴ However, minimizing the amount of radiation exposed to the patients is still the best method of reducing the number of cataract caused by ionizing radiation. These can be achieved by replacing iodinated contrast used during fluoroscopy with air which reduces radiation exposure by almost 50% with 4.45mSv instead of 7.67 mSv. Besides that, air causes less extravasation and has preferential filling of posterior calyces when patient is prone.⁸ Other interventions to reduce radiation exposure during PCNL include the use of ultrasound-guidance especially in pregnant ladies, children and non-obese patients as it uses high-frequency sound waves.¹³ The use of ultrasound to guide access during PCNL significantly reduces radiation from fluoroscopy.⁸ Implementation of low dose CT protocols (LDCT) which uses lower amount of radiation while maintaining similar sensitivity and specificity in detecting calculi also reduces radiation exposure especially in non-obese patients¹⁰. Lastly, when using fluoroscopy, the principles of radiation exposure As Low As Reasonably Achievable (ALARA) should be followed. These include using pulsed fluoroscopy.

at lowest frames per second which gives usable image quality to perform the procedure and minimizing fluoroscopy time.⁸ Reducing the fluoroscopy time can also be achieved by getting an experienced surgeon to perform PCNL. This will also increase the stone-free rate and reduce the possibility of patients having to undergo another round of treatment requiring fluoroscopy in the future.⁷

To the best of our knowledge, no similar cases have been reported previously. However, a study on ionizing radiation-induced cataract in interventional cardiology staff has been reported.¹⁶ Hence, it may be recommended in the future that a study to investigate the direct relationship between PCNL and cataract should be carried out.

Conclusion

Patients with nephrolithiasis undergoing PCNL are at high risk for radiation exposure secondary to imaging and fluoroscopy used during treatment. Exposure to repeated ionizing radiation within a short period of time although at a relatively low dose, may result in the formation of a cataract.

References

1. Javitt JC, Wang F, West SK, Wang F. Blindness due to cataract: epidemiology and prevention. *Annu Rev Public Health* 1996;17:159-77.
2. Romero V, Akpınar H, Assimos DG. Kidney stones: a global picture of prevalence, incidence and associated risk factors. *Rev Urol* 2010 Spring;12(2):e86-96.
3. Malik I, Wadhwa R. Percutaneous Nephrolithotomy: Current Clinical Opinions and Anesthesiologists Perspective. *Anesthesiology Research and Practice* 2016;1:1-7.
4. Kim KP, Miller DL, Berrington de Gonzalez A, Balter S, Kleinerman RA, Ostroumova E, et al. Occupational radiation doses to operators performing fluoroscopically-guided procedures. *Health Phys* 2012;103(1):80-99.

5. Mancini JG, Raymundo EM, Lipkin M. Factors Affecting Patient Radiation Exposure During Percutaneous Nephrolithotomy. *J Urol* 2010;184(6):2373-7.
6. Nahas AE, Shokeir AA, Shoma A. Percutaneous nephrolithotomy versus open surgery for treatment of staghorn stones in pediatric patients. *Can Urol Assoc J* 2014;8(11):906-9.
7. Celik H, Tasdemir C, Altintas R. An overview of percutaneous nephrolithotomy. *EMJ Urol* 2015;1:46-52.
8. Lipkin ME, Preminger GM. Risk reduction strategy for radiation exposure during percutaneous nephrolithotomy. *Curr Opin Urol* 2012;22(2):139-43.
9. Taylor E, Miller J, Chi T, Stoller ML. Complications associated with percutaneous nephrolithotomy. *Transl Androl Urol* 2012;1(4):223-8.
10. Chen TT, Wang C, Ferrandino MN. Radiation exposure during the Evaluation and Management of Nephrolithiasis. *J Urol* 2015;194(4):878-85.
11. John BS, Patel U, Anson K. What radiation exposure can a patient expect during a single stone episode? *J Endourol* 2008;22(3):419-22.
12. Boal TJ, Pinak M. Dose limits to the lens of the eye: International Basic Safety Standards and related guidance. *Ann ICRP* 2015;44(1):112-7.
13. Elkoushy MA, Andonian S. Lifetime Radiation Exposure in Patients with Recurrent Nephrolithiasis. *Curr Urol Rep* 2017;18(11):85.
14. Lipman RM, Tripathi BJ, Tripathi RC. Cataracts induced by microwave and ionizing radiation. *Surv Ophthalmol* 1988;33(3):200-10.
15. Shore RE, Neriishi K, Nakashima E. Epidemiological studies of cataract risk at low to moderate radiation doses: (Not) seeing is believing. *Radiat Res* 2010;174(6):889-94.
16. Vano E, Kleiman NJ, Duran A. Radiation cataract risk in interventional cardiology personnel. *Radiat Res* 2010;174(4):490-5.