

# Vertical Root Fracture Findings from Cone Beam Computerized Tomography: A Serial Case Analysis

Kanchit Suwanalai<sup>1</sup>, Weerapan Aunmeungthong<sup>2</sup>

<sup>1</sup>Sukhothai Hospital, Thailand

<sup>2</sup>Center of Excellence for Dental Implantology, Faculty of Dentistry, Chiang Mai University, Thailand

Received: June 10, 2021 • Revised: June 25, 2021 • Accepted: July 13, 2021

Corresponding Author: **Assistant Professor Dr. Weerapan Aunmeungthong**, Center of Excellence for Dental Implantology, Faculty of Dentistry, Chiang Mai University, Chiang Mai 50200, Thailand. (E-mail: [weedentphd@outlook.com](mailto:weedentphd@outlook.com))

## Abstract

The diagnosis of vertical root fracture (VRF) has been discussed as a difficult and complicate issue to make the definitive diagnosis. With the using of a new modality image diagnosis, cone-beam computed tomography (CBCT), it may help to identify the VRF. The purpose of the study was to describe the CBCT findings of the VRF and relevant clinical findings. Nine patients with tentative diagnosis of VRF were included in the report. All patients were sent for CBCT. Most of the CBCT clearly showed peri-radicular lesion. Together with the periapical film and clinical findings, the diagnosis of VRF could be made. All the extracted teeth showed the VRF. CBCT is helpful to confirm the VRF when using with the conventional periapical film and clinical symptoms.

**Keywords:** cone beam computed tomography, root canal treated tooth, vertical root fracture

## Introduction

Vertical root fracture (VRF) was defined as “a longitudinally oriented fracture of the root that originates from the apex propagates to the coronal part”.<sup>(1)</sup> The prevalence of VRF is more commonly found in endodontically treated teeth. The overall prevalence of VRF has been reported around 3%-5%.<sup>(2)</sup> The prevalence of VRF is higher (11%-20%) in endodontically treated teeth.<sup>(3,4)</sup>

To make the definitive diagnosis, VRF is not straight forward to clearly define. The clinical findings in non-endodontic treatment tooth are hardly to confirm the VRF. The two-dimensional radiography such as periapical film somehow VRF cannot be detected. It has been investigated that to visualize a VRF, the primary beam needs to be within 4 degree of the fracture line.<sup>(5)</sup> To date the most accurate method to detect the VRF is surgical inspection or visual inspection of the extracted tooth.<sup>(6)</sup> However, in root canal treated tooth, clinical findings such as multiple

sinus tracts, visual fracture line using blue light unit, can be helpful for VRF diagnosis. Periapical film with halo lesion around the root of endodontically treated tooth demonstrate the sign of VRF.<sup>(7)</sup>

Cone-beam computed tomography (CBCT) is a medical imaging device using a cone-shaped x-ray source projected on a digital flat-panel detector. The signal then was interpreted by a software to reconstruct the 3-D image. By using the software with the algorithm, the image can be seen in every dimension depending on each commercial software used. Compared to the medical CT, CBCT units are smaller and less cost with the higher resolution images with lower x-ray doses to the patients.<sup>(8)</sup> A study showed the average sensitivity of the CBCT for the diagnosis of VRF was  $0.84 \pm 0.2$ .<sup>(6)</sup> However, a systematic review on CBCT and VRF concluded that, there is currently insufficient evidence to suggest that CBCT is a reliable test in detecting VRFs in endodontically treated teeth.<sup>(9)</sup>

The purpose of the case report was to describe the CBCT findings of the VRF and relevant clinical findings.

### Case series

Nine patients with tentative diagnosis of VRF were included in the report. Six male and three female patients with average age 57.2 years were presented to the dental clinic of Sukhothai Hospital between August 2019 to February 2020. Most of the cases had chief complaint of gingival swelling, pain at the affected teeth, some cases the pus exudate were presented. The teeth involvement are eight molars (two upper first molars, two upper second molars, four second lower molars) and one first premolar. Eight from nine teeth are endodontically treated teeth. The details of cases are shown in table 1. Periapical radiography was made in all cases. The tentative diagnosis was made in all cases as VRF.

### Periapical film findings

Case 1-8 show root canal treated teeth, case 9 shows severe attrition tooth without endodontically treated tooth. All the case shows periapical radiolucency. Case 1, 2, and 3 show clearly defined of VRF. Case 4-9 are not clearly detected for root fracture.

### CBCT findings

All the cases were proceeded to the CBCT scanning (Dentiscan, NSTDA, Thailand) for three-dimensional

radiographic investigation. Dentiplan software (NSTDA, Thailand) was used to identify the 3D radiographic findings.

**Case 1** Axial view: The image shows the artifact of metal post in the root canal, however, the separation of buccal root can be detected.

Coronal view: The image shows clearly separated buccal root from the metal post in the canal.

Sagittal view: The image indicates the bone resorption around the root, the space between buccal root can be detected.

3D image shows the bony destruction around the root of both premolars, the fracture piece of the buccal root can be seen. (Figure 1)

**Case 2** Axial view: The fracture root cannot be detected. The periapical radiolucency can be detected.

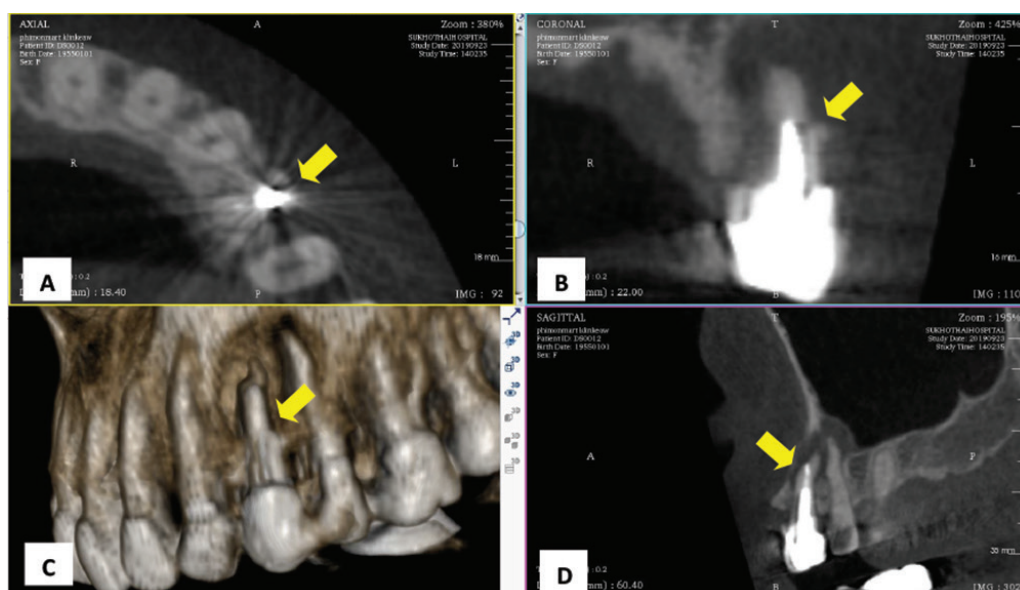
Coronal view: The fracture part of the distobuccal root can be detected.

Sagittal view: The fracture root cannot be seen, however, the bony lesion can be seen more invasion into the furcation.

3D image: The fracture root cannot be detected. (Figure 2)




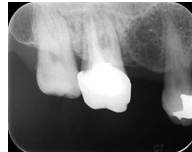

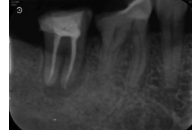



**Case 3** Axial view: The fracture root cannot be detected.

Coronal view: The fracture root cannot be detected, but the bony lesion around palatal root and buccal can be seen involved in the furcation area.



**Figure 1:** CBCT of case 1. (A) axial view, (B) coronal view, (C) reconstruction view and (D) sagittal view.

**Table 1:** Information of patients and periapical films.

Number	Gender	Age	Tooth	Clinical findings	Periapical film
1	Female	65	24	No pain, sinus tract found between teeth 24, 25, deep pocket depth around tooth 24, tooth 24 has no mobility, previously root canal treatment	
2	Male	81	16	Sinus tract at buccal of tooth 16, deep pocket depth at mesial of tooth 16, tooth 16 has 1 <sup>st</sup> degree of tooth mobility. Previously root canal treatment	
3	Male	68	27	No pain, swelling and deep pocket depth at buccal of tooth 27, crack line found at mid buccal, 2 <sup>nd</sup> degree mobility. Previously root canal treatment	
4	Male	61	26	No pain, sinus tract at buccal of tooth 26, deep pocket depth around the tooth, 2 <sup>nd</sup> degree tooth mobility. Previously root canal treatment	
5	Female	44	47	Swelling with pus exudate, deep pocket depth around the tooth, 3 <sup>rd</sup> degree tooth mobility. Previously root canal treatment	
6	Male	59	47	No pain, slightly swelling at buccal of the tooth, pus exudate is found from deep pocket depth, 1 <sup>st</sup> degree tooth mobility. Previously root canal treatment	
7	Male	42	47	No pain, sinus tract at buccal of the tooth, deep pocket depth at mesial and distal of the tooth, 1 <sup>st</sup> degree mobility. Previously root canal treatment	
8	Male	41	47	No pain, normal pocket depth, no mobility found. Previously root canal treatment	
9	Male	56	27	Slightly pain, swelling with mesial deep pocket depth, 2 <sup>nd</sup> degree tooth mobility. No previous root canal treatment.	

Sagittal view: The fracture root cannot be detected. Radiolucency (halo lesion) around buccal root can be seen clearly.

3D image: The fracture root cannot be detected. (Figure 3)

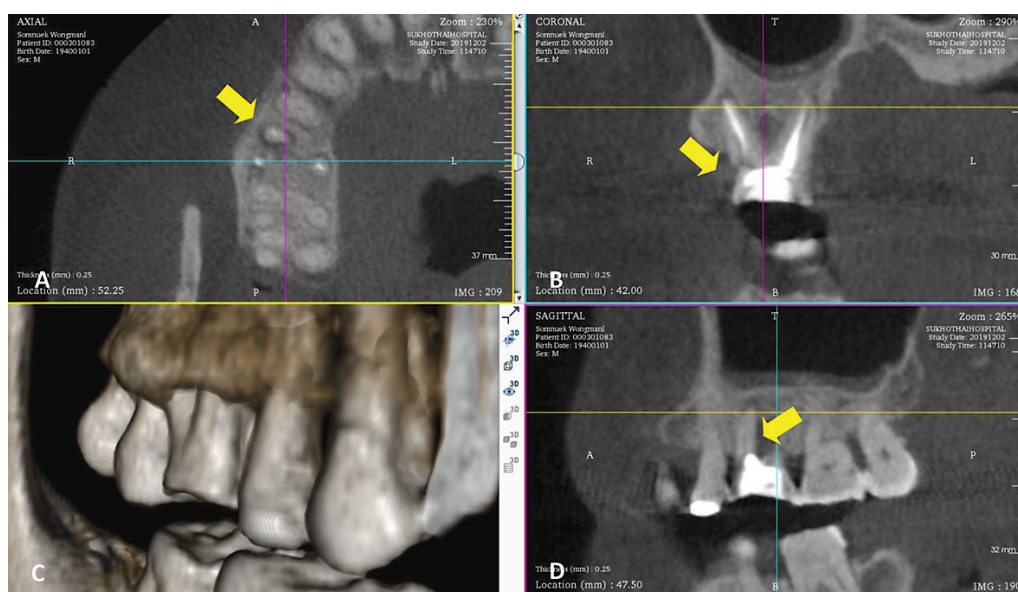
**Case 4** Axial view: The fracture part can be clearly detected; the fracture line is seen.

Coronal view: The fracture root which is separated from the buccal root can be found, bony lesion around the root can be seen.

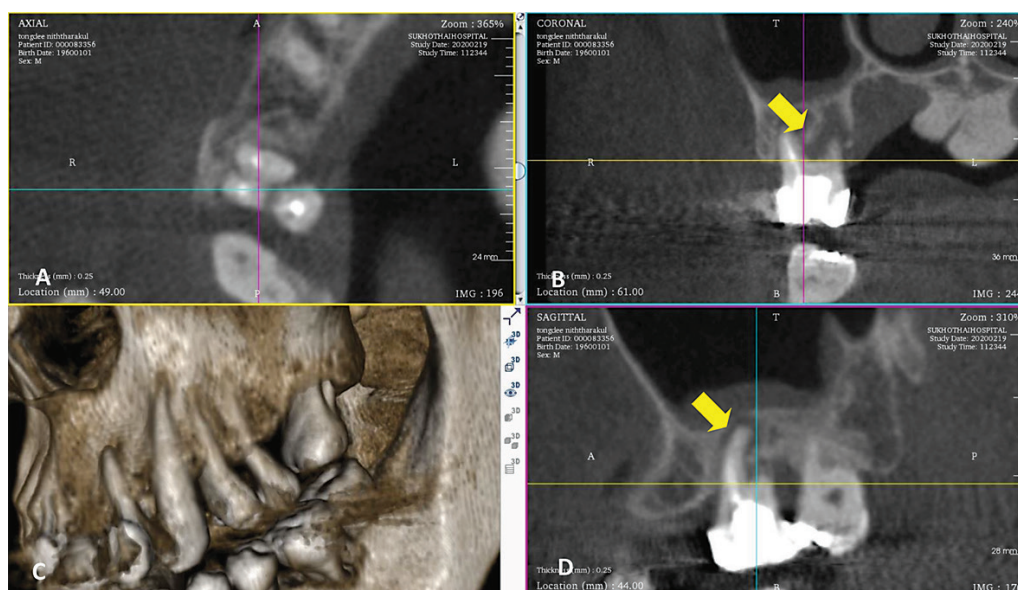
Sagittal view: The fracture line can be detected, the bone resorption around the fracture root is easily seen.

3D image: The fracture root can be seen in the image. (Figure 4)

**Case 5** Axial view, coronal view, sagittal view, and 3D image: The fracture cannot be detected, however, the bone lesion around the roots in all views is easily seen for the location of the lesion which is reflected the classical finding of root fracture. (Figure 5)



**Figure 2:** CBCT of case 2. (A) axial view, (B) coronal view, (C) reconstruction view and (D) sagittal view.



**Figure 3:** CBCT of case 3. (A) axial view, (B) coronal view, (C) reconstruction view and (D) sagittal view.

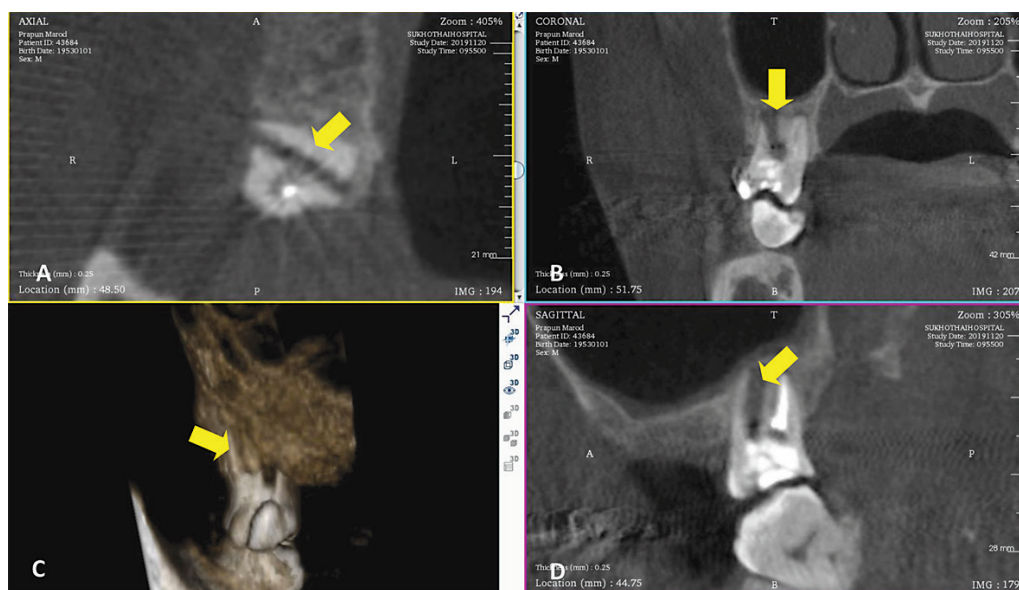


**Case 6** The findings of CBCT in axial view, coronal view, and sagittal view are like case 5. However, the fracture root can be detected in 3D image. (Figure 6)

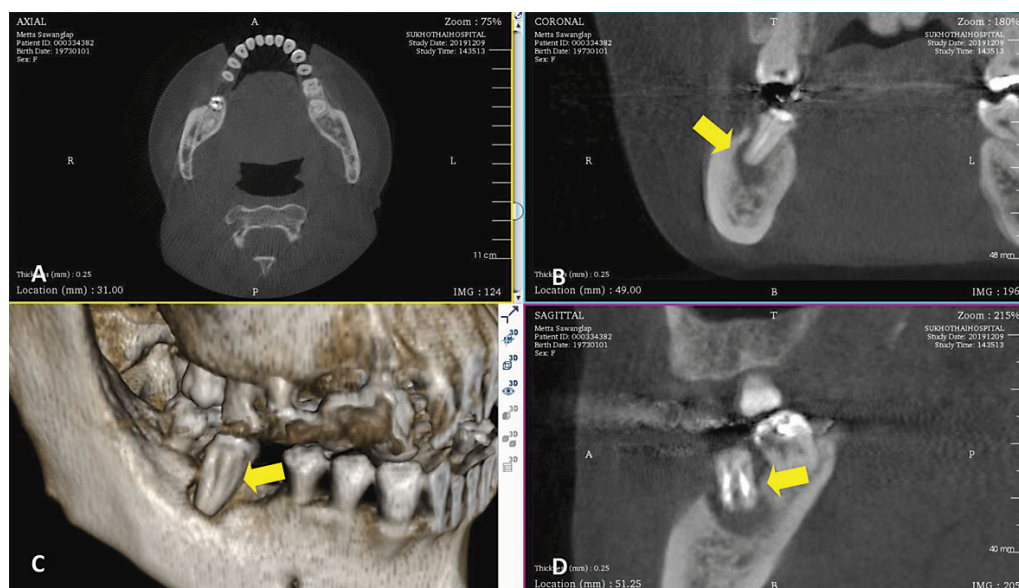
**Case 7** CBCT was made before the root canal treatment. For all views of the CBCT image, the fracture root cannot be detected. The radiolucency of bony lesions shows the furcation involvement area better than periapical radiography. The diagnosis of VRF could be made from this finding. (Figure 7)

**Case 8** CBCT was made before the root canal treatment. For all views of the CBCT image, the fracture root cannot be detected. The periapical lesion can be found, but the diagnosis of VRF cannot be made. (Figure 8)

**Case 9** In all views of CBCT image, the fracture root cannot be detected. But the radiolucency around the tooth and bony pocket especially in 3D image, together with the clinical findings, the diagnosis of VRF can be made. (Figure 9)



**Figure 4:** CBCT of case 4. (A) axial view, (B) coronal view, (C) reconstruction view and (D) sagittal view.



**Figure 5:** CBCT of case 5. (A) axial view, (B) coronal view, (C) reconstruction view and (D) sagittal view.

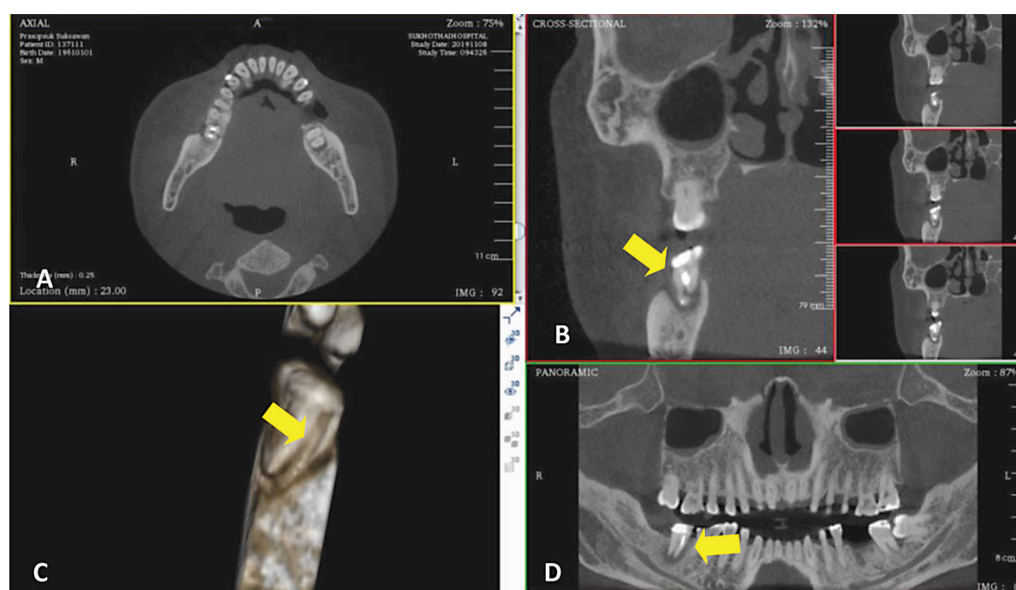
All the teeth are extracted due to unimproved clinical symptoms, or some are non-restorable or hopeless teeth. The extracted teeth show vertical root fracture.

## Discussion

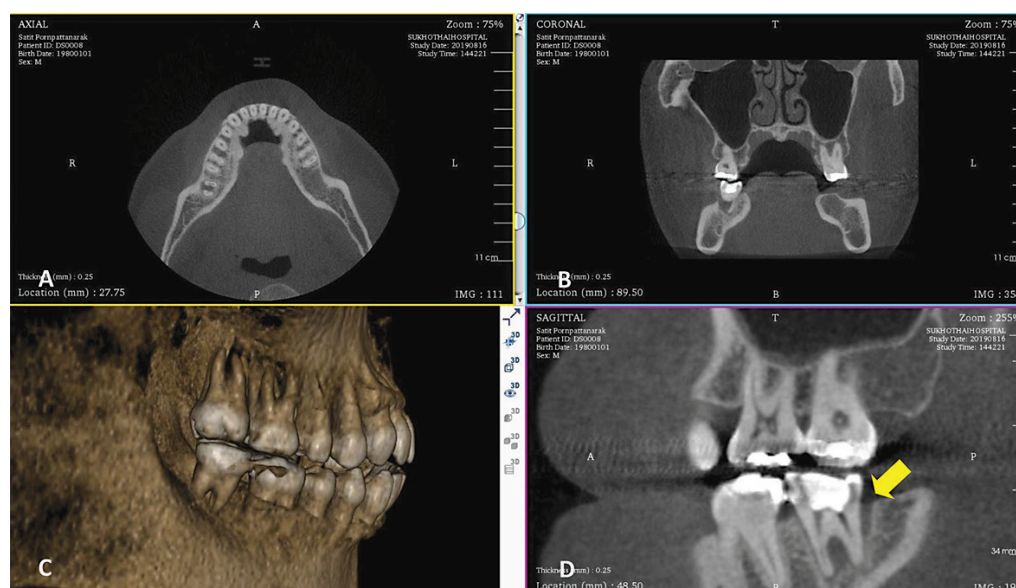
Vertical root fracture (VRF) is normally cannot be treated by root canal treatment. The involving teeth are normally end with tooth extraction. Clinically, the patients are suffering from VRF though the root canal treatment has been performed. In the root canal treated teeth, VRF

is also the long-term consequence of previous endodontically treatment tooth. In our case reports, most of the VRF are root canal treated teeth, some were tried with root canal retreatment, but the results are poor. The symptoms are continued, and the end results are tooth extraction.

The differential diagnosis of VRF is challenging because there are no pathognomonic clinical signs and symptoms of VRF.<sup>(10,11)</sup> The using of CBCT together with periapical radiography and clinical findings is useful for the tentative diagnosis and decision making for tooth



**Figure 6:** CBCT of case 6. (A) axial view, (B) coronal view, (C) reconstruction view and (D) sagittal view.



**Figure 7:** CBCT of case 7. (A) axial view, (B) coronal view, (C) reconstruction view and (D) sagittal view.

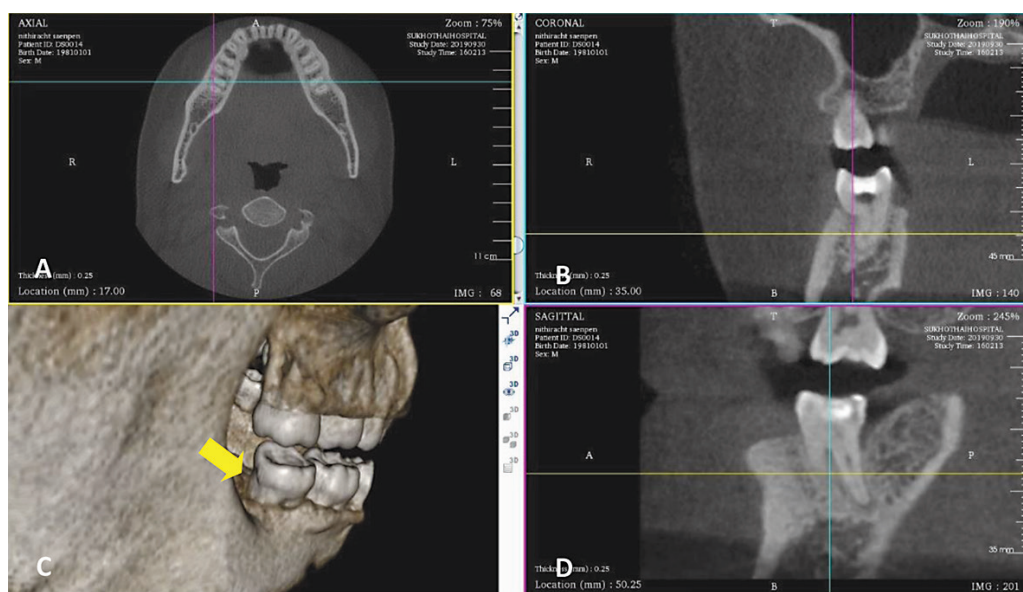


extraction. Although most of the reported cases, the fracture lines cannot be seen in both periapical film and CBCT, but the peri-radicular lesion in CBCT are confirmed the evidence of VRF (case 3, 5, 7, 9). A study from Byakova *et al.* indicated that CBCT was helpful in VRF diagnosis even when it was not possible to visualize the fracture line.<sup>(6)</sup>

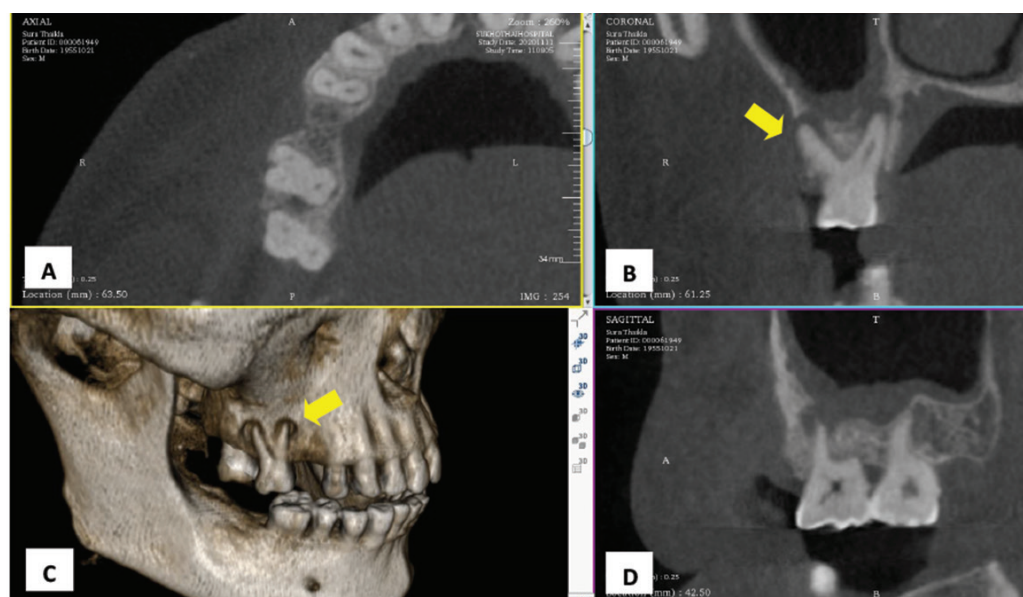
The width of fracture lines has been assessed for VRF detection, Chavda *et al.* found poor sensitivity in detection VRF.<sup>(15)</sup> In our report, the fracture lines cannot be seen until the root fragment is separated (case 1, 2, 4, 6).

VRF occurred mainly in patients older than 40 years. Several studies have shown that age-related changes in dentin can lead to a decrease in fracture resistance.<sup>(12-14)</sup> In our cases report, the average age of the patient is 57.2 years, the youngest is 40 year old and the oldest is 81 year old.

A systematic review on CBCT for detecting VRF in endodontically treated teeth which included 4 studies and 130 patients shows that there is insufficient evidence to suggest that CBCT is a reliable test in detecting VRF in endodontically treated teeth.<sup>(9)</sup> However, in our report,



**Figure 8:** CBCT of case 8. (A) axial view, (B) coronal view, (C) reconstruction view and (D) sagittal view.



**Figure 9:** CBCT of case 9. (A) axial view, (B) coronal view, (C) reconstruction view and (D) sagittal view.

the CBCT is useful to detect the 3D peri-radicular lesion to confirm the evidence of VRF.

To make the diagnosis of VRF, the clinical findings together with radiography are important for the definitive diagnosis. The finding of the 2D radiography is somehow not sufficient to diagnose the VRF. CBCT may be useful for the differential diagnosis especially for detecting the bony lesion around the VRF tooth, thus the correct decision to extract the VRF tooth.

## Conclusions

CBCT is helpful to confirm the VRF when using with the conventional periapical film and clinical symptoms.

## References

1. American Association of Endodontists (1997). Cracking the cracked tooth code; Endodontics. *AAE Colleagues for Excellence*. 1-13.
2. Haueisen H, Gärtner K, Kaiser L, Trohorsch D, Heidemann D. Vertical root fracture: prevalence, etiology, and diagnosis. *Quintessence Int*. 2013;44;467-74.
3. Fuss Z, Lustig J, Tamse A. Prevalence of vertical root fractures in extracted endodontically treated teeth. *Int Endod J*. 1999;32:283-6.
4. Coppens CRM, DeMoor RJG. Prevalence of vertical root fractures in extracted endodontically treated teeth. *Int Endod J*. 2003;36:926.
5. Kositbowornchai S, Nuansakul R, Sikram S. Root fracture detection: a comparison of direct digital radiography with conventional radiography. *Dentomaxillofac Radiol*. 2001;30:106-9.
6. Byakova S, Novozhilova N. The accuracy of CBCT for the detection and diagnosis of vertical root fractures *in vivo*. *Int Endod J*. 2019;52:1255-63.
7. Hargreaves KM, Cohen S, Berman HL. *Pathways of the Pulp*. 10<sup>th</sup> ed. St. Louis, Mo: Mosby Elsevier, 2011.
8. Angelopoulos C, Scarfe WC, Farman AG. A comparison of maxillofacial CBCT and medical CT. *Atlas Oral Maxillofac Surg Clin North Am*. 2012;20:1-17.
9. Chang E, Lam E, Shah P. Cone-beam computed tomography for detecting vertical root fractures in endodontically treated teeth: a systematic review. *J Endod*. 2016;42: 177-85.
10. Tamse A. Vertical root fractures in endodontically treated teeth: diagnostic signs and clinical management. *Endodontic Topics*. 2006;13,84-94.
11. Walton RE. Vertical root fracture factors related to identification. *J Am Dent Assoc*. 2017;148:100-5.
12. Kinney JH, Nalla RK, Pople JA, Breunig TM, Ritchie RO. Age-related transparent root dentin: mineral concentration, crystallite size, and mechanical properties. *Biomaterials*. 2005;26:3363-76.
13. Mireku AS, Romberg E, Fouad AF, Arola D. Vertical fracture of root filled teeth restored with posts: the effects of patient age and dentine thickness. *Int Endod J*. 2010;43:218-25.
14. Yan W, Montoya C, Øilo M, Ossa A, Paranjpe A, Zhang H, Arola D. Reduction in fracture resistance of the root with aging. *J Endod*. 2017;43:1494-8.
15. Chavda R, Mannocci F, Andiappan M, Patel S. Comparing the *in vivo* diagnostic accuracy of digital periapical radiography with cone-beam computed tomography for the detection of vertical root fracture. *J Endod*. 2014;40:1524-9.